

Table of contents

Chapter 1 Humeral fractures

- 1.11 I Proximal humeral fractures—Nonoperative treatment
- 1.12 I Humeral shaft fractures—Treatment with brace
- 1.13 I Distal humeral shaft fractures—Treatment with a splint

Chapter 2 Forearm fractures

- 2.11 I Proximal forearm fractures—Treatment with cast or splint
- 2.11 II Proximal forearm fractures—Functional treatment of 21 A1.1 fractures
- 2.11 III Proximal forearm fractures—Functional treatment of 21 A2.1 fractures
- 2.11 IV Proximal forearm fractures—Functional treatment of 21 A2.2 fractures
- 2.12 I Forearm shaft fractures—Treatment with a cast

Chapter 3 Femoral fractures

- 3.11 I Proximal femoral fractures—Management with minimal resources
- 3.11 II Proximal femoral fractures—Nonoperative treatment of 31—B1 fractures
- 3.12 I Femoral shaft fractures—Management with minimal resources
- 3.12 II Femoral shaft fractures—Temporary Thomas splint
- 3.13 I Distal femoral and patellar fractures—Treatment with a long leg cast
- 3.13 II Distal femoral fractures—Temporary long leg splint
- 3.13 III Distal femoral fractures—Temporary skeletal traction

Chapter 4 Tibial and malleolar fractures

- 4.11 I Proximal tibial fractures—Nonoperative treatment
- 4.12 I Tibial shaft fractures—Management with limited resources
- 4.13 I Distal tibial fractures—Treatment with a cast
- 4.13 II Distal tibial fractures—Traction as initial provisional stabilization
- 4.14 I Malleolar fractures—Management with limited resources
- 4.14 II Malleolar fractures—Functional treatment

Chapter 5 Acetabular fractures

- 5.11 I Acetabular fractures—Nonoperative treatment

Chapter 6 Fractures of the hand

- 6.11 I Scaphoid fractures—Nonoperative treatment with a cast
- 6.12 I Fractures of the thumb—Nonoperative treatment of a Bennett fracture
- 6.12 II Fractures of the thumb—Nonoperative treatment of a Rolando fracture
- 6.13 I Metacarpal fracture—Nonoperative treatment
- 6.14 I Fractures of the proximal phalanx—Nonoperative treatment
- 6.14 II Fractures of the middle phalanx—Nonoperative treatment
- 6.14 III Fractures of the distal phalanx—Nonoperative treatment

Chapter 7 Fractures of the foot

- 7.11 I Fractures of the talus—Treatment with a cast
- 7.12 I Fractures of the calcaneus—Treatment with a splint
- 7.13 I Fractures of the navicular bone—Treatment with a functional boot
- 7.13 II Fractures of the cuboid—Treatment with a functional boot
- 7.14 I Fractures of the phalanges—Treatment by buddy taping



1 Humeral fractures

1.11 Proximal humeral fractures—Nonoperative treatment

Indication **All 11-A, 11-B, and 11-C type fractures**

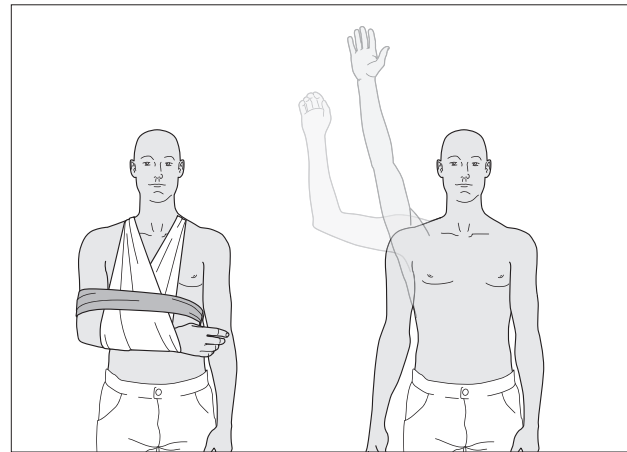
1 Principles

General considerations

Most proximal humerus fractures will heal without surgery, and many recover satisfactory function.

Outcome of nonoperative treatment depends upon the type of fracture, the degree of fragment displacement, and intrinsic fracture stability. Assessment of stability with image intensification is helpful according to the author's experience.

Without fixation, displaced proximal humerus fractures are rarely improved with closed fracture reduction.



Nonoperative treatment should provide mechanical support until the patient is sufficiently comfortable to begin shoulder use, and the fracture is sufficiently consolidated that displacement is unlikely.

Once these goals have been achieved, rehabilitative exercises can begin to restore range of motion, followed by strength, and function.

The three phases of nonoperative treatment are thus

1. Immobilization
2. Passive/assisted range of motion
3. Progressive resistance exercises

Duration of Immobilization should be as short as possible, and as long as necessary. Typically, immobilization is recommended for 2-3 weeks, followed by gentle range of motion exercises. Resistance exercises can generally begin at 6 weeks. Isometric exercises may help maintain strength during the first 6 weeks.



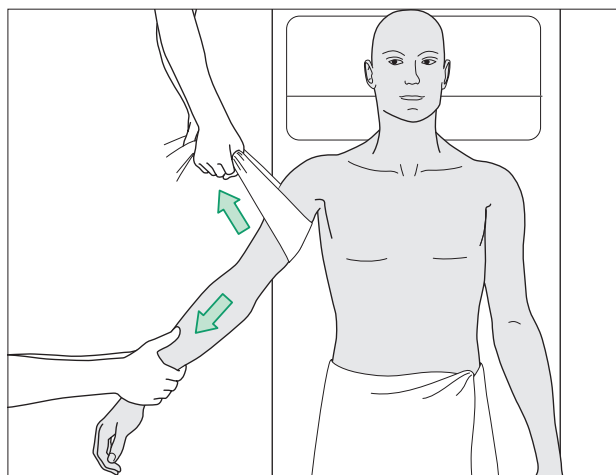
2 Reduction of glenohumeral fracture dislocation

Proximal humeral fracture dislocations (A1.3, B3, and C3) require prompt reduction of the glenohumeral joint dislocation.

Keep in mind that with fracture dislocations it may be necessary to convert to an open reduction procedure in order to reduce the joint. Therefore, arrange for operating room availability.

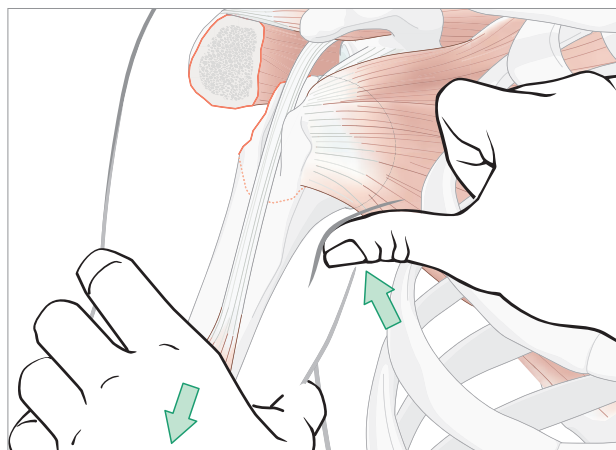
Since the reduction of the dislocation may be difficult, regional or general anesthesia, including muscle relaxation, is recommended.

Note: Definitive operative treatment is usually best for glenohumeral fracture dislocations. Nonoperative treatment should be considered only if surgery has a significant risk, or if shoulder reduction has resulted in acceptable reduction of the fracture components.



2.1 Principles of closed reduction

(See illustration) Axial traction on the arm is almost always helpful. Even with a fracture of the proximal humerus there is usually sufficient intact soft tissue so that the traction is transmitted to the humeral head. Direct manipulation of the dislocated head segment can assist the reduction. Pressure should be applied over the prominent humeral head, and directed to push it back into the glenoid. Beware pressure on neurovascular structures.



2.2 Confirmation of glenohumeral reduction

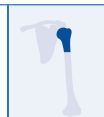Once the glenohumeral reduction is felt, it should be confirmed with true AP and axillary x-rays. Additional fractures or displacement should be looked for. When x-ray anatomy is not completely clear, a CT scan, often with reconstructed views, can be very helpful.

Check also the neurovascular status, especially distal pulses, motor function, and sensation. The axillary nerve is at particular risk, and can be assessed by sensation over the lateral deltoid and the cooperative patient's ability to contract the deltoid muscle.

2.3. Rule out rotator cuff tear

Particularly in older patients, glenohumeral dislocations may result in a torn rotator cuff. Early repair, before tendon retraction or significant atrophy, is the most effective treatment. If physical assessment does not confirm rotator cuff strength, additional studies (eg, ultrasound, MRI) should be performed promptly.

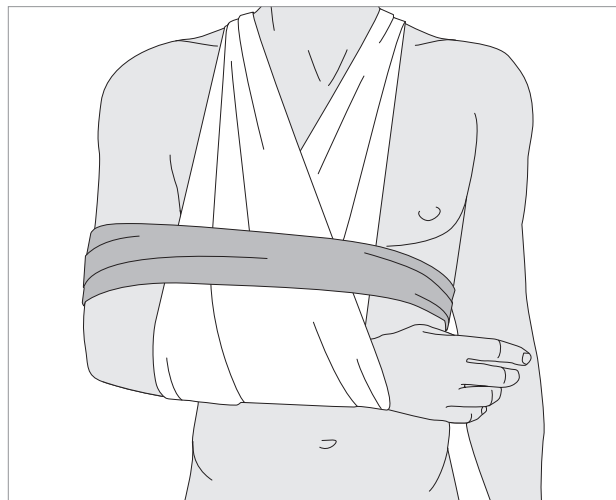




3 Sling and swath

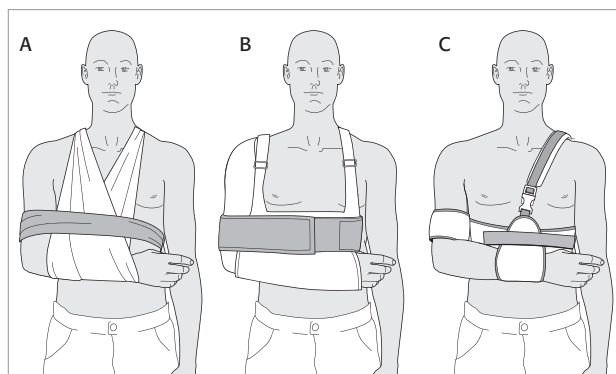
Optimal shoulder immobilization is achieved when the upper arm and forearm are secured to the chest. Traditionally, this has been done with a **sling** that supports the elbow and forearm and counteracts the weight of the arm. The simplest sling is a triangular bandage tied behind the neck.

Additional support is provided by a **swath** which wraps around the humerus and the chest to restrict shoulder motion further, and keep the arm securely in the sling. Commercially available devices provide similar immobilization, with or without the circumferential support of a swath.



4 Shoulder immobilization

Sling and swath (A), shoulder immobilizer (B), Gilchrist bandage (C), and other such devices all provide essentially similar support for the shoulder joint.

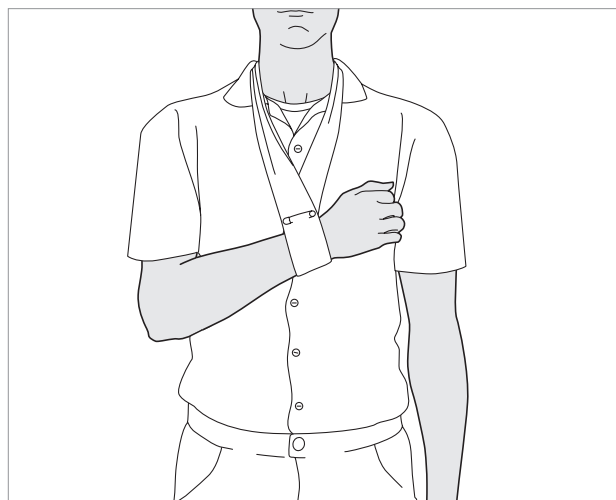

5 Collar and cuff

The simplest arm support is a so-called collar and cuff that limits shoulder motion but does not support much of the arm's weight. This may be desirable when gentle traction is expected to improve fracture alignment. It provides less stability than a sling, with or without swath, and must be removed for shoulder or elbow motion.

Most shoulder supports can be worn underneath or outside the patient's clothing. The latter requires sufficient shoulder motion and comfort for dressing before the support is applied.

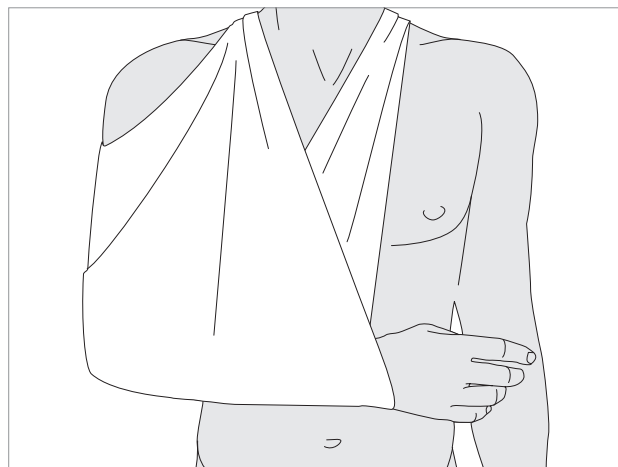
Keeping the hand accessible, and encouraging the patient to move use wrist and fingers, helps to prevent stiffness that may be very hard to correct if it is allowed to develop.





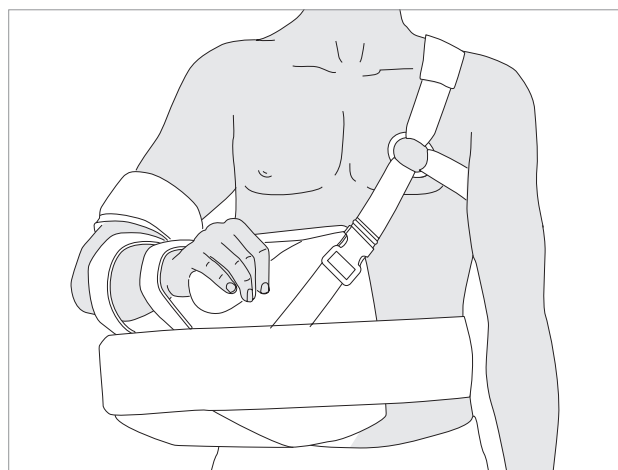
6 Arm sling

Slight to moderate displacement of proximal humerus fractures may be treated by external support alone. A broad arm sling is the commonest method. In its simplest form, a triangular bandage is wrapped around the elbow and the forearm and tied behind the neck. The sling can be adjusted to avoid distraction at the shoulder which might cause undesirable disimpaction. Commercial slings are available to provide similar support.



7 Shoulder abduction cushion

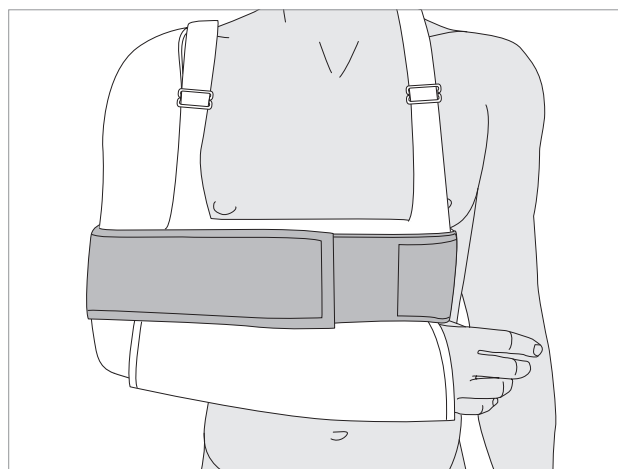To relieve tension on the supraspinatus tendon and greater tuberosity, one may support the arm in abduction. This can be done with a so-called airplane splint or a shoulder abduction cushion as shown.



8 Mobilization: 2-3 weeks posttrauma

Nonoperative management of proximal humerus fractures usually begins with maximal support - a sling and swath equivalent worn continuously. If the patient is uncomfortable, a sitting position may be preferred for sleeping.

A patient who is very comfortable, at the beginning of treatment or after some recovery, may need less immobilization, and even begin gentle use of the injured arm.

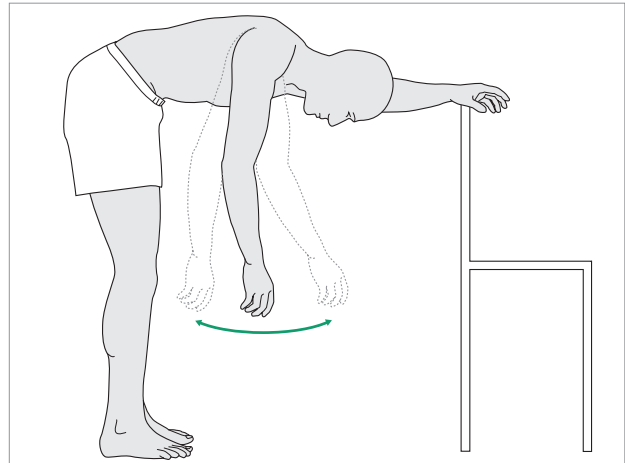




As soon as pain permits, pendulum exercises (as illustrated) should begin. Active hand and forearm use should also be encouraged.

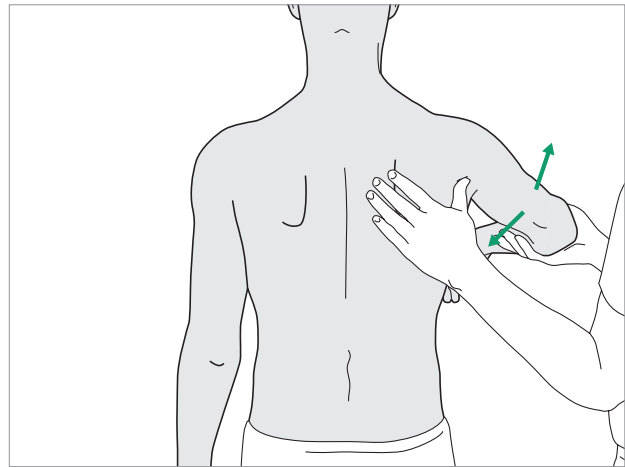
Isometric exercises can begin as soon as tolerated for the shoulder girdle including scapular stabilizers, and the upper extremity.

X-rays should be checked to rule out secondary fracture displacement.



9 Active assisted exercises: 3-6 weeks post-operative

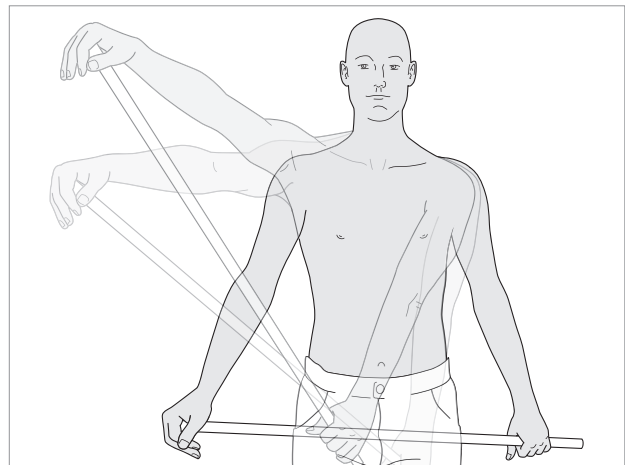
To relieve tension on the supraspinatus tendon and greater tuberosity, one may support the arm in abduction. This can be done with a so-called airplane splint or a shoulder abduction cushion as shown.



10 Shoulder therapy set: 3-6 weeks postoperative

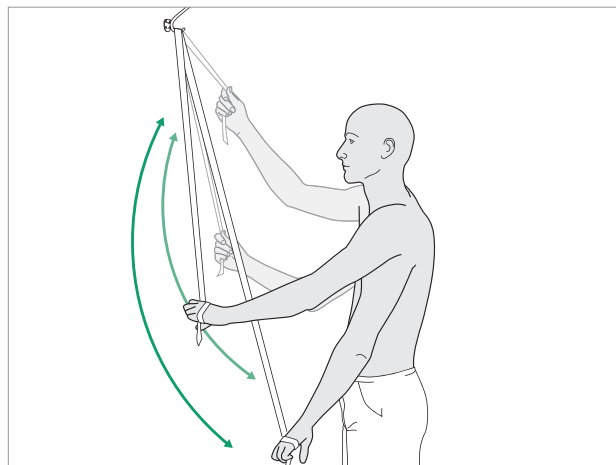
A «shoulder therapy set» might be helpful. Typically included devices are:

1. An exercise bar, which lets the patient use the uninjured left shoulder to passively move the affected right side.





2. A rope and pulley assembly. With the pulley placed above the patient, the unaffected left arm can be used to provide full passive forward flexion of the injured right shoulder.

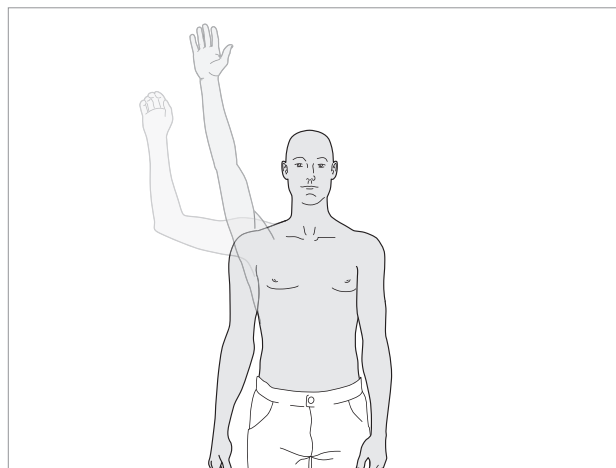


11 Strengthening: from week 6 on

As passive motion improves, and the fracture becomes fully consolidated, active motion against gravity and resistance exercises are added to build strength and endurance. Many surgeons advise forward flexion before abduction against gravity, which puts significant strain on the supraspinatus.

Elastic devices can be used to provide varying degree of resistance, and ultimately the athletic patient can progress to resistance machines and free weights. Physical therapy instruction and supervision may be helpful for optimal rehabilitation or if the patient is not progressing satisfactorily.

Remember to monitor rotator cuff strength. Significant weakness may indicate an unidentified rotator tendon cuff rupture in need of surgical repair.



12 Pitfall: shoulder stiffness

To reduce the risk of stiffness, immobilization should be discarded as soon as possible. This can be done progressively, beginning with elimination of the swath (circumferential bandage) during the daytime and encouraging pendulum exercises.

The sling may be used on a part-time basis as soon as appropriate.

If formal physical therapy has not been prescribed, it should be considered for any patient whose range of motion is not improving as expected.



1 Humeral fractures

1.12 I Humeral shaft fractures — Treatment with brace

Indication **All 12-A, 12-B, and 12-C type fractures**

1 Principles

1.1 General considerations

Most humeral shaft fractures will heal with nonoperative management. A supportive brace and active use of the arm are the two key parts of this. Initial management typically requires somewhat more support. Pain interferes at first with function, which should be progressively encouraged as the patient becomes more comfortable. In an upright patient, the force of gravity on the fractured humerus usually produces satisfactory alignment. The brace, by principle of soft tissue containment, supports the fracture and limits interfragmentary motion. There is a tendency for varus malalignment, which can be resisted by splint molding and arm positioning. Simi-

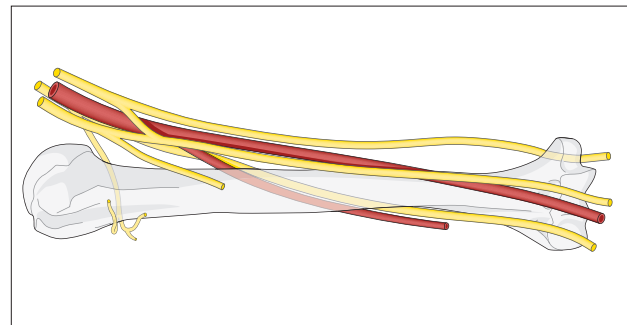
larly, there is a risk of internal rotation malposition, which can be minimized by active arm use.

Most humeral fractures, without significant initial displacement, will heal within three months. If fracture stability is not evident by this time, surgical treatment should be recommended, as a long delay risks increasing osteoporosis as well as prolonged disability.

Healing with slight deformity does not usually cause a problem. Angulation and malrotation of 20–30 degrees, and shortening of up to 3 cm have been described as acceptable. Particularly in slender patients, this much angulation may cause visible deformity. This can be assessed during the healing process by physical examination.

1.2 Associated radial nerve injury

The radial nerve lies in close proximity to the humeral shaft. It is fairly frequently injured with shaft fractures (12–16 %). Most such injuries recover within a few months. Occasionally, the nerve is caught within the fracture site. This may be recognized by sharp pain associated with fracture motion, and/or a fracture gap. In such cases, and typically when nerve function is lost during closed treatment, it may be wise to explore the nerve, and fix the fracture.





2 Initial treatment

2.1 Reduction

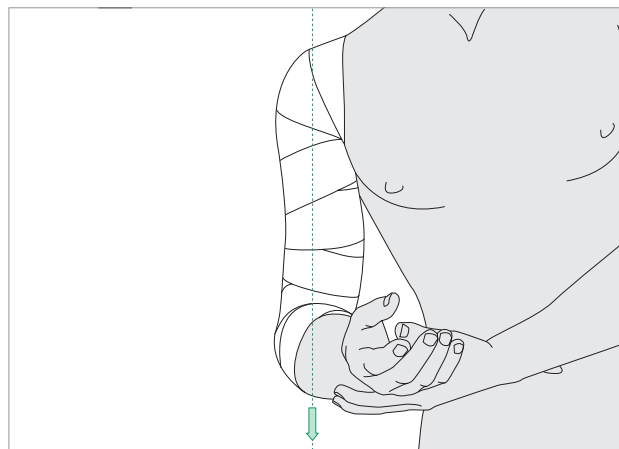
Simple gravitational realignment of the fractured humerus is usually all that is required. With the patient upright and the limb hanging free, deformity is largely

corrected. Muscle forces may cause angulation, but, as the patient relaxes and becomes more comfortable, these forces diminish and alignment improves. Manipulative reduction is rarely necessary.

Angulation can be improved with molding of the splint, as required.

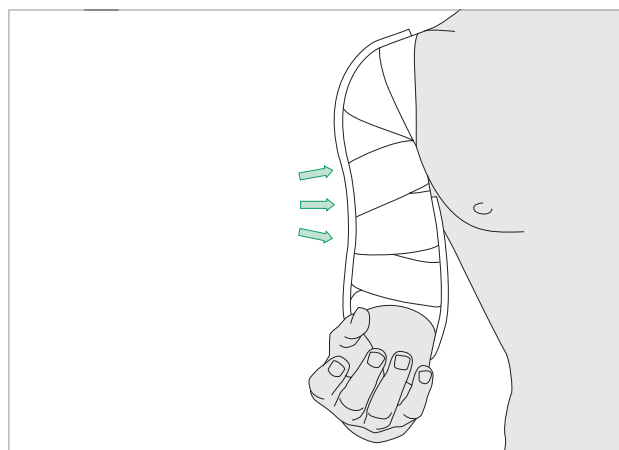
2.2 Cast padding

With the patient sitting, if possible, and leaning slightly to the injured side, cast padding should be wrapped around the upper arm from axilla to elbow. Make sure that the epicondyles of the humerus and antecubital area are well padded.



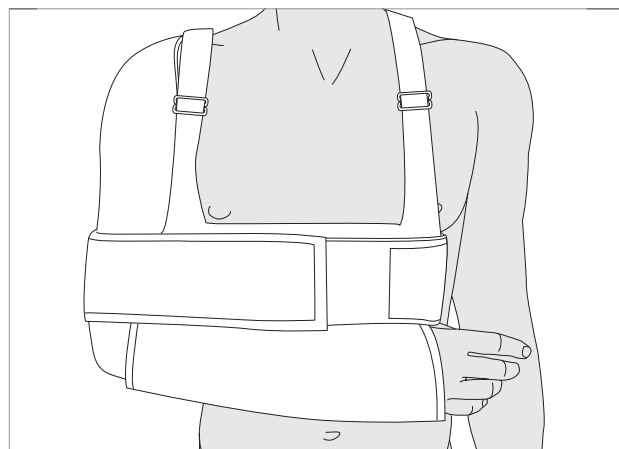
2.3 Application of splint

A splint of fiberglass, or plaster, is applied in a U-shape, with padding under the axilla. It is wrapped from medial to lateral and over the shoulder (except for very distal fractures). It is secured in place with an elastic bandage that should not be too tight. This splint is molded to be concave laterally, to correct typical varus angulation. The upper arm should appear straight when viewed from the side.



2.4 Secure injured arm

The injured arm is secured to the chest with a sling and swathe, shoulder immobilizer, or Velpeau bandage. If there is a radial nerve palsy, a short arm splint is added, to support the wrist in dorsiflexion.



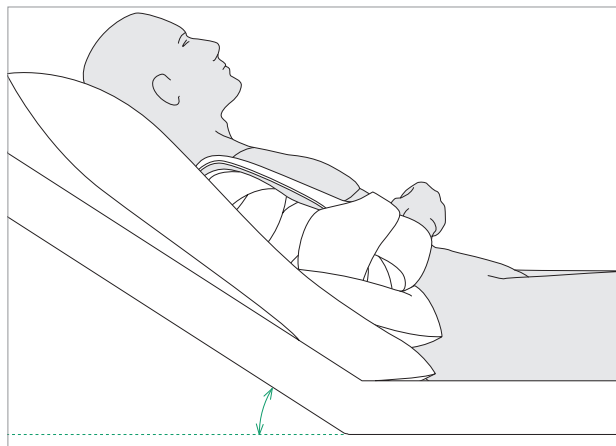


2.5 Analgesia

Analgesia will be required. The patient is usually more comfortable in a sitting or semi-reclining position, at least for the first few weeks. Motion and crepitus will be felt, and the patient should be reassured that this is normal, stimulates healing and will gradually go away.

2.6 Caution

Occasionally, a fracture that is initially closed may become open from excessive motion or splint pressure over a prominent fracture fragment. This will require immediate change to open management with debridement and fixation.



3 Fracture brace management

3.1 Brace application

When the patient is comfortable, and the swelling has decreased, the initial splint should be replaced with a prefabricated humeral fracture brace. The size should be chosen to fit the patient. Make sure that the brace is for the correct side. Alternatively, if the services of an orthotist are available, a custom brace can be made.

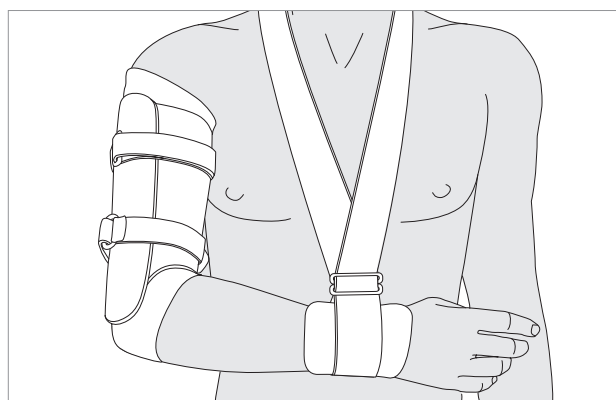
A padded stocking, or sleeve, is first applied to the upper arm, stabilizing the fracture as necessary with gentle distal traction.

The brace must be positioned to avoid pressure in the antecubital fossa, or the axilla. It should be applied with correct rotation.

Initially, the patient may be more comfortable if the arm remains supported with the sling and swathe.

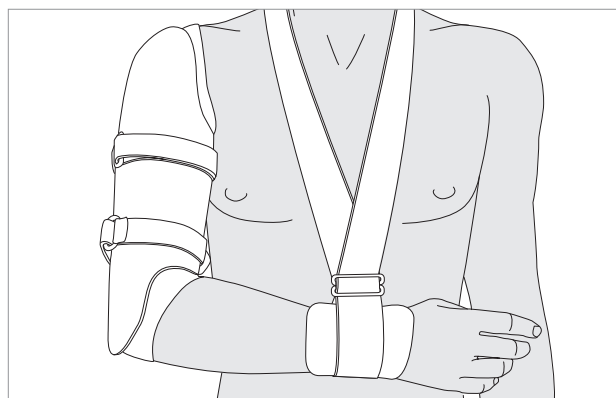
3.2 Initial mobilization

As soon as possible, the sling should be discontinued. A collar and cuff may often be substituted before the unsupported arm is comfortable. Use of the arm, while avoiding abduction from the chest, is to be encouraged. Abduction is painful until healing is advanced, and provokes varus deformity. It is also good to encourage external rotation at the shoulder, but not at the fracture site.



This brace is a simple molded cuff that extends from axilla to elbow. Its straps can be tightened to provide containment support, but not true immobilization, for the fracture.

This brace extends over the shoulder and may provide somewhat better support for more proximal fractures. However, it may also prove irritating during shoulder motion.

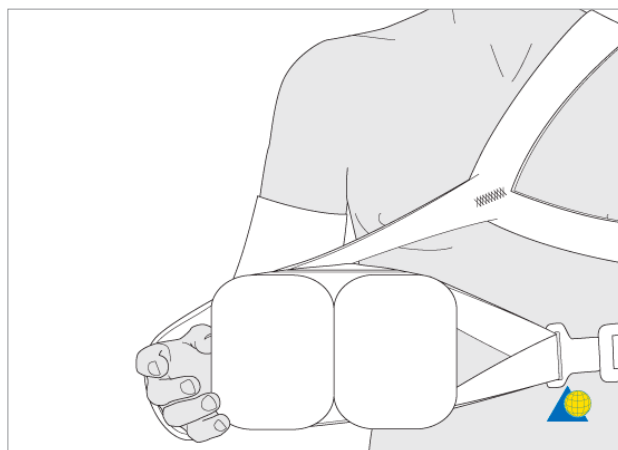




1 Humeral fractures

1.12 Humeral shaft fractures—Treatment with brace

If there is a varus tendency, the arm can be supported away from the body with a pad (“shoulder abduction pillow”) under the medial side of the elbow, as shown. This support can be quite helpful for obese patients.

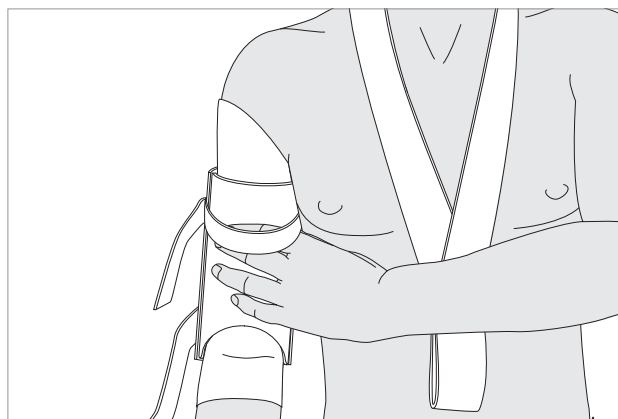


3.3 Brace care

As soon as comfort permits, the patient must be instructed in donning and removing the brace, and caring for the underlying skin.

By letting the arm hang straight down, the patient stabilizes the unbraced fracture with the force of gravity, and regains elbow extension. In this position he is able to shower, wash the arm, and replace the stocking with a clean one, usually daily.

The patient must learn to position the brace correctly. It must be high enough to allow elbow flexion. Because the brace tends to slide down the arm, he will need to reposition it periodically during the day. Rotational position of the brace is also important. The patient should be taught to position the brace so that its anterior inferior edge accommodates the proximal forearm during elbow



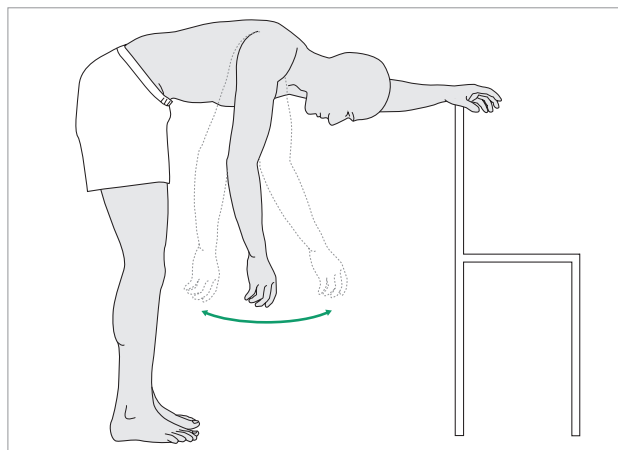
flexion. The longer medial and lateral sides of the brace's distal end should overlie the humeral epicondyles.

3.4 Beginning functional use

Simultaneous isometric contraction of flexors and extensors is important, as it stimulates fracture healing,

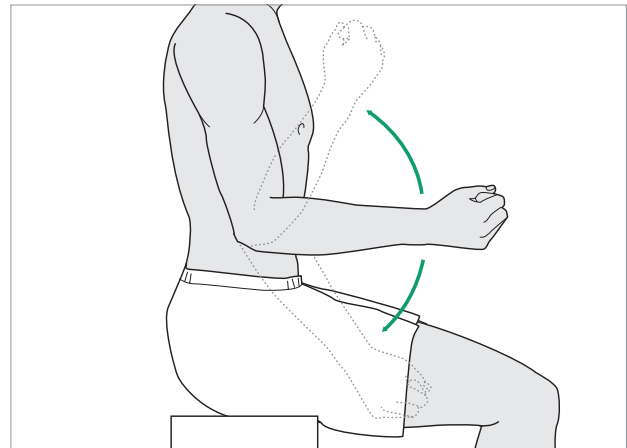
As soon as possible, begin pendulum exercises for passive shoulder flexion. Encourage active use of the hand and forearm.

improves support of the fracture inside the brace, and corrects fracture distraction produced by the weight of the distal arm. This can begin quite soon.





Try to regain active elbow flexion as soon as comfortable. Gravity should be allowed to help with elbow extension.



3.5 Patient monitoring

Early after injury, the patient will need to be seen every week or two to ensure satisfactory splint or brace position. Adequacy of analgesia must be assessed with adjustment of medication as needed. Check the skin under the brace, particularly around the elbow, for irritation. Confirm that the patient has learned to remove

and replace the brace correctly. Home health care assistance may be necessary, possibly including physical therapy at home, until the patient is independent in self care and use of the arm.

As healing progresses, upper extremity function is also encouraged.

4 Follow up

4.1 Healing assessment

X-rays are checked at three and six weeks and thereafter monthly, unless there is earlier concern about malalignment. Usually, progressive callus will be observed. The arm should be examined out of the brace. Stability of the fracture will become increasingly evident, and its tenderness will disappear. When active abduction of the shoulder to 90 degrees is possible without pain, or evident motion at the fracture, the brace may be discontinued. The patient may be comfortable sleeping without the brace before this, but its daytime use may be appropriately advised. Progressive resistance exercises and assisted shoulder motion can begin vigorously at this time.

Caution about risk activities and contact sports remains advisable until mature callus is visible and full strength and motion have been restored.

4.2 Delayed union

Healing is usually evident by three months. Occasionally at three months the fracture remains mobile to a degree, yet convincing clinical progress is observed, and healing at a slightly later date is to be anticipated. Generally however, failure to unite by three months is strong evidence that union is unlikely to occur without a change of treatment. Operative stabilization, with possible bone graft, is recommended without prolonged delay.

4.3 Radial nerve palsy - prevent contractures

Since radial nerve injuries with humeral fractures usually recover, nonoperative fracture management is often appropriate for patients with these combined injuries. It is important to include physical therapy and splinting for the hand to avoid wrist flexion and thumb adduction contractures and to maintain metacarpo-phalangeal

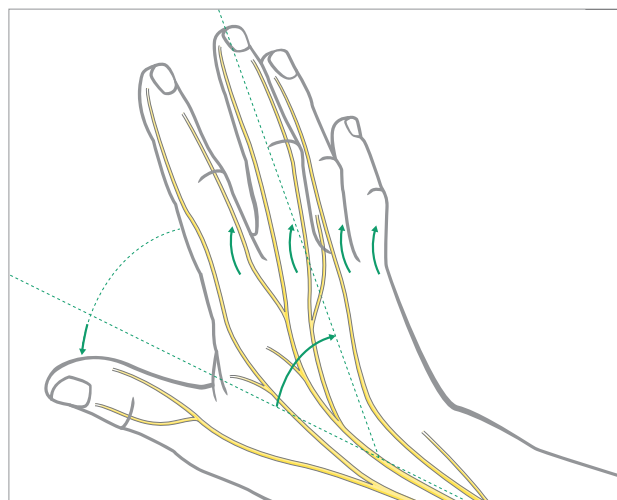


1 Humeral fractures

1.12 | Humeral shaft fractures—Treatment with brace

extension. The nerve is observed for progressive motor and sensory recovery. The former typically begins with return of brachioradialis and the radial wrist extensors. Finger extension and thumb abduction will follow. Electrodiagnostic testing might be considered at six weeks, if there is no clinical evidence of recovery at that time.

If there are no clinical and electromyographic signs of recovery at 3 months, surgical exploration and neurolysis of the radial nerve at the fracture site must be considered.





1

Humeral fractures

1.13 I Distal humeral fractures — Treatment with a splint

Indication **All 13-A type fractures, excluding 13-A1.3**

1 Principles

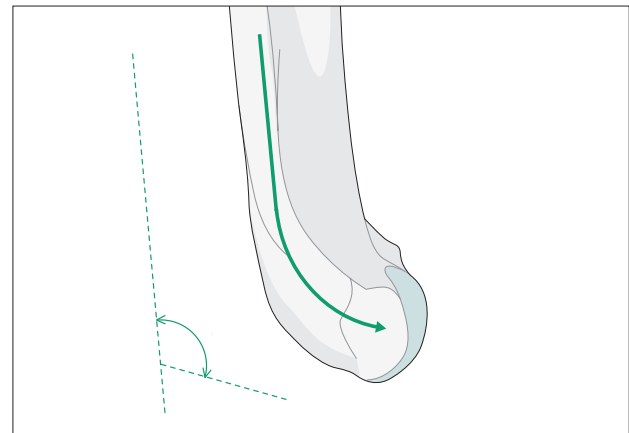
1.1 Indications

Nonoperative treatment by splinting is only indicated for undisplaced, extraarticular fractures, such as 13-A type

1.2 Anatomical consideration

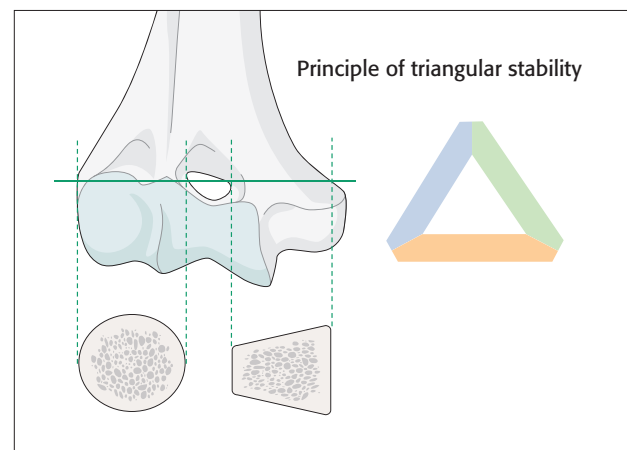
The distal third of the humerus is flattened in the coronal plane and curves anteriorly.

fractures. It is not suitable for 13-A1.3 type fractures though, which are characterized by incarceration of the fragment in the humero-ulnar joint, unless general contraindications to surgery are present.



Sometimes, the olecranon fossa and the opposing coronoid fossa communicate through an opening, the supratrochlear foramen.

Stability of the distal third of the humerus depends on the lateral and medial supracondylar columns linked distally, as a triangle by the condylar mass. Any rotation causing loss of bony contact decreases fracture stability.



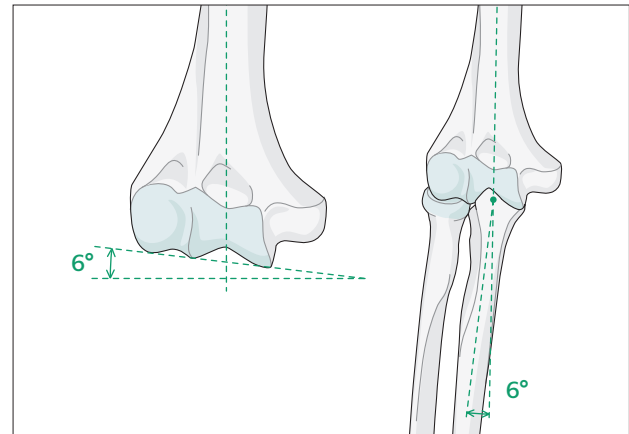


1 Humeral fractures

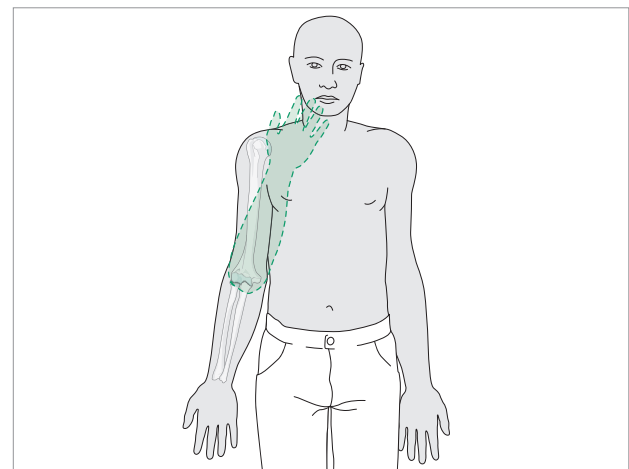
1.13 I Distal humeral fractures—Treatment with a splint

1.3 Distal articular surface

The medial part of the trochlea is bigger than the lateral part and the capitellum, resulting a valgus humero-antebrachial geometry (“carrying angle”) of long axis of the humerus passes through the centre of the trochlea about 6° in the coronal plane.

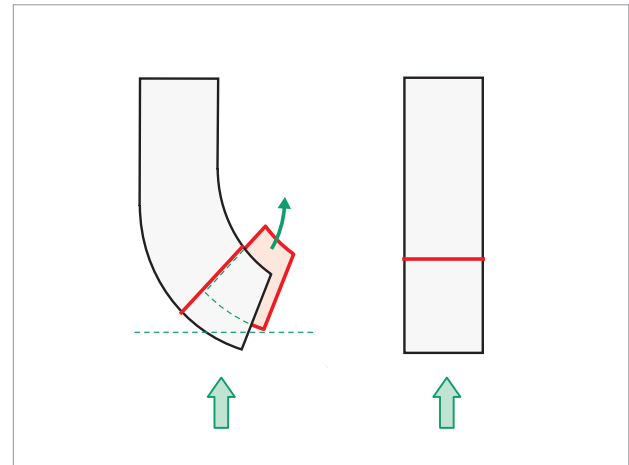


During elbow flexion the forearm moves on a plane such that the hand goes directly towards the mouth. Any changes in the valgus position after the reduction will strongly distort the original plane of movement. Adjustment to the distortion has been blamed for causing secondary shoulder problems.



1.4 Tendency to malalignment

There is a tendency to malalignment and to secondary anterior displacement after reduction.



Similarly, there is the risk of rotation and rotational malposition of the fragments. Reduction is made more difficult by the weight of the forearm acting on the fracture site.

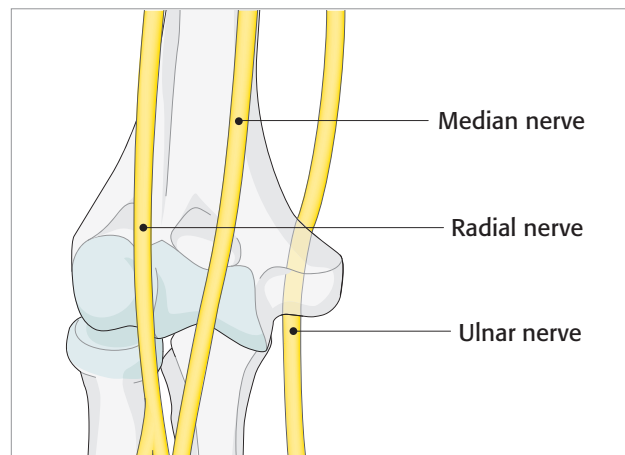
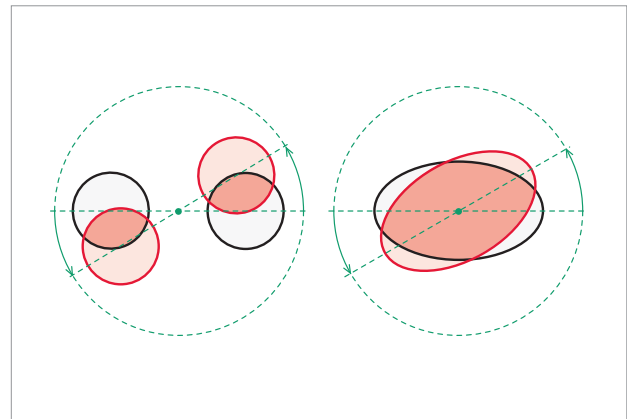
1.5 Deformity

Healing with any deformity (angulation, malrotation, and / or shortening) will usually cause significant elbow dysfunction. The restoration of normal elbow anatomy (anatomical reduction) is of high importance.

1.6 Nerves around the distal third of the humerus

Nerves on both sides of the distal humerus run very closely to the bone, especially the ulnar nerve, which perforates the medial intermuscular septum runs and then in its sulcus behind the medial epicondyle. It can be directly compressed in distal humeral fractures. The radial nerve perforates the lateral intermuscular septum as it loares the spiral groove on the humerus, torun anteriorly and distally. At the level of the radial head it divides into its deep and superficial branches.

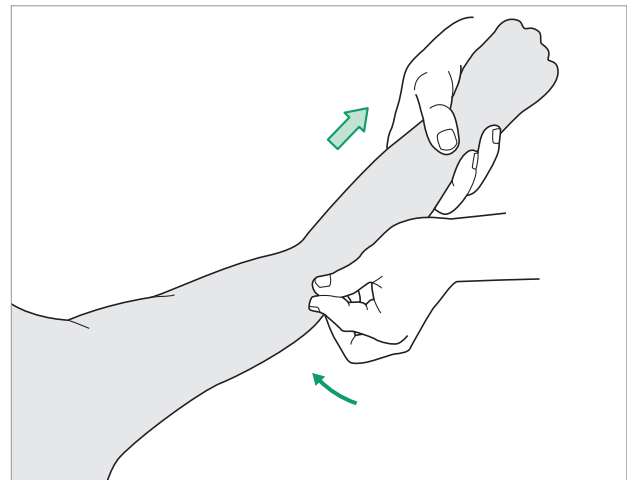
Note: The median nerve crosses the anterior capsule of the elbow joint, running into the forearm between the two heads of the pronator teres muscle.



2 Reduction of A1.1 and A1.2 type fractures (apophyseal avulsion without incarceration)

2.1 Reduction of fracture fragment

The reduction is performed under general anesthesia, or using an axillary block. The arm is pulled with one hand and the fracture fragment is palpated with the other hand. Reduction of the fracture fragment is obtained pushing it into its appropriate position.



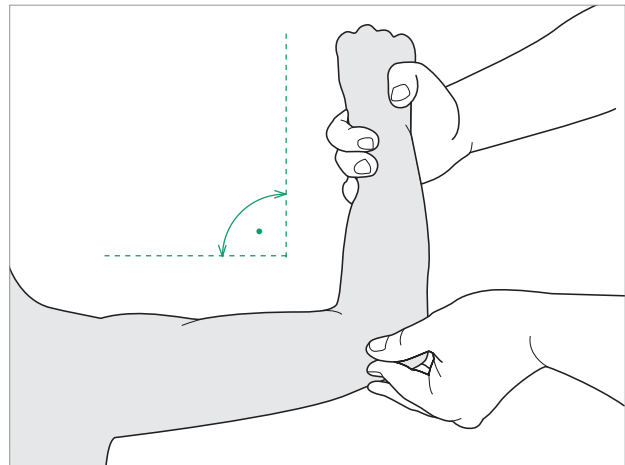


1 Humeral fractures

1.13 I Distal humeral fractures—Treatment with a splint

2.2 Flexion of the elbow

Flex the elbow up to 90° whilst maintaining the reduction, and apply the posterior splint.

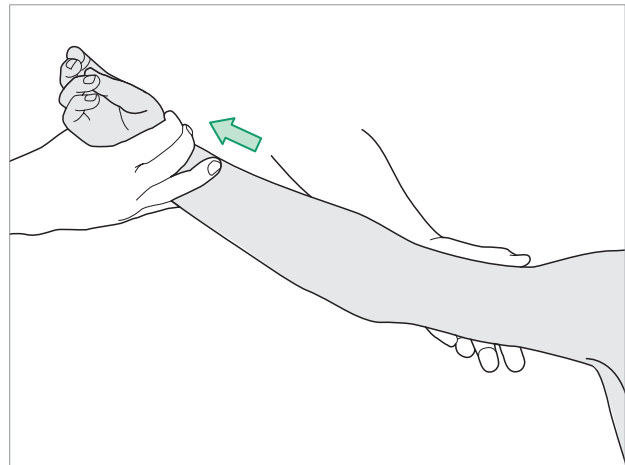


3 Reduction of A2 and A3 type fractures (simple or multifragmentary metaphyseal)

3.1 Distract the fracture

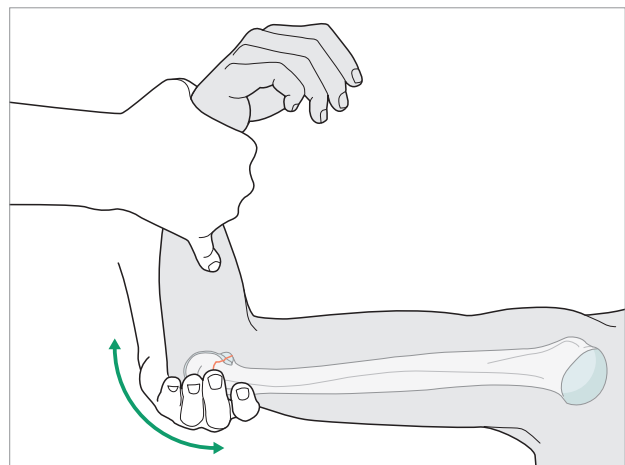
The reduction is performed under general anesthesia, or using an axillary block.

The arm is pulled with one hand while the other hand palpates the bony eminences of the distal humerus, ie, medial and lateral epicondyles. Distraction of the fracture is obtained by pulling the forearm.



3.2 Flex elbow

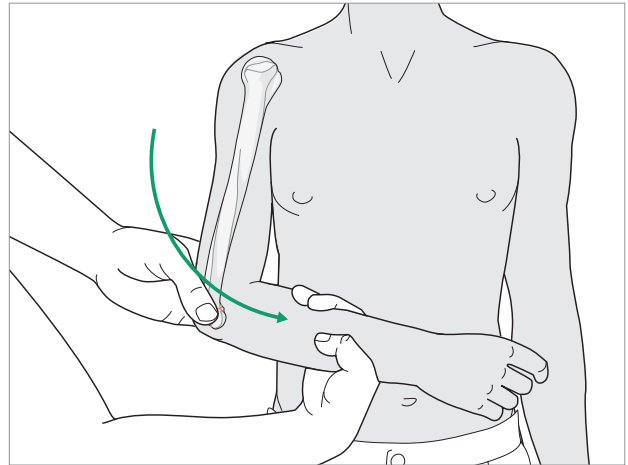
Flex the elbow up to 90°, whilst maintaining the distraction the whole time - as the elbow flexes the reducing hand also applies distraction.





3.3 Correct rotation

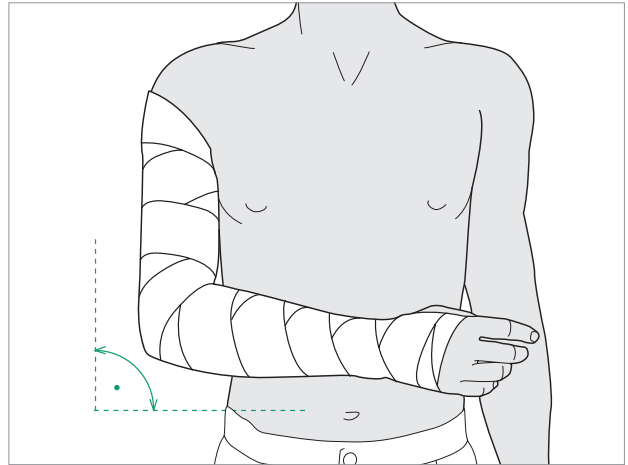
Correct any rotational displacement by applying force to the forearm, whilst still distracting. Once reduction is complete, the distraction is gently discontinued.



4 Fracture splint management

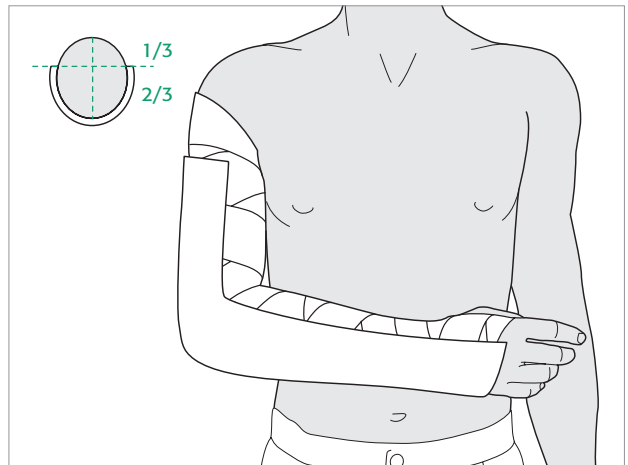
4.1 Apply cast padding

With the patient sitting, if possible, cast padding should be wrapped around the upper arm, elbow, forearm and hand, down as far as the transverse crease of the hand (leave the MP joints free). Keeps the elbow in 90° flexion and the forearm in neutral rotation. Make sure that the epicondyles of the humerus and the antecubital area are well padded.



4.2 Apply splint

A splint of fiberglass, or plaster, is applied on the posterior aspect of the arm and forearm. It should be wide enough to cover more than half of the circumference of the arm and forearm. It is secured with an elastic bandage that should not be too tight.



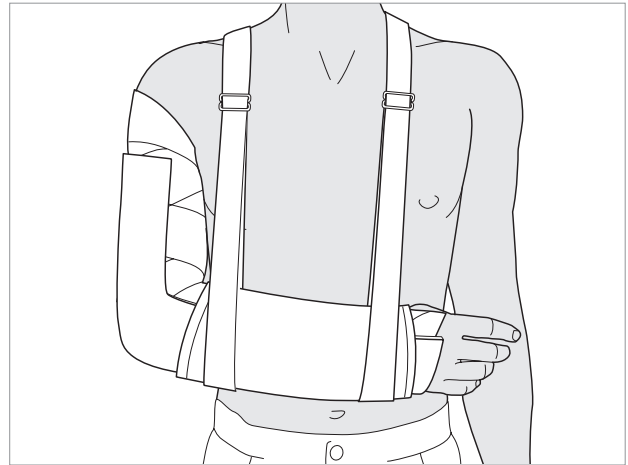


1 Humeral fractures

1.13 I Distal humeral fractures—Treatment with a splint

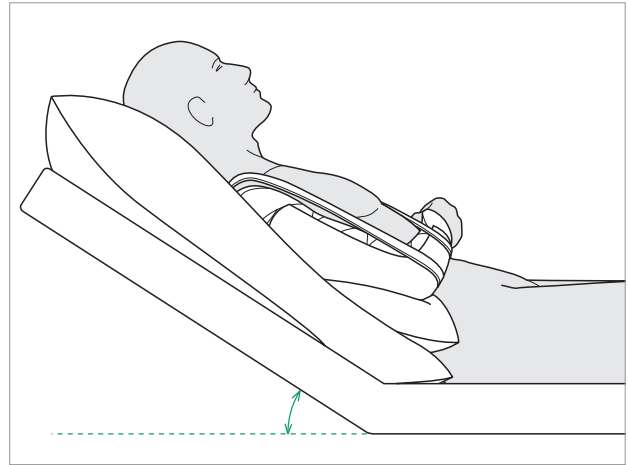
4.3 Sling

The injured arm is supported in a sling.



4.4 Analgesia

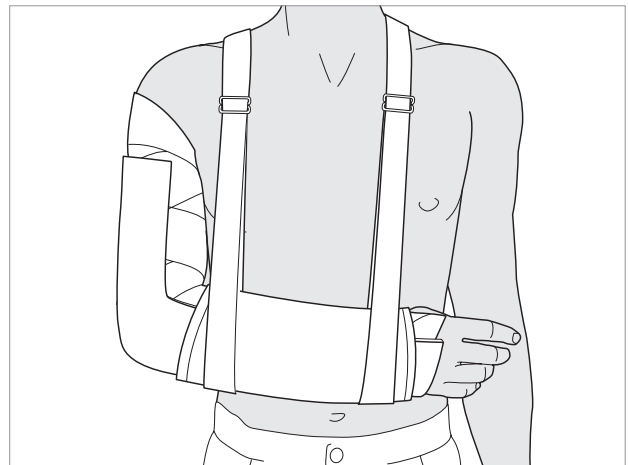Analgesia will be required. The patient is usually more comfortable in a sitting or semireclining position, with the elbow elevated on pillows at least for the first few weeks. Fragment motion and crepitus may well be perceived, and the patient should be reassured that this is normal, stimulates healing, and will gradually settle.



5. Aftertreatment

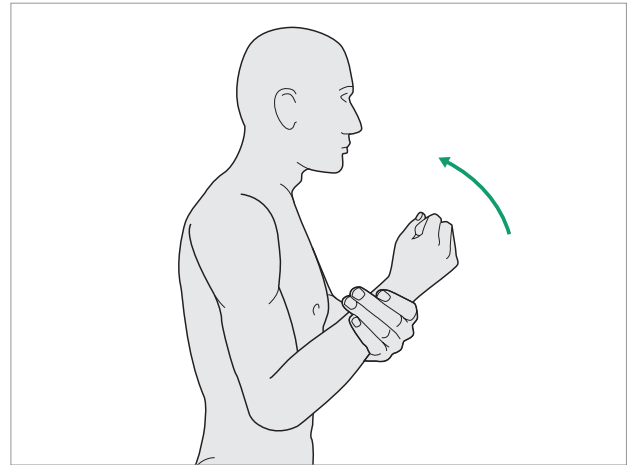
The arm is immobilized in a splint for comfort with the elbow at 90 degrees of flexion. Active exercises of the elbow should be initiated within a few days. The elbow is prone to stiffness, and fixation that is adequate to allow functional use of the arm for light tasks is important.

Avoidance of shoulder abduction will limit varus elbow stress. Shoulder mobility should be maintained by gravity-assisted pendulum exercises in the sling.





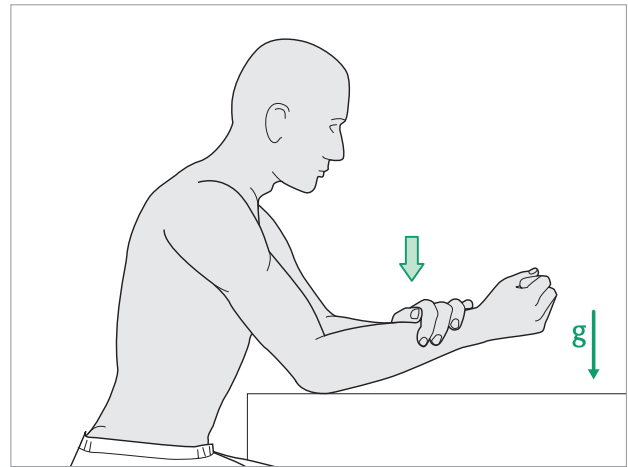
Active assisted elbow motion exercises are performed by having the patient bend the elbow as much as possible using his/her muscles, while simultaneously using the opposite arm to push the arm gently into further flexion. This effort should be sustained for several minutes, the longer the better.



Next, a similar exercise is done for extension, see illustration.

5.1 Load bearing

No load-bearing or strengthening exercises are allowed until early fracture healing is established, a minimum of 6-8 weeks after the fracture. Weight bearing on the arm should be avoided until bony union is assured.





2 Forearm fractures

2.11 I Proximal forearm fractures— Treatment with cast or splint

Indication **21-A1, 21-A2.2, 21-A2.3, 21-B1, and 21-B2 type fractures**

1 General considerations

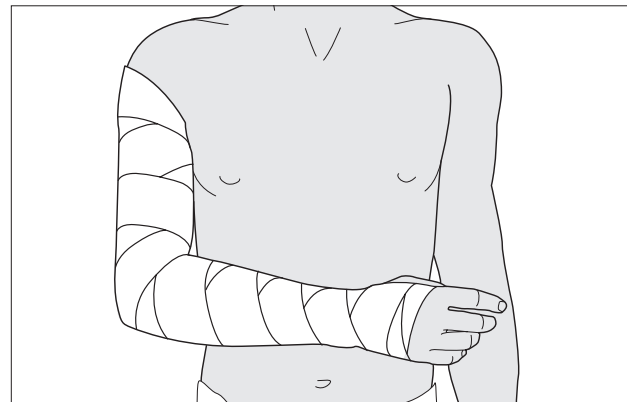
Immobilization of the elbow in a cast or splint is only indicated in undisplaced and stable fractures. A splint may be faster to apply, and easier to remove.

The time of immobilization should be as brief as possible to prevent stiffness of the elbow. Ideally, this would be 2 or 3 weeks.

While the patient is in the cast, finger and shoulder movements are to be encouraged.

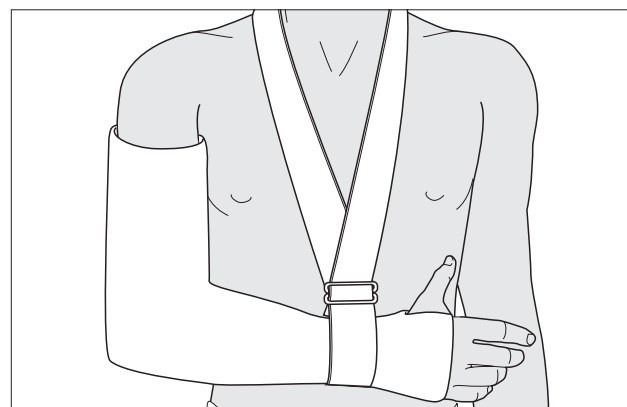
2 Apply padding

The elbow is in 90° flexion and the forearm in neutral position of rotation. With the patient sitting, if possible, cast padding should be wrapped around the upper arm, elbow, forearm and hand. Finish wrapping at the transverse crease of the hand (leave the MP joints free). Make sure that the epicondyles of the humerus and the antecubital area are well padded.



3 Application of an above elbow cast

An above elbow cast is applied with the elbow flexed 90 degrees and the forearm in mid-pronation-supination position. Either fiberglass or plaster cast material may be used. Avoid constricting the antecubital area. Trim the cast as needed to protect axilla and around thumb and fingers. Secure the injured arm with a sling.

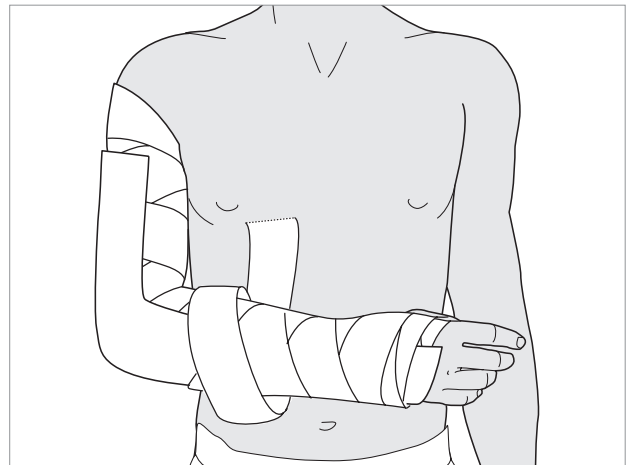




4 Application of a splint

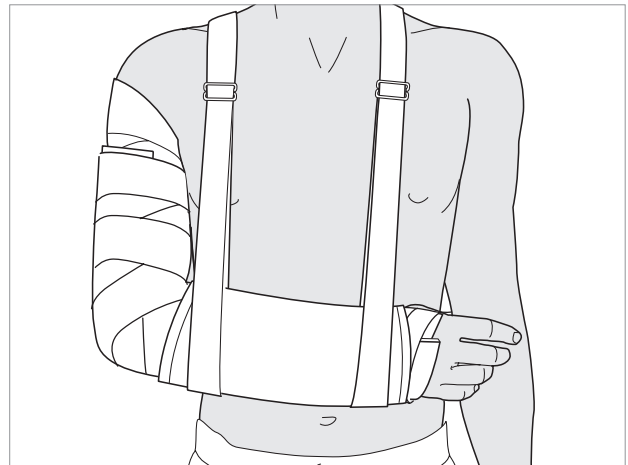
4.1 Apply splint

After padding, apply a splint of fiberglass or plaster on the posterior aspect of the arm and forearm. It should be deep enough to cover more than half of the circumference of the arm and forearm. Secure the splint with an elastic bandage that should not be too tight.



4.2 Sling

Secure the injured arm with a sling.





2 Forearm fractures

2.11 II Proximal forearm fractures – Functional treatment of 21-A1.1 fractures

Indication **21-A1.1 type fractures**

Functional treatment

Minimally displaced A1.1 fractures, without associated injury, can often be treated functionally, allowing light use as tolerated, but avoiding elbow extension against resistance.

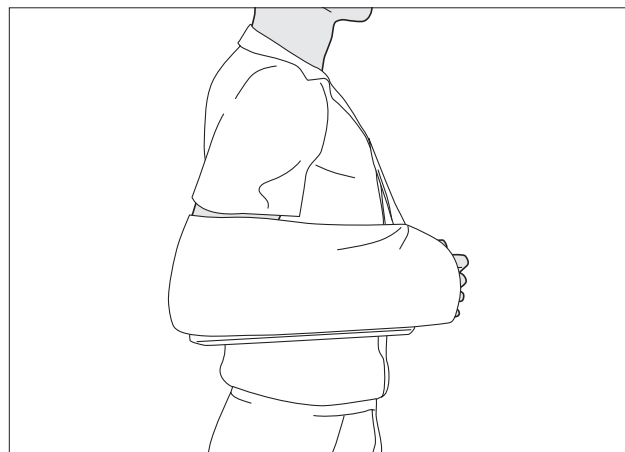
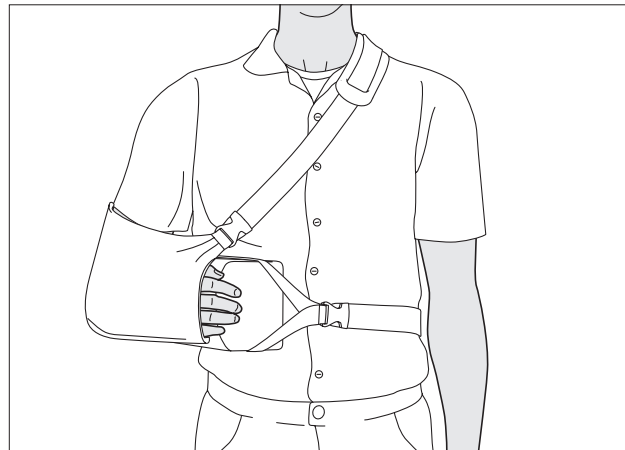
Analgesia is given as needed.

A sling, with or without swath, may be used as needed, particularly at night, and removed as comfort permits.

If there is concern about the fracture displacement, follow-up with x-rays within 10-20 days is advisable.

Healing should be secure within 4-6 weeks, following which resistance exercises may begin.

A cuff and collar sling may be used as an adjuvant for pain control.





2 Forearm fractures

2.11 III Proximal forearm fractures— Functional treatment of 21-A2.1 fractures

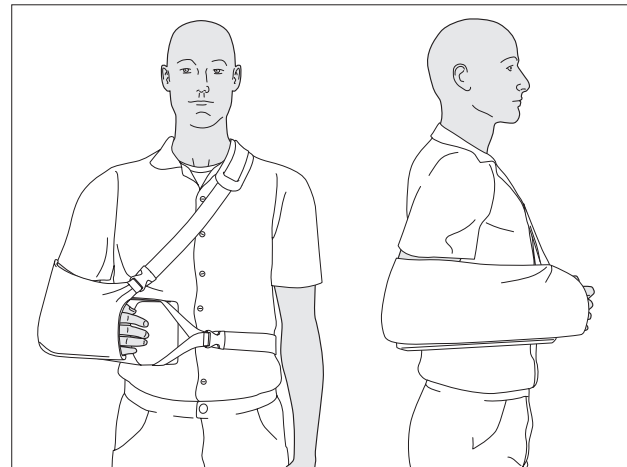
Indication **21-A2.1 type fractures**

Functional treatment

A2.1 bicipital tuberosity fractures without significant functional loss, particularly in older patients or poor operative candidates, may reasonably be treated functionally, allowing light use as tolerated but avoiding elbow flexion against resistance.

Analgesia is given as needed.

A sling, with or without swath, may be used as needed, particularly at night, and removed as comfort permits.





2 Forearm fractures

2.11 IV Proximal forearm fractures— Functional treatment of 21-A2.2 fractures

Indication **21-A2.2 type fractures**

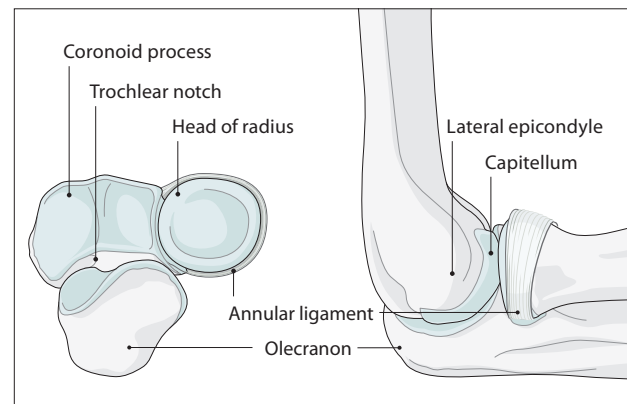
1 General considerations

The elbow is a complex joint with three separate articulations, ie, the humeroradial, the humeroulnar and the radioulnar joint. Immobilization of the elbow may compromise patient's range of motion. Early movement is encouraged in:

- Fractures involving less than 30% of the radial head, undisplaced or minimally displaced (<2 mm)
- Radial neck fractures with less than 20 degrees of angulation and unrestricted elbow movement.

In the elderly, high surgical risk, and low demand patient with osteoporotic bone, there is a place for early motion in comminuted fractures of the proximal ulna or radius when the elbow joint is stable.

Note: In A2.1 fractures in low demand patients, there is no indication for surgery.



2 Functional Treatment

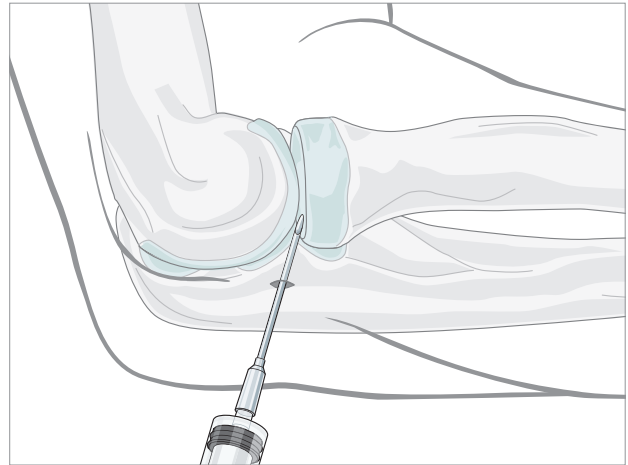
2.1 Pain control

Adequate pain management helps to achieve early range of motion. Early aspiration of the radioulnar joint and intraarticular injection of local anesthetics might be performed. This allows analgesia for clinical assessment of range of motion.

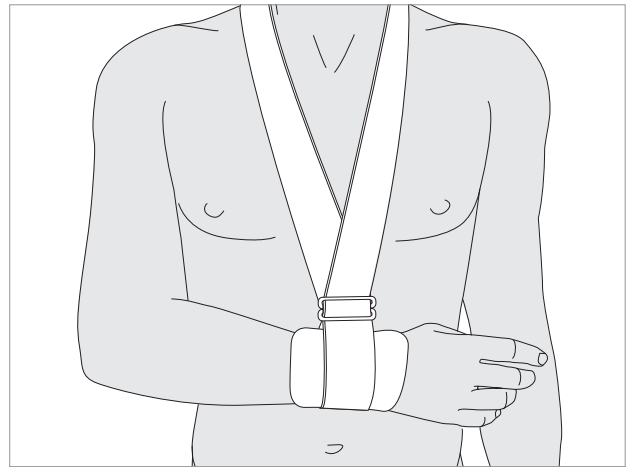


Aspiration technique

Enter the elbow through the anconeus triangle on the radial side. Flex and fully supinate the forearm to protect the radial nerve. The surface landmarks are the radial head, the lateral humeral epicondyle, and the tip of the olecranon (anconeus triangle). Insert an 18 gauge needle into the joint through the soft spot in the center of the triangle. With this approach, only anconeus and capsule are penetrated.

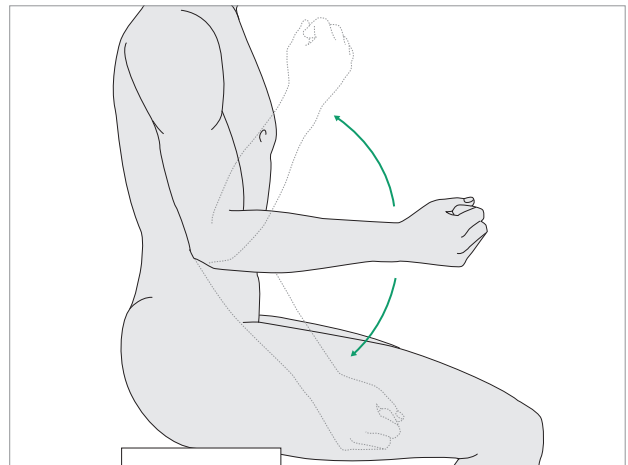


A cuff and collar sling may be used as an adjuvant for pain control.



2.2 Mobilization

Encourage the patient to move the elbow actively in flexion, extension, pronation and supination as soon as possible.

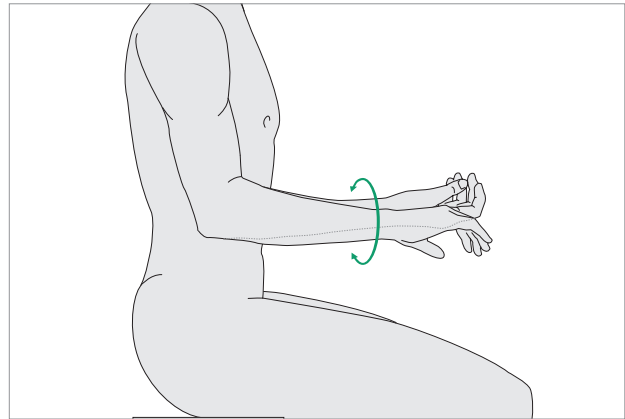




The sling may be removed for early range of motion exercises.

Monitor the patient at regular intervals to assess and encourage range of motion.

Note: Shoulder, wrist and hand movement is also encouraged.





2 Forearm fractures

2.12 I Forearm shaft fractures – Treatment with a cast

Indication **All 22-A, 22-B and 22-C type fractures, excluding 22-B1.3, 22-B2.3**

1 Indications

The only adult forearm shaft fractures in which a satisfactory functional outcome can be expected after nonoperative treatment are A1.2 fractures which are undisplaced, minimally displaced (less than 50% translation, less than 10° angulation), or stably reduced, isolated ulnar fractures with no compromise of either radioulnar joint. According to Sarmiento et al, the more proximal the level of the fracture the higher the risk of impaired pronation. See:

- Mackay D, Wood L, Rangan A (2000) The treatment of isolated ulnar fractures in adults: a systematic review. *Injury*; 31(8): 565-70.

- Sarmiento A, Latta LL, Zych G, et al (1998) Isolated ulnar shaft fractures treated with functional braces. *J Orthop Trauma*; 12 (6): 420-3; discussion 423-4.
- Handoll HH, Pearce P (2009) Interventions for isolated diaphyseal fractures of the ulna in adults. *Cochrane Database Syst Rev*; Jul 8; (3): CD000523.

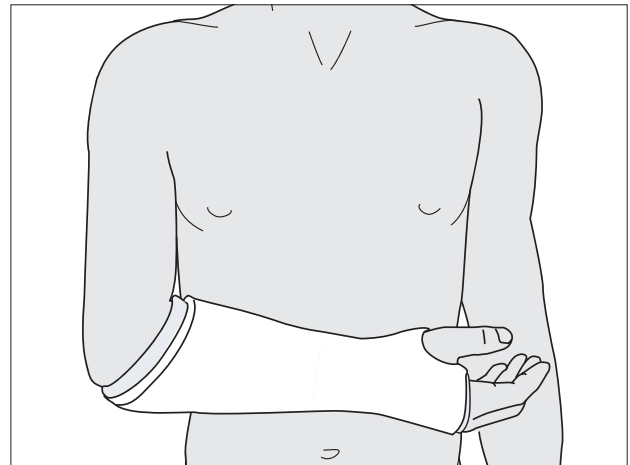
In all other cases, if nonoperative treatment is necessary because of severe soft-tissue compromise or the patient being unfit for surgery, the functional outcome will inevitably be suboptimal.

2 Treatment principles

The basic principles of nonoperative treatment of forearm shaft fractures are:

- 1) Except in 22-A1.2 fractures, both wrist and elbow joints must be included in the cast.

Note: Mackay et al. and Sarmiento & Latta suggest that in isolated ulnar fractures, above elbow splintage is not necessary.





2) If the elbow joint is included in the cast, it should be in 90° flexion.

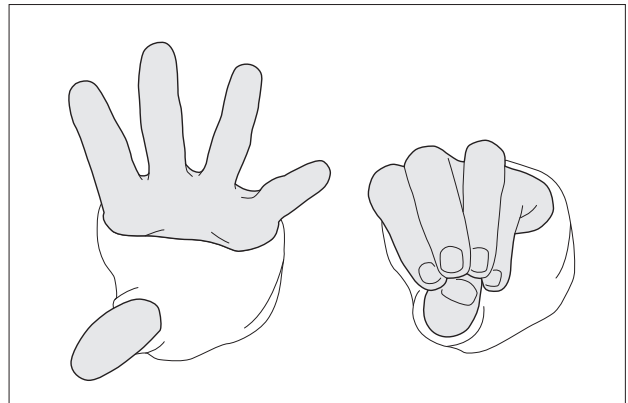
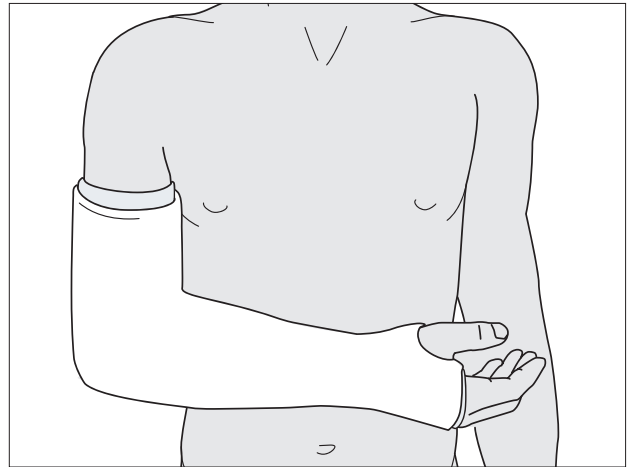
3) The general form of the forearm should be restored.

Note: For 22-A1.2 fractures, this is usually not required.

4) The cast should be well-padded and split along its whole length in any injury where progressive swelling is to be expected.

5) The cast should not extend beyond the proximal palmar flexor crease, in order to permit full flexion of the MCP joints of the fingers.

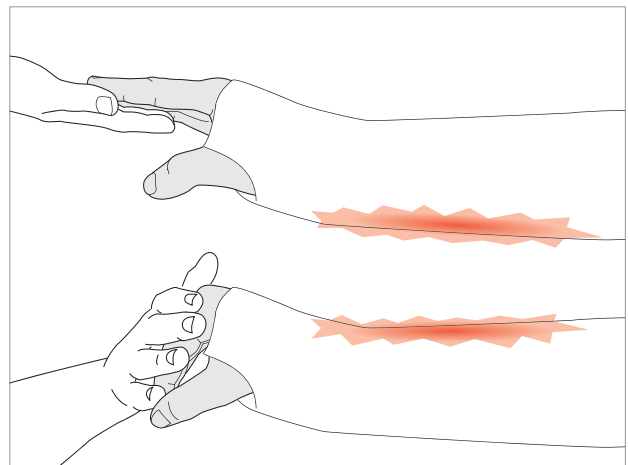
6) The thumb should not be included in the cast.



Sarmiento and Latta (Closed Functional Treatment of Fractures, Springer Verlag, 1981, p.384) recommend that the cast be applied with the arm suspended from Chinese fingers traps and the elbow at a right angle. This

results in a forearm posture of “relaxed supination”: they combine this with careful moulding anteroposteriorly in such a manner as to separate the two bones and tension the interosseous membrane.

Meticulous clinical observation for compartment syndrome must be undertaken. Watch out for increasing inappropriate pain, especially with passive stretching of the muscles of the affected compartment(s).





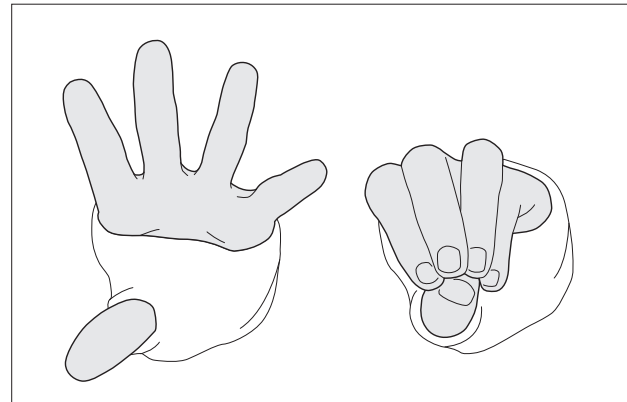
3 Aftercare following nonoperative treatment

3.1 Record of fracture alignment

Document fracture position radiographically after casting, for future reference.

3.2 Extension and flexion of the fingers

Start with finger exercises immediately after casting. Maintain elevation of the limb for 24 hours, paying special attention to pain, especially with passive extension and flexion to the fingers, which could indicate compartment syndrome.



3.3 Broad arm sling

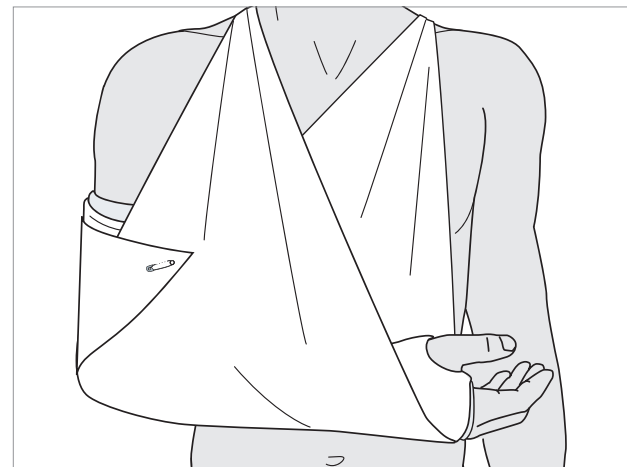
Generally, a broad arm sling is preferable to a collar and cuff sling.

The collar and cuff can induce ulnar bowing due to cast dropping in the forearm, when the forearm muscles waste.

The ulnar bowing is produced because the wrist is still firmly held by the collar and cuff.

In 22-A1.2 fractures, the broad arm sling is used to support the weight of the cast for the first 7-10 days. It is advisable to practice active elbow extension exercises out of the sling on a regular basis if a short arm cast is being used.

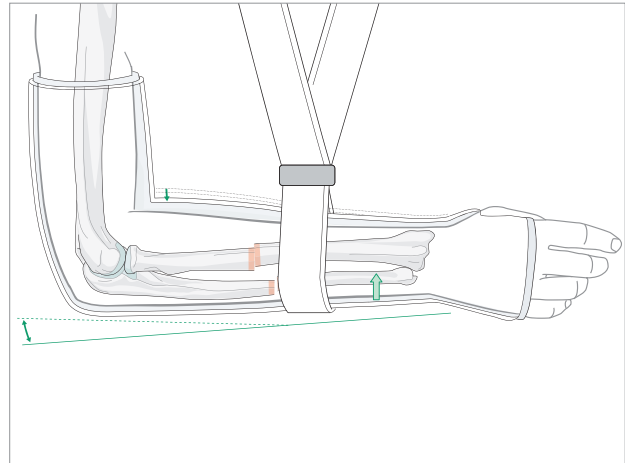
The position of the ulnar fracture should be checked radiographically at 1 week and 2 weeks after the onset of treatment. Should the fracture position become unacceptable, compression plating is indicated.





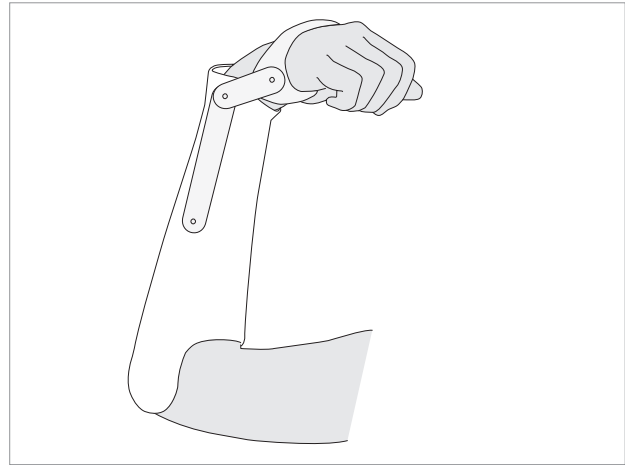
3.4 Functional bracing

In A1.2 fractures and other relatively simple adult forearm shaft fractures which have had to be treated non-operatively and which have not displaced on follow-up x-rays, functional bracing might be considered, as a means of enhancing rehabilitation.



3.5 Change of treatment method

In occasional cases in which nonoperative treatment was initially indicated for soft-tissue or general medical reasons, the patient's status may improve to the point that operative treatment can be reconsidered. Such a decision will need to be made within 3 weeks of injury, beyond which stage satisfactory reduction of such fractures is unlikely to be feasible.





3 Femoral fractures

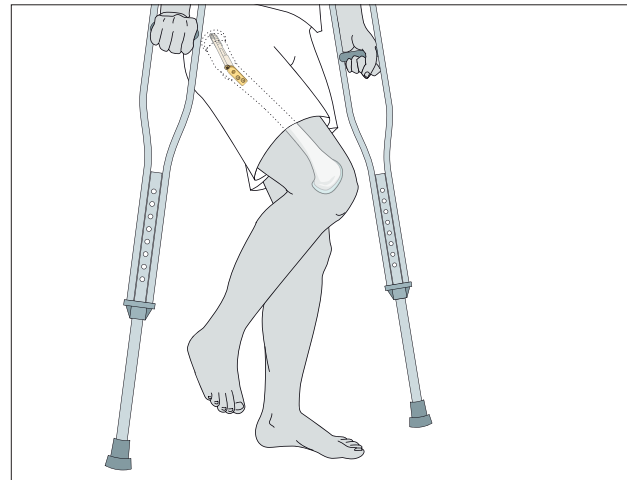
3.11 I Proximal femoral fractures - Management with minimal resources

Indication **All proximal femoral fractures**

1 Introduction

Fractures of the upper end of the femur should be treated operatively.

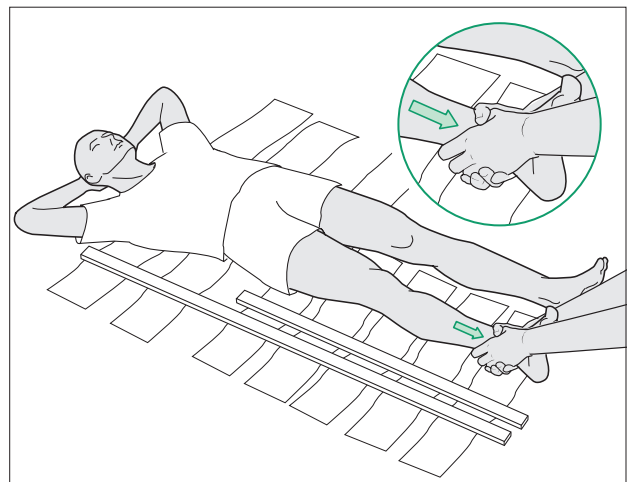
They should only be considered for nonoperative fracture treatment if there are neither facilities, nor skills, for surgical treatment.




2 First Aid

The ABC of primary care for the injured always takes precedence over the fracture treatment. Once the safety of the patient has been established, attention is directed to the fracture.

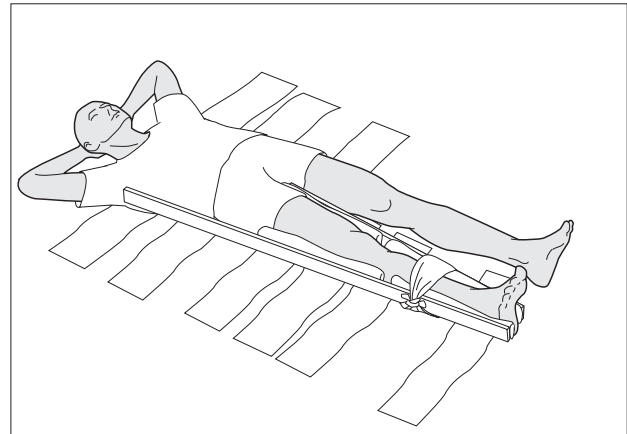
It is important in treating any femoral fracture to splint the whole leg as soon as possible, and before transport of the patient. For that purpose you need two firm boards or sticks along the leg, suitably padded, one on the inside and one along the leg and the body on the outside.





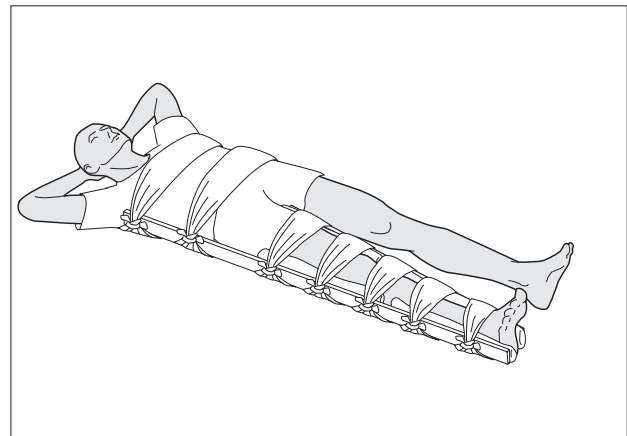
Any soft material such as clothing, blankets, etc. can be used as emergency padding.

The splints should then be kept in place by bandages around both splints and ...

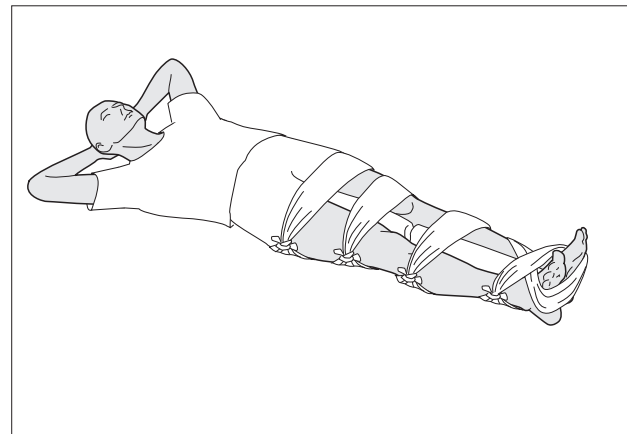


... the leg as well as the body.

Suitably splinted, the patient can be transported to the chosen hospital facility.



If no boards are available some stabilization can be achieved by splinting the fractured leg to the uninjured leg, with padding in between.



3 Principles

Once a radiological diagnosis has been made, decisions about non-operative management can be taken.

For non-impacted intracapsular fractures, the best non-surgical care is to relieve pain and mobilize the patient despite the fracture. These fractures will not unite with non-surgical treatment and mobilization of the patient as a whole is of paramount importance.

If a radiological diagnosis is not available, the possibility of a displaced intracapsular fracture of the proximal femur may be suggested by external rotation with slight to moderate shortening (2.5 – 5 cm), which increases only slightly with proximally directed pressure on the leg. Non-operative treatment of such patients is not based upon bone healing, which, as noted, does not occur without surgical treatment. Traction can be omitted, or discontinued and the patient mobilized as soon as comfort permits.





If there is marked thigh shortening which increases progressively, or is associated with palpable bone deformity, the patient is more likely to have an extracapsular fracture with potential for healing. Patients with these injuries are reasonable candidates for 6-8 weeks of traction, as described below, followed by progressive

ambulation, with delayed weightbearing, in hopes of avoiding excessive deformity.

For proximal femur fractures that are likely to be extracapsular (pertrochanteric or subtrochanteric), the non-operative regimen is as follows.

3.1 Straight skin traction

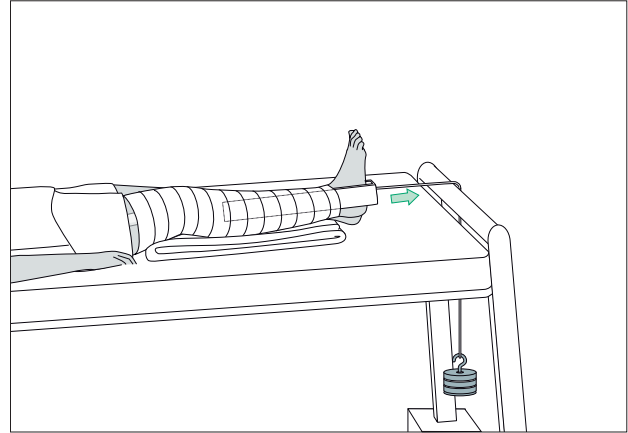
Nonoperative treatment means that the patient will be in some form of traction for at least 6-8 weeks, often 10-12 weeks.

The preliminary treatment usually is straight skin traction, later converted to skeletal traction.

Note the padding under the patient's calf, to keep the heel from pressing on the bed beneath it.

Disadvantages of prolonged skin traction are:

- Loosening
- Constriction
- Friction with skin irritation
- Allergy



3.2 Hamilton-Russell (balanced) skin traction

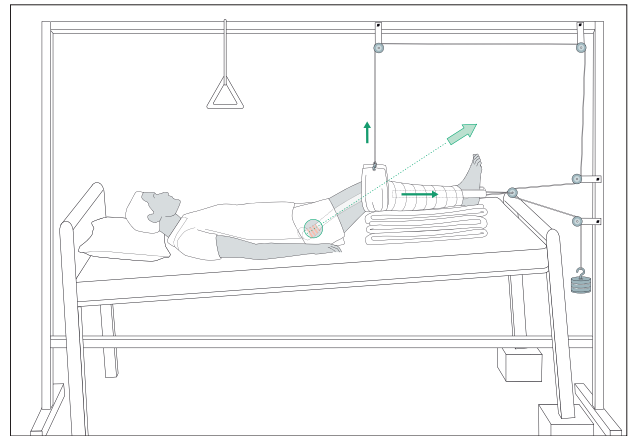
If skin traction is likely to be used for more than 24 hours, greater patient comfort and better control of the fracture can be achieved by using Hamilton-Russell skin traction.

To apply Hamilton-Russell traction, a dedicated orthopedic bed, or a standard bed in combination with a mobile Balkan beam frame, is needed.

A padded sling is placed behind the slightly flexed knee and skin traction applied to the lower leg. The traction cord and pulley system are shown here.

The principle of the parallelogram of forces determines that the upward pull of the sling and the longitudinal pull of the skin traction create a resolution of force in the line of the femur, as illustrated.

This configuration of traction and leg support also can be adjusted to control femoral rotation, by directing the upward support medially or laterally. Generally, to minimize external rotation at the fracture, the patella should be pointing upward, nearly perpendicular to the bed surface.

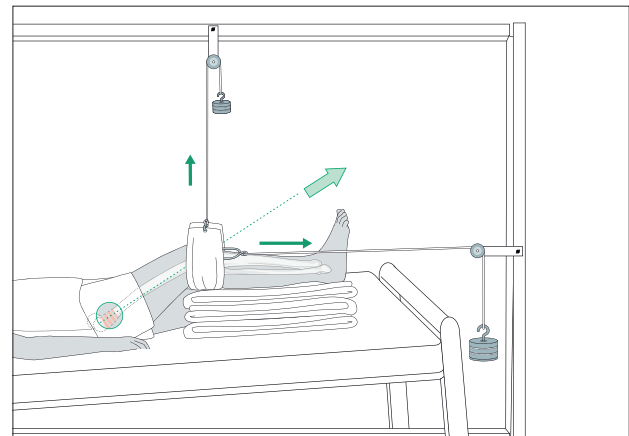




A simpler alternative to this technique involves two separate systems.

- a sling suspended from the overhead frame, or supported with a rope and pulley counterweight, to provide an upward force, which lifts the leg off the bed
- longitudinal (distal) traction applied with skin or skeletal technique.

The resulting vector force, as illustrated, is oblique, the vector sum of the upward and distal forces applied by the two weights.



Note: With any longitudinal traction, the foot of the bed must be raised, tilting the bed, to avoid the traction weight's pulling the patient down the bed.

With the tilted bed the weight of the patient acts as countertraction.

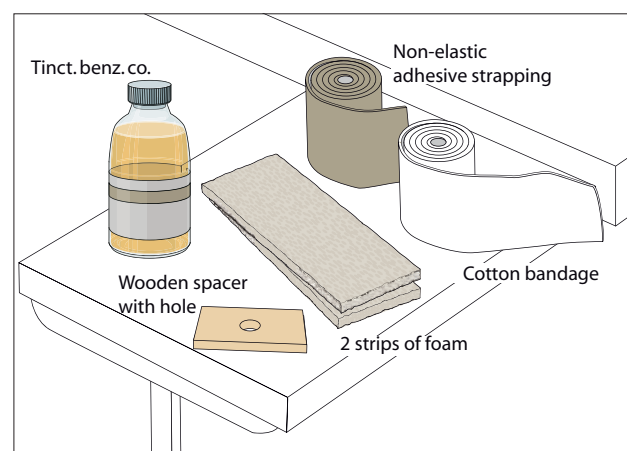
4 Skin traction

4.1 Application

This photograph shows a commercially available skin traction kit.



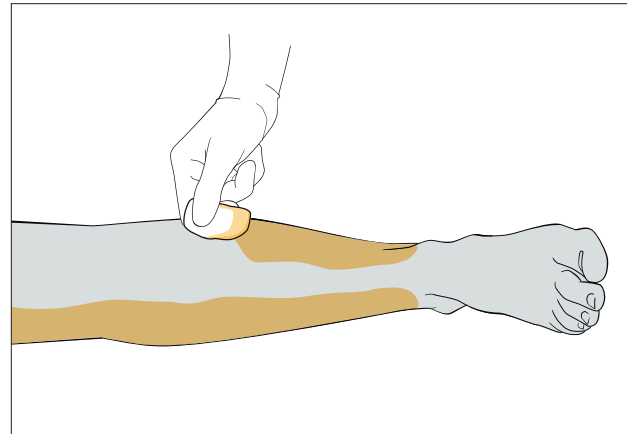
A simple skin traction kit can be made easily, from a roll of non-elastic adhesive strapping (approximately 3 inches, 8 cms, wide), some foam padding for the malleolar region and a wooden spacer block (suitably drilled for cord attachment).





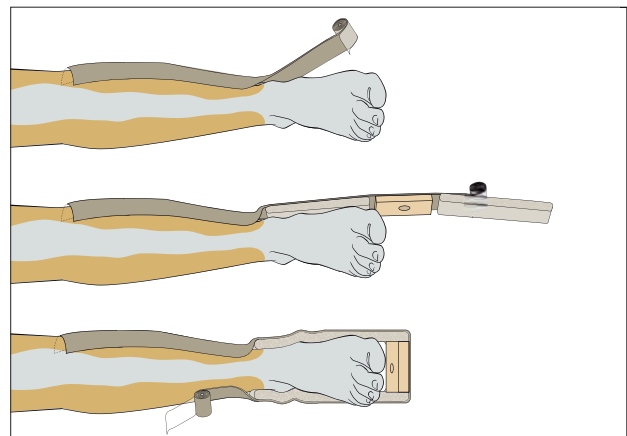
Prior to the application of the adhesive traction strip, the skin is painted with friar's balsam (Tinct. benz.co.), or equivalent.

The strip is then applied to the lower leg, from the level of the knee.



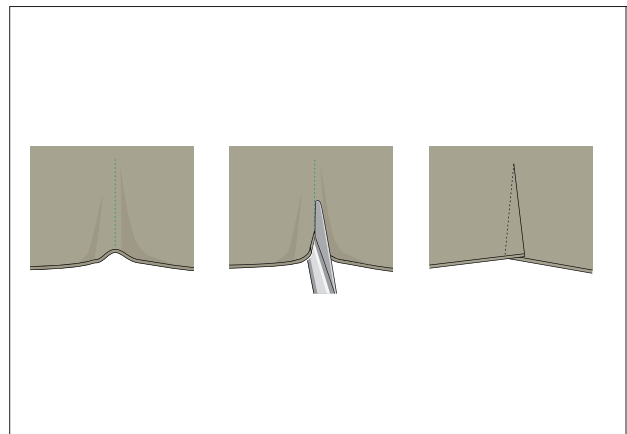
The strapping is applied to the inner side of the leg, then unrolled a little further, to allow placement of the spacer and of the foam; it can then be applied to the outer side of the leg.

It is important to ensure that the wooden spacer lies transversely, i.e. parallel to the sole of the foot.



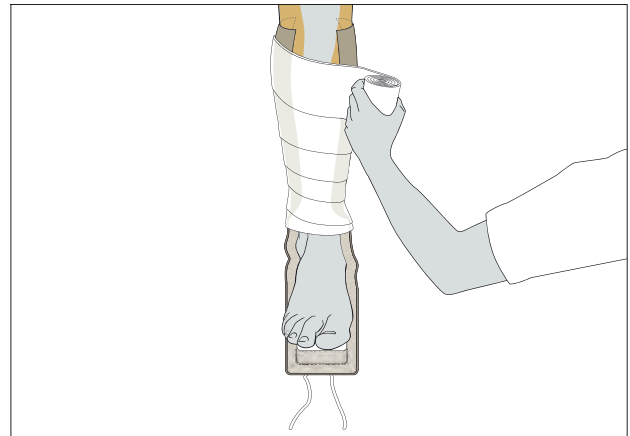
To prevent the development of blisters, the skin traction needs to be applied without folds or creases in the adhesive material and the covering bandage should be non-elastic.

Should a crease be inevitable, due to the contour of the limb, the creased area should be lifted, partially slit transversally and the edges overlapped.

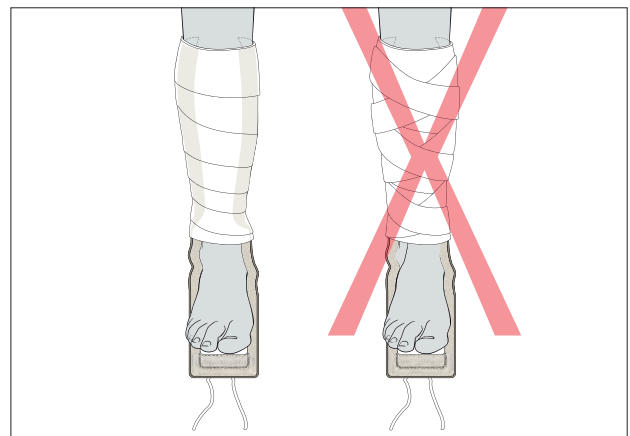




Once the adhesive strip is satisfactorily in place, ensuring that the padded lower section overlies the malleoli, an inelastic bandage is carefully wrapped around the limb from just above the malleoli to the top of the strip.

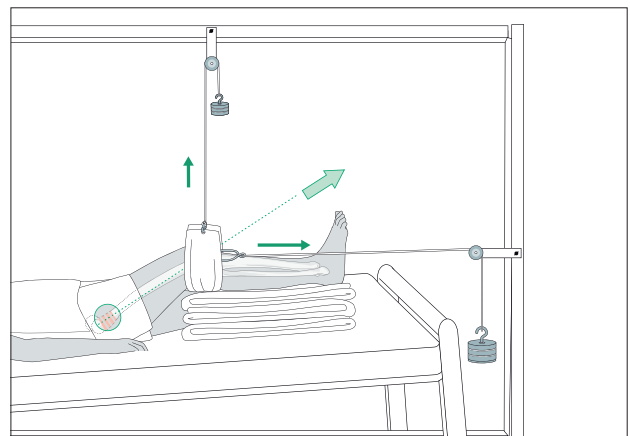


Apply the overlying bandages spirally, overlapping by half.



5 Skeletal traction

The initial skin traction should soon be converted to skeletal traction via a tibial pin.

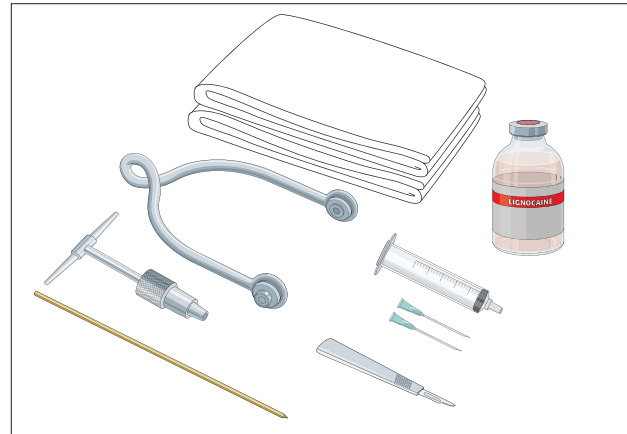




5.1 Preparation for applying skeletal traction

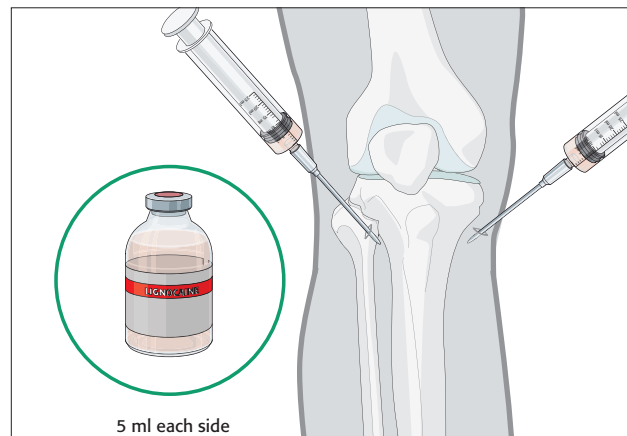
This is greatly aided by the use of a pre-assembled, sterile pack, containing the following items:

- Sterile towels
- Disinfectant
- Syringe
- Needles
- Local anaesthetic
- Scalpel with pointed blade
- Sharp pointed Steinmann pin, or Denham pin
- Jacobs chuck with T-handle
- Stirrup



5.2 Local anaesthesia

After painting the skin with antiseptic and draping with sterile towels, inject a bolus of local anaesthesia (5 ml of 2% lignocaine) on each side of the tibial tuberosity, into the lateral skin at the proposed site of pin insertion and medially at the anticipated exit point, infiltrating down to the periosteum.



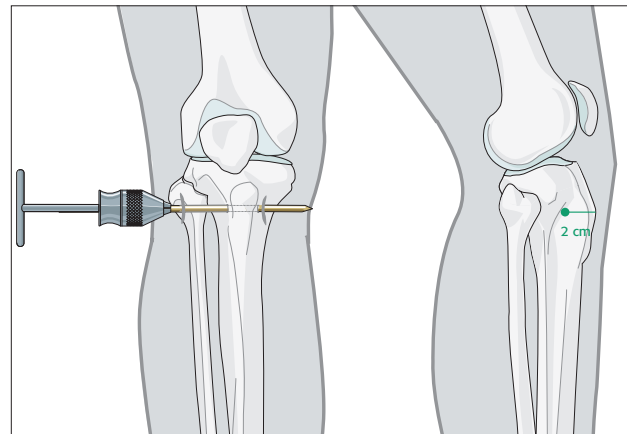
5.3 Insertion of traction pin

At the entry point, a stab incision is made through the skin with a pointed scalpel.

A Steinmann, or preferably a Denham pin (a Denham pin has a short threaded section in the centre to prevent side-to-side motion of the pin in the bone), mounted in the T-handle, is inserted manually at a point about 2 cm dorsal to the tibial tuberosity.

As the pin is felt to penetrate the far cortex, check that the exit will coincide with the area of local anaesthetic infiltration. If not, inject additional local anaesthetic. Once the point of the pin clearly declares its exit site, make a small stab incision in the overlying skin.

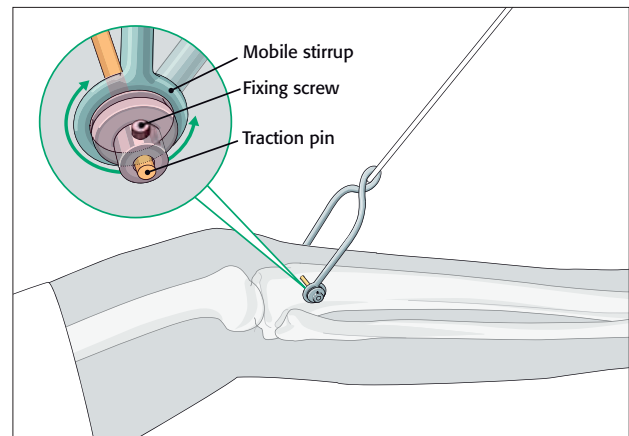
Once the pin is in place, ensure that there is no tension on the skin at the entry and exit points. If there is, then a small relieving incision may be necessary.



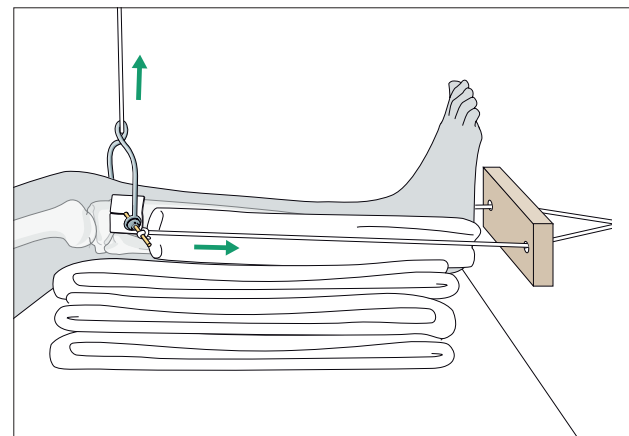


5.4 Traction setup

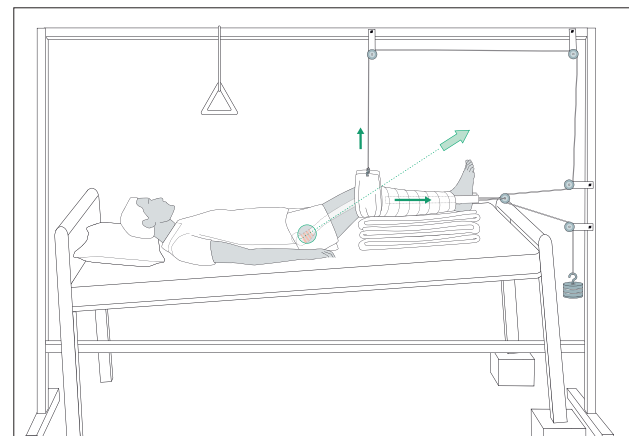
It is important that the stirrup be freely mobile around the traction pin, to prevent rotation of the pin within the bone. Rotating pins loosen quickly and significantly increase the risk of pin track infection.



Application of upward and distal forces to the skeletal traction pin. A rope tied to the traction pin stirrup can apply the upward force. Distal force can then be applied separately via a loop of rope tied to each end of the pin and running distally along the medial and lateral surfaces of the calf. This must be padded to protect the skin, and a spreader (usually wood) distal to the foot is essential to avoid pressure on the malleoli.

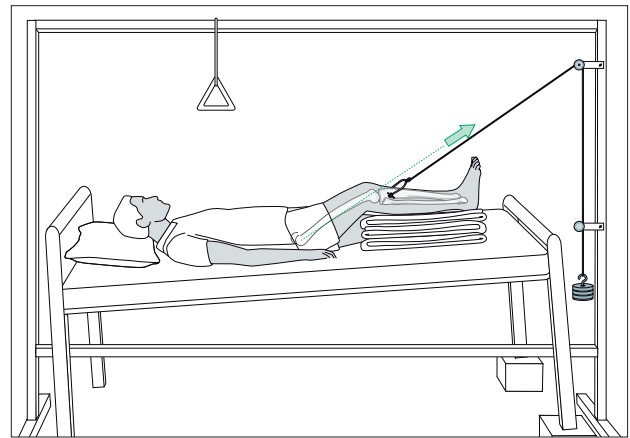


Another alternative is to make a Nissen-type traction loop, as illustrated. These were previously available commercially, but now probably will require local fabrication, if desired.



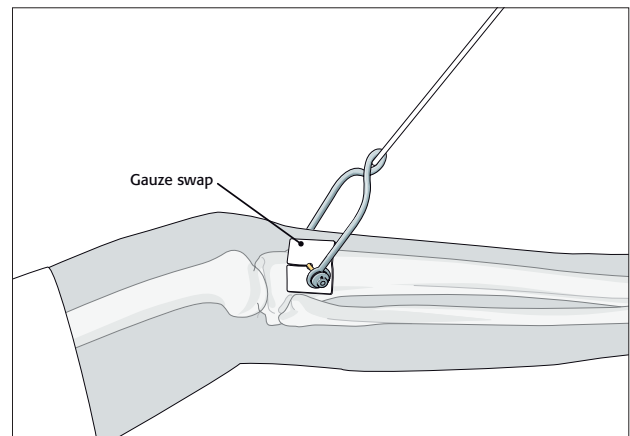


Often the simplest alternative is to use a single rope from the traction pin stirrup, directed overhead and distally through a pulley (and then through a second pulley at the foot of the bed). The position of the first pulley determines the force vector (direction) of the traction, presuming the patient remains in the selected location. Weight and direction of the traction should be adjusted to lift the knee approximately one fist-width off the bed. Pillows under the calf support the lower leg, prevent excessive knee flexion, and keep the heel off the bed, as shown.



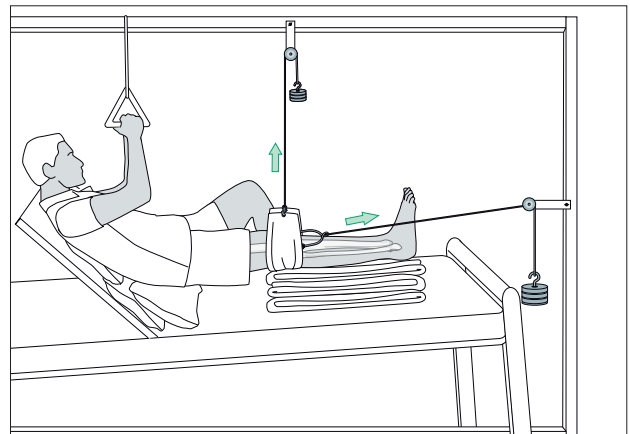
5.5 Pin care

In order to prevent pin track infection, apply a slit gauze swab (sponge) as a dressing around the pin and do not remove the crust that develops around the pin on the skin. The gauze swab should only be changed infrequently.



6 Mobilization in bed

Assisted active mobilization and chest physiotherapy should start from day one. With the aid of a “monkey chain” as shown, the patient can lift himself up and the traction system allows mobilization of the knee.





7 Aftercare

General guidelines

Intertrochanteric fractures usually stabilize within 6-8 weeks and changing to touch weight bearing on crutches should then be considered.

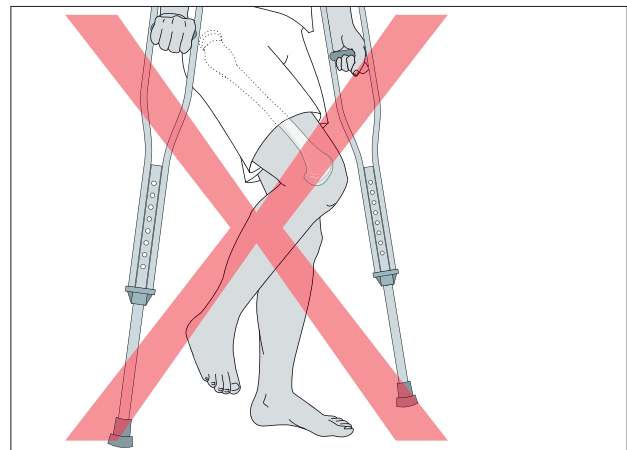
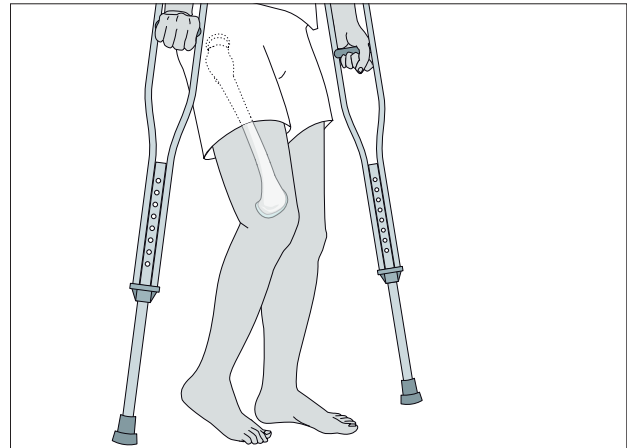
At this stage an x-ray is highly desirable to give further information on healing. Visible bridging callus suggests that progressive weightbearing can begin. If radiography is not available, mobilization in bed can typically be started 6-8 weeks after injury, and progressed as tolerated, encouraging the patient to use walking aids for support, to minimize pain at the fracture site. The ability to bear full weight without pain is a good sign of fracture healing.

Discharge to home care should be delayed until the patient can get in and out of bed independently, and is mobile on crutches.

The patient in homecare should not sit for prolonged periods in a chair, if avoidable, as this will lead to a flexion contracture at the hip joint.

Note: Non-weight bearing involves flexion of the hip which can greatly increase the angular load on the healing fracture. Many surgeons believe that touch weight bearing, which allows the healing femur to be more vertical, is safer at this stage.

From about 10 weeks onwards partial weight bearing should be started and increased to full weight bearing at +/- 12-14 weeks.





3 Femoral fractures

3.11 II Proximal femoral fractures - Nonoperative treatment of 31-B1 fractures

Indication **31-B1 type fractures**

1.2 Preliminary remark

Since B1 fractures are impacted, they are stable. Thus, in some parts of the world they are treated non surgically. The patient is allowed weight bearing and the position of the fragments is checked radiologically.

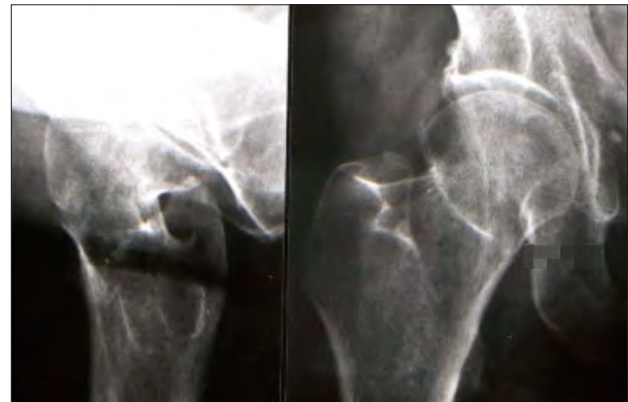About 10% of these fractures will displace. The majority of surgeons consider this risk unacceptable and prefer therefore to fix these fractures with cannulated screws which prevents this complication.

1.2 Treatment guidelines

Mobilization starts as soon as pain is tolerable. Partial weight bearing if possible, full weight bearing if necessary.

8 weeks after injury, full weight bearing can be started. Functional treatment is continued until fracture healing. In case of secondary displacement, treat the fracture like a primarily displaced fracture.

X-ray control should be performed only if pain doesn't subside, or returns.



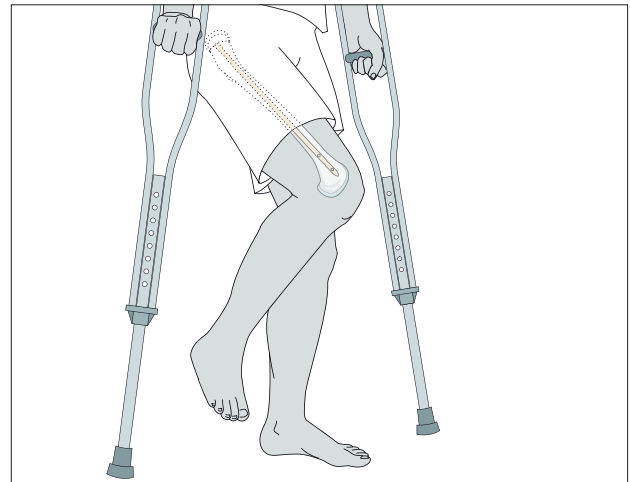
3 Femoral fractures

3.12 I Femoral shaft fractures - Management with minimal resources

Indication **All femoral shaft fractures**

1 General considerations

Femoral shaft fractures are normally treated operatively, using intramedullary nailing. They should only be considered for nonoperative fracture treatment if there are neither facilities, nor skills, for surgical treatment.

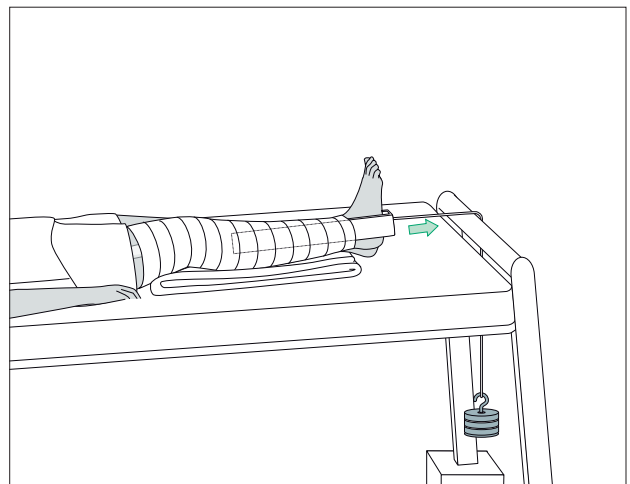


Nonoperative treatment means that the patient will be in a form of traction for at least 6-8 weeks, often 10-12 weeks.

The initial treatment is usually skin traction, later converted to skeletal traction.

Disadvantages of prolonged skin traction are:

- Loosening
- Constriction
- Friction
- Allergy



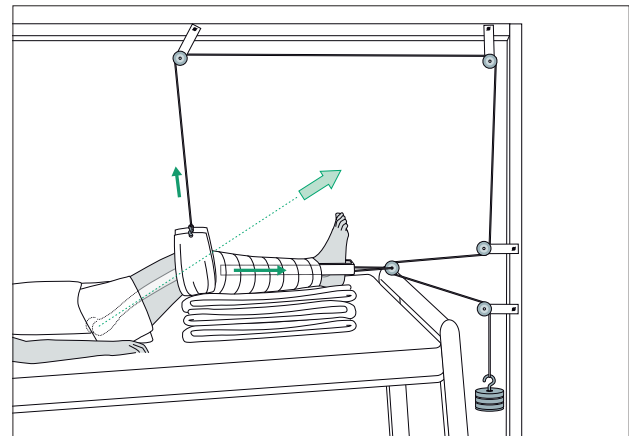


If skin traction is likely to be used for more than 24 hours, greater patient comfort and better control of the femoral fracture can be achieved by using Hamilton-Russell skin traction.

A padded sling is placed behind the slightly flexed knee and skin traction applied to the lower leg. The traction cord and pulley system is as illustrated.

The principle of the parallelogram of forces determines that the upward pull of the sling and the longitudinal pull of the skin traction create a resolution of force in the line of the femur, as illustrated.

This configuration of traction also allows control of rotation, by side-to-side adjustment of the pulley above the knee.

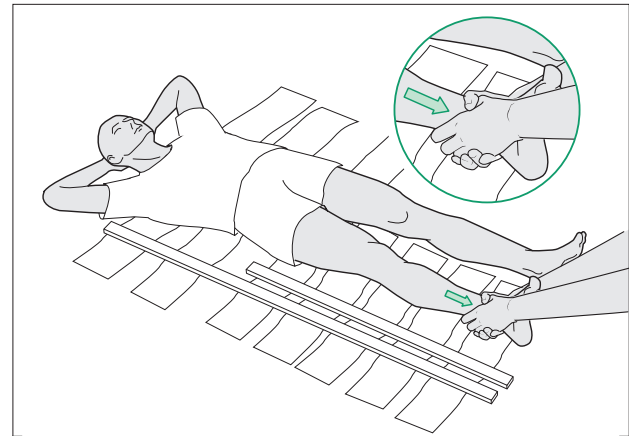


2 First aid

The ABC of primary care for the injured always takes precedence over the fracture treatment. Once the safety of the patient is established, we attend to the fracture.

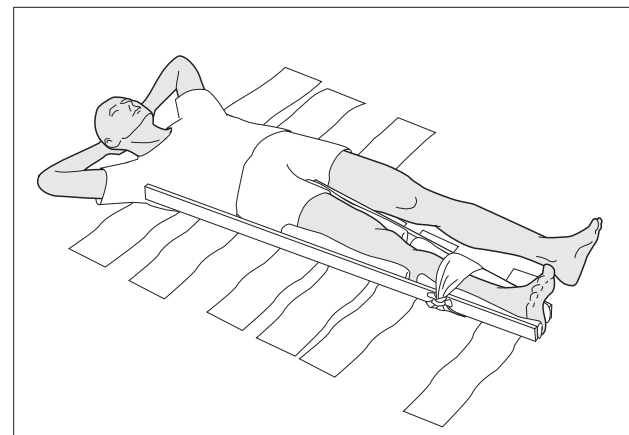
It is important in treating a femoral shaft fracture to splint the whole leg as soon as possible, and certainly before transport of the patient.

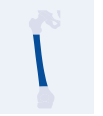For that purpose you need two firm boards or sticks along the leg, suitably padded, one on the inner aspect of the leg and one along the leg and the body on the outer aspect.



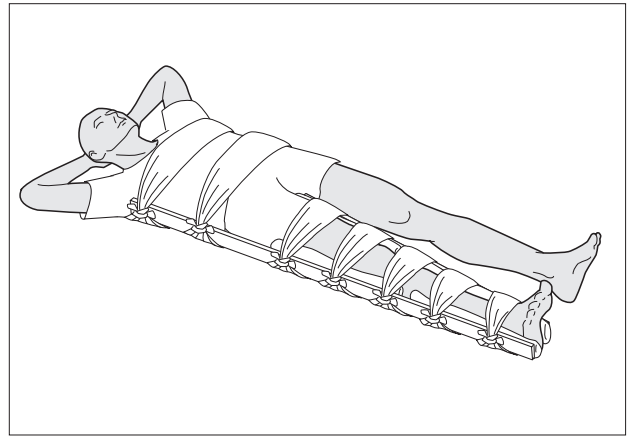
Any soft material such as clothing, blankets, etc. can be used as emergency padding.

The splints should then be kept in place by bandages around both splints and ...

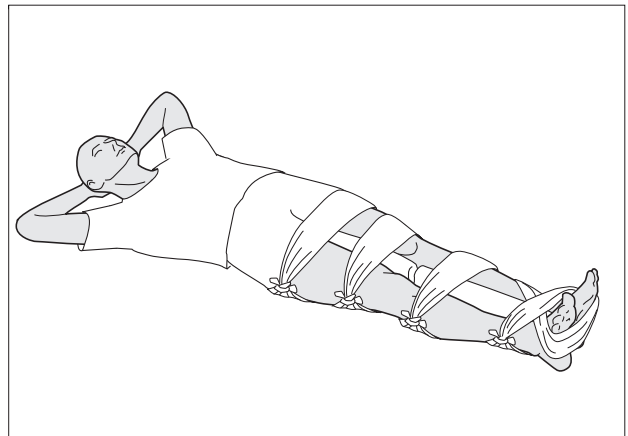




... the leg as well as the body.



If no boards are available, some stabilization can be achieved by splinting the fractured leg to the uninjured leg, with padding in between.

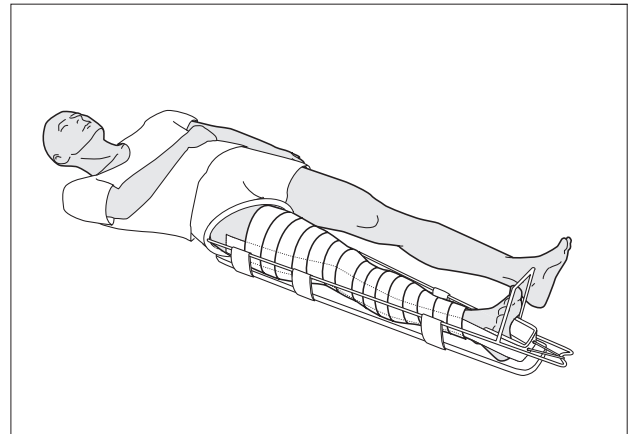


Many ambulance services these days work with technically advanced light-weight splints.





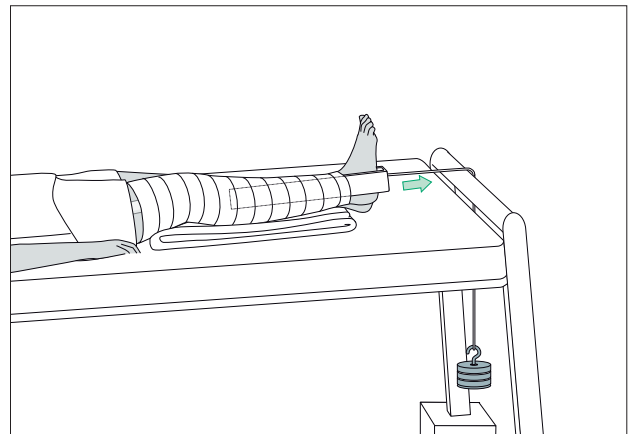
Another way of splinting is the use of skin traction in combination with a Thomas splint. The Thomas splint affords excellent immobilization for transporting the patient. Unfortunately nowadays, the availability of a Thomas splint is somewhat limited. Great care must be taken to avoid excessive pressure of the ring of the splint against the perineum, using suitable padding as necessary.



3 Skin traction

In the event that there is no Thomas splint available, skin traction over the end of the bed with 7 kg will be the initial treatment of a femoral fracture.

Note: With any longitudinal traction, the foot of the bed must be raised, tilting the bed, to avoid the traction weight pulling the patient down the bed. With the tilted bed the weight of the patient acts as countertraction.



This photograph shows a commercially available skin traction kit.



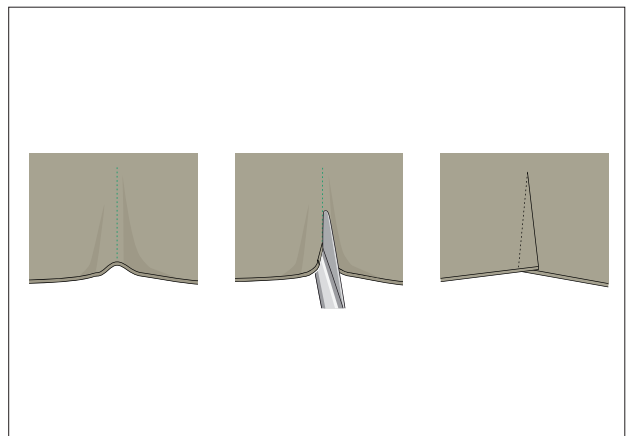


Prior to the application of the adhesive traction strip, the skin is painted with friar's balsam. The strip is then applied below the level of the fracture on the medial and lateral aspects of the leg as shown, carefully avoiding any creases.

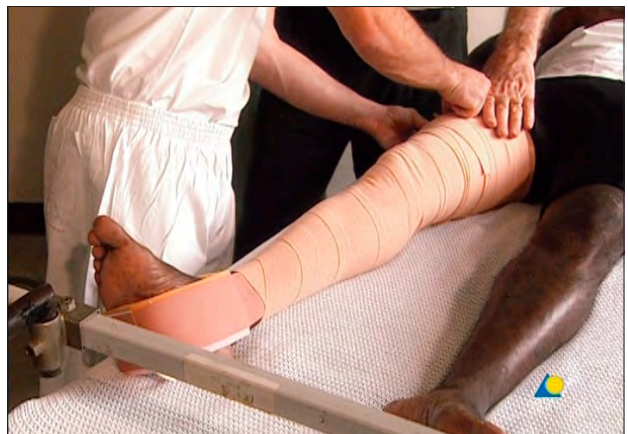

To prevent the development of blisters, the skin traction needs to be applied without folds or creases in the adhesive material and the covering bandage should be non-elastic.

Should a crease be inevitable, due to the contour of the limb, the creased area should be lifted, partially slit transversally and the edges overlapped.



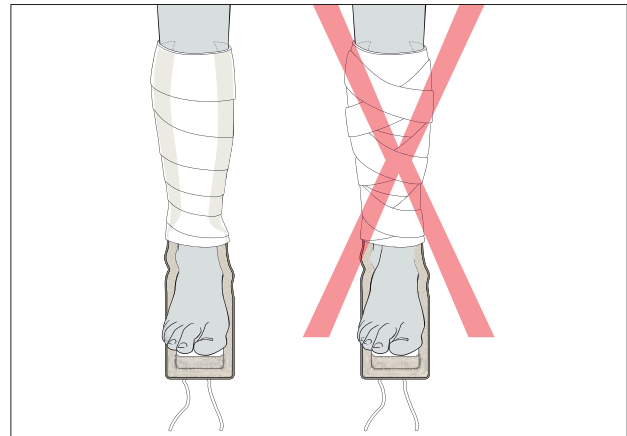
Once the adhesive strip is satisfactorily in place, ensuring that the padded lower section overlies the malleoli, a spiral inelastic bandage is carefully wrapped around the limb from just above the malleoli to the top of the strip.





Apply the overlying bandages spirally overlapping by half.

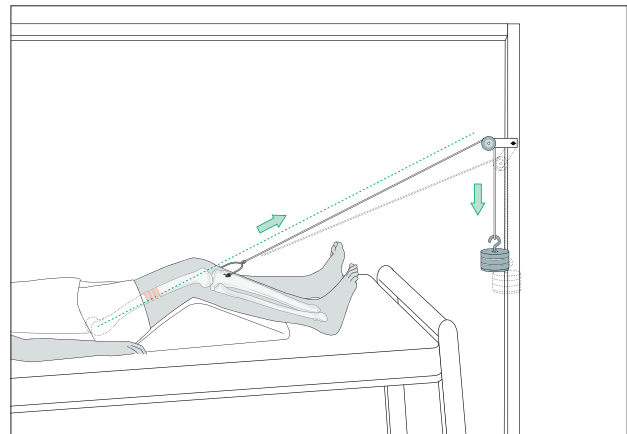
The traction strip should be applied to the level of the fracture only, but not above.



4 Skeletal traction

4.1 Skeletal traction via tibial pin (Perkin's traction)

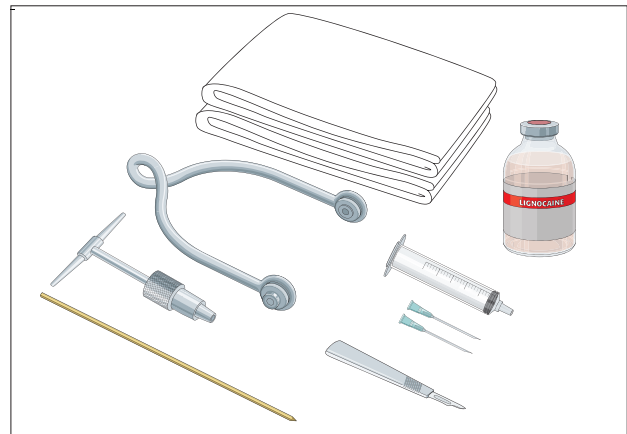
As soon as the decision is made that traction will be the definitive treatment, conversion to skeletal traction should be done.



4.2 Preparation

Pack with:

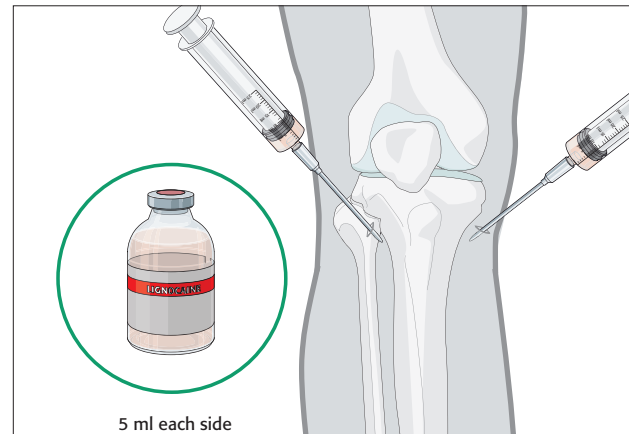
- Sterile towels
- Disinfectant
- Syringe
- Needles
- Local anaesthetic
- Scalpel with pointed blade
- Sharp pointed Steinmann pin, or Denham pin
- Jacobs chuck with T-handle
- Stirrup





4.3 Anesthesia

After painting the skin with antiseptic and draping with sterile towels, inject a bolus of local anaesthesia (5 ml of 2% lignocaine) on each side of the tibial tuberosity, into the lateral skin at the proposed site of pin insertion and medially at the anticipated exit point, infiltrating down to the periosteum.



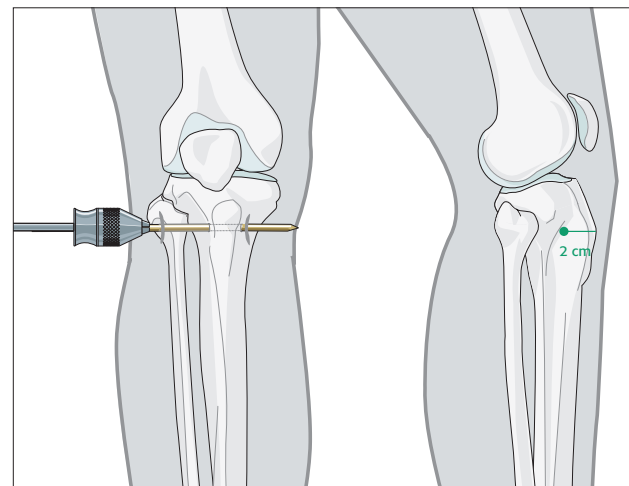
4.4 Pin insertion

At the entry point, a stab incision is made through the skin with a pointed scalpel.

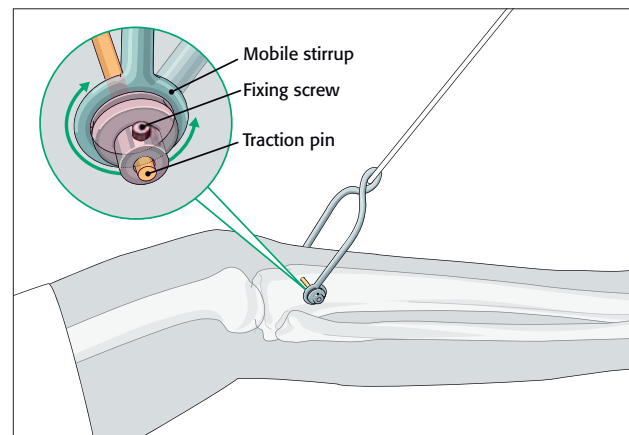
A Steinmann, or preferably a Denham pin, mounted in the T-handle, is inserted manually at a point about 2 cm dorsal to the tibial tuberosity.

As the pin is felt to penetrate the far cortex, check that the exit will coincide with the area of local anaesthetic infiltration. If not, inject additional local anaesthetic. Once the point of the pin clearly declares its exit site, make a small stab incision in the overlying skin.

Once the pin is in place, ensure that there is no tension on the skin at the entry and exit points. If there is, then a small relieving incision may be necessary.



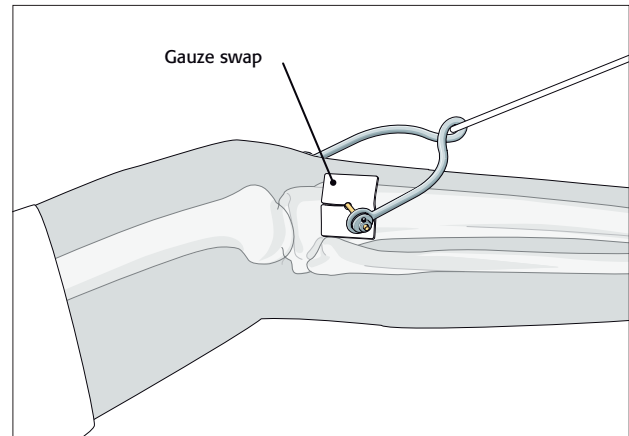
It is important that the stirrup be freely mobile around the traction pin, to prevent rotation of the pin within the bone. Rotating pins loosen quickly and significantly increase the risk of pin track infection.





4.5 Pin care

In order to prevent pin track infection, apply a slit gauze swab around the pin and do not remove the crust that develops around the pin on the skin. The gauze swab should only be changed infrequently.



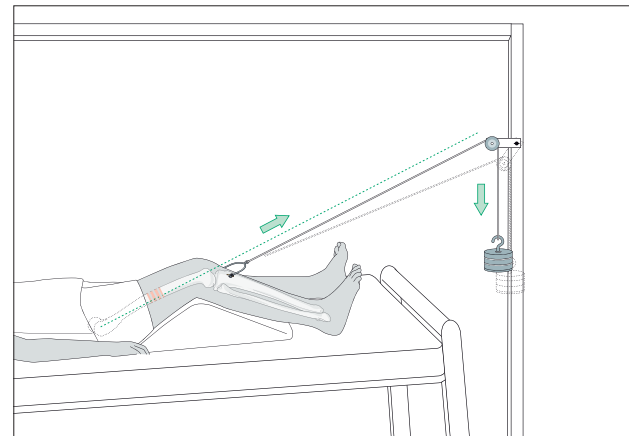
4.6 Reduction

The pull on the femur (weight at the end of the traction) should be enough to correct length and to reduce the fracture.

For maintenance traction 10% of the patient's body weight is usually sufficient.

The pull should always be in line with the femur. For that purpose, the height of the pulley on the Balkan beam must be adjustable.

The thigh needs to be supported on a firm triangular foam wedge, or by folded pillows, in order to prevent posterior sag at the fracture site.

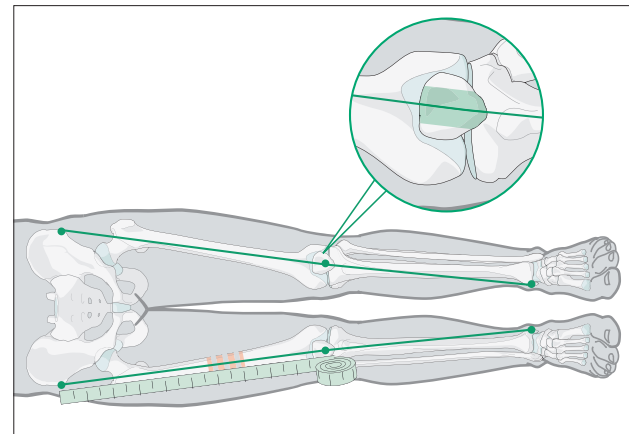


4.7 Control of length and rotation

Length and rotation need to be checked daily.

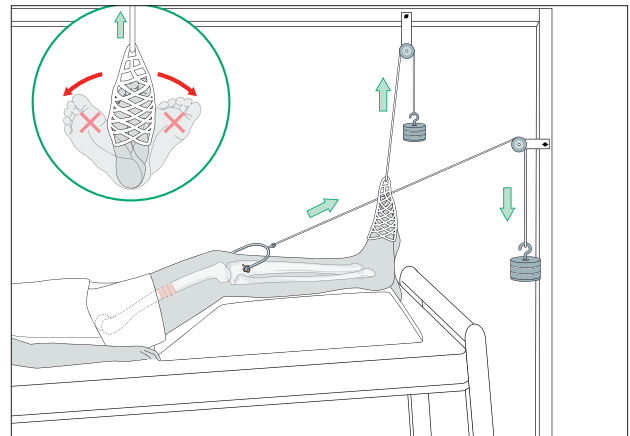
Length is measured by comparison to the uninjured leg. Both legs are brought into comparable positions and the distances from the anterior superior iliac spines, over the knee, to the medial malleoli, are measured and compared.

Adjustment, if required, is done by increasing, or decreasing, the traction weight. Control x-rays need to be taken weekly, if possible, for at least the first 4 weeks. If the medial/lateral angulation at the fracture site is anatomical, this line will pass over the central third of the patella.



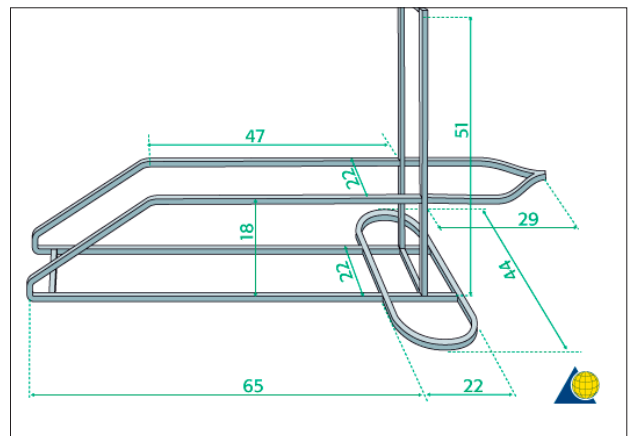


Rotation and maintenance of dorsiflexion in the ankle can be achieved by applying an adhesive sock to the forefoot with a cord over a pulley on the Balkan beam. This pulley should be adjustable from side to side to control rotation.



4.8 Distal shaft fractures

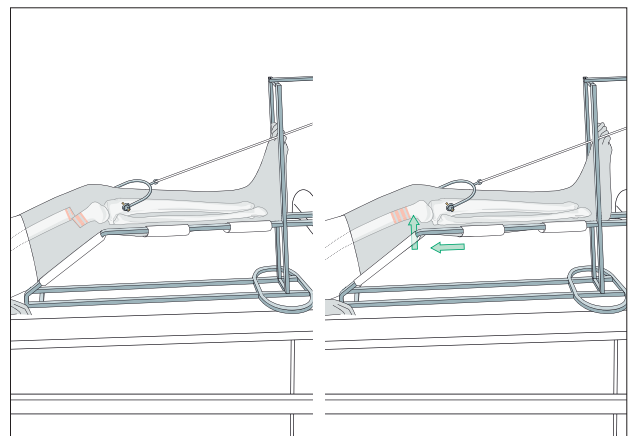
Fractures in the distal third of the femur can be controlled more easily by using a Braun frame. This illustration shows the construction of a Braun-type frame, using metal bars (5 mm x 20 mm).



In order to prevent posterior displacement of the distal fragment, the angle of the padded frame is pushed proximally to support the distal fragment, with appropriate padding.

As soon as the resolution of the pain allows, exercises should be started.

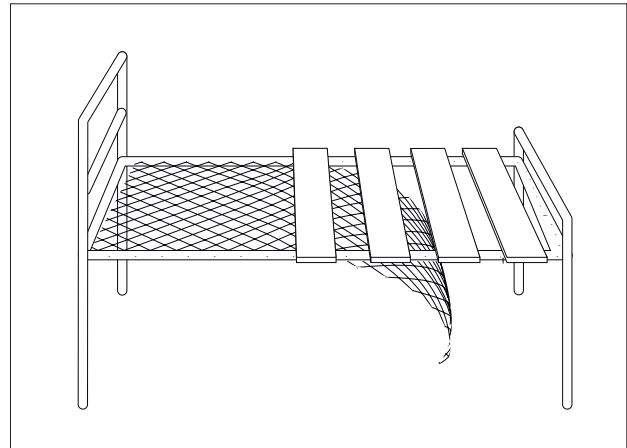
Control x-rays for fracture position need to be taken weekly, if possible, for the first 4 weeks. Thereafter X-rays are only necessary at 4-week intervals to monitor bone healing.



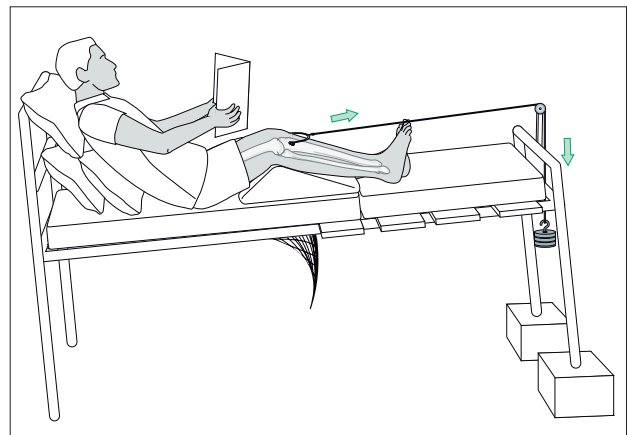


5 Mobilization

Modification of the bed, as illustrated, will allow early mobilization of the knee as soon as resolution of the pain allows.



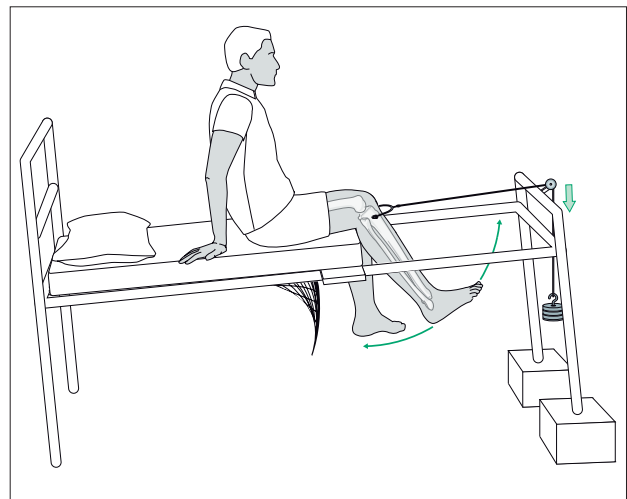
A split mattress is used so that the lower half of the bed base can be removed.



With the lower half of the bed base removed and the femoral shaft fully supported by the remaining mattress, the patient starts active knee mobilization after the acute phase (7-10 days). This comprises active extension exercises and active gravity-assisted flexion exercises, under the supervision of a physical therapist.

Once the patient can flex the knee from 0 to 90° painlessly and freely, and can actively straight-leg raise with the weights relieved, non-weight bearing mobilization on two crutches can be considered, sometimes as early as 6 weeks after the injury.

Note: Non-weight bearing involves flexion of the hip which can theoretically increase the tendency to angulate the healing fracture. Some surgeons believe that touch weight bearing, which allows the healing femur to be more vertical, is safer at this stage.



From 8 weeks onwards, progressive partial weight bearing should be started and increased to full weight bearing at +/- 12 weeks.



3 Femoral fractures

3.12 II Femoral shaft fractures - Temporary Thomas splint

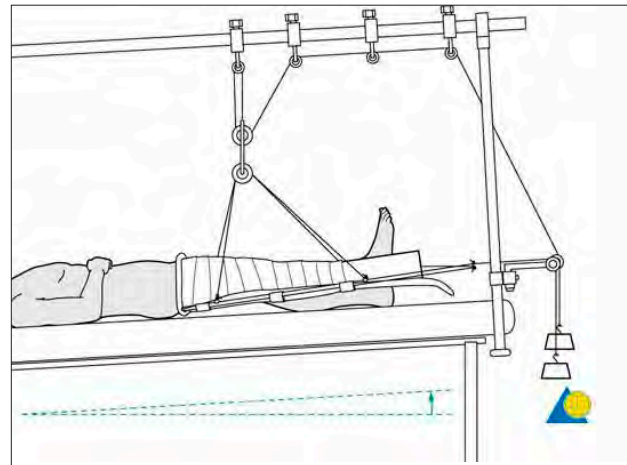
Indication **All femoral shaft fractures**

1 General considerations

1.1 Thomas' splint

Temporary stabilization of femoral shaft fractures can be achieved using the Thomas's splint apparatus. It can also be used for transportation of patients. This can provide adequate fracture stability and pain relief until definitive stabilization is carried out.

If this method of treatment is chosen the appropriate size of the Thomas's splint has to be selected.



1.2 Prolonged temporary treatment

If prolonged temporary treatment is envisaged, consider other methods of treatment (external fixator) in order to avoid soft-tissue complications (pressure sores, skin blistering under adhesive strip.)

1.3 Medical treatment

During immobilization, pharmaceutical thromboembolic prophylaxis is desirable. Non-steroidal anti-inflammatory medication should be avoided due to reported adverse effects on fracture healing.

1.4 Thomas's splint with children

In older children it can be used as a definitive method of treatment (for a period of four to six weeks). In younger children, the presence of the ring can displace a short proximal fragment.

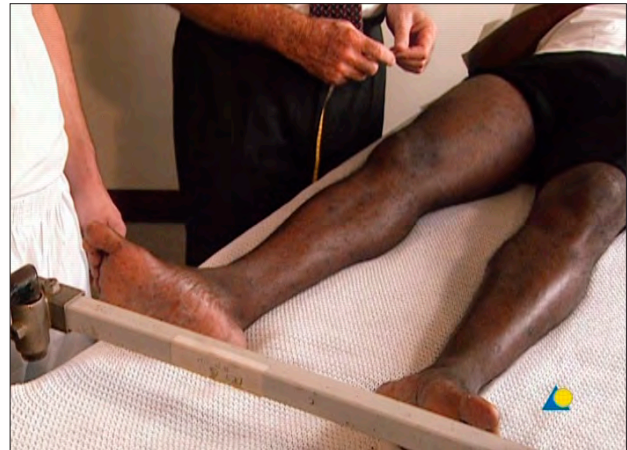1.5 Definitive treatment

In cases where there are contraindications to surgery and/or socio-economic issues do not permit fracture fixation, Thomas's splint traction can be used as the definitive method of treatment.



2 Positioning

The patient should lie down on his or her back.

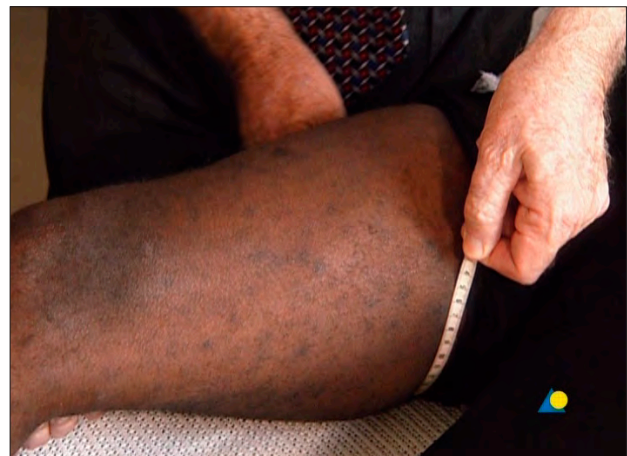

3 Size and length of the Thomas's splint

3.1 Circumference

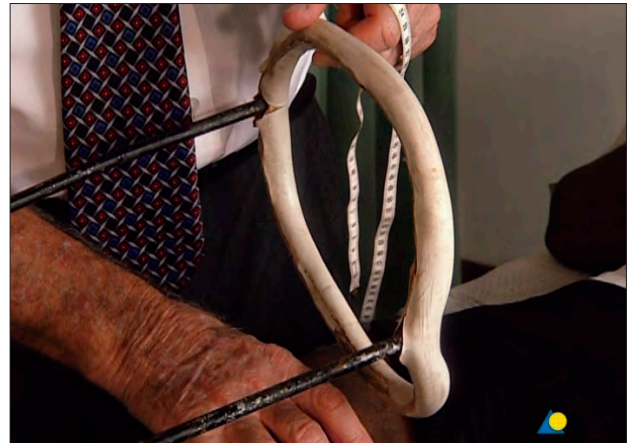To begin, the circumference of the thigh is measured to establish the size of the inner circumference of the ring of the Thomas's splint.

Here the circumference of the thigh is measured as sixty centimeters.



When choosing the Thomas's splint to be used, four centimeters should be added to the measurement to allow for swelling.

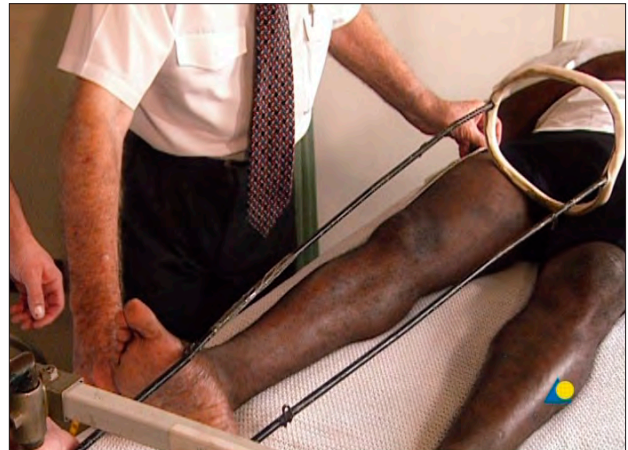In this example, a splint with an inner circumference of sixty-four centimeters is selected.





3.2 Length

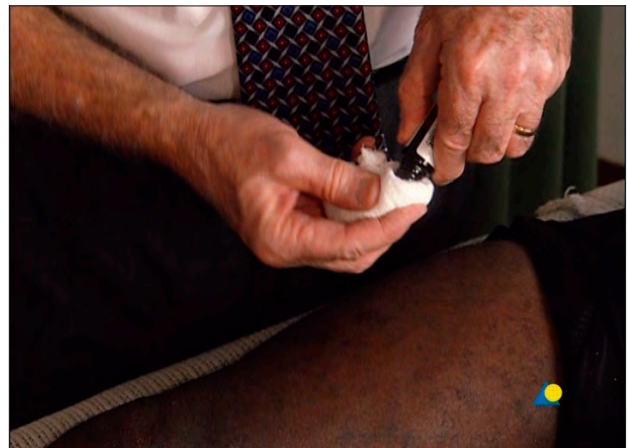The length of the patient's leg is measured, and twenty centimeters are added to establish the length of the Thomas's splint.



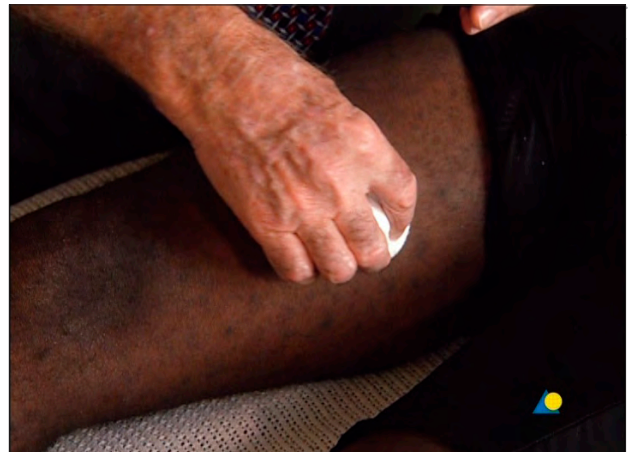4 Preparation

4.1 Tinc Benz Co

Tinc Benz Co is used on the skin of the leg to improve the adhesion of the adhesive traction strip.



On the medial side, beginning at the groin, Tinc benz co is applied down to the ankle.

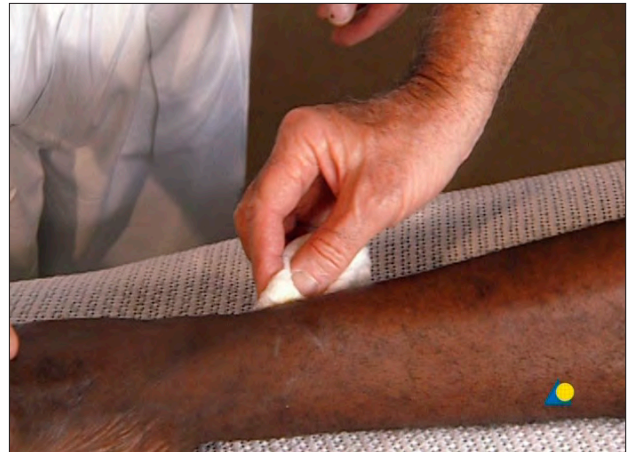



3 Femoral fractures

3.12 II Femoral shaft fractures - Temporary Thomas splint

The adhesive also is spread on the lateral side from the greater trochanter down to the ankle.

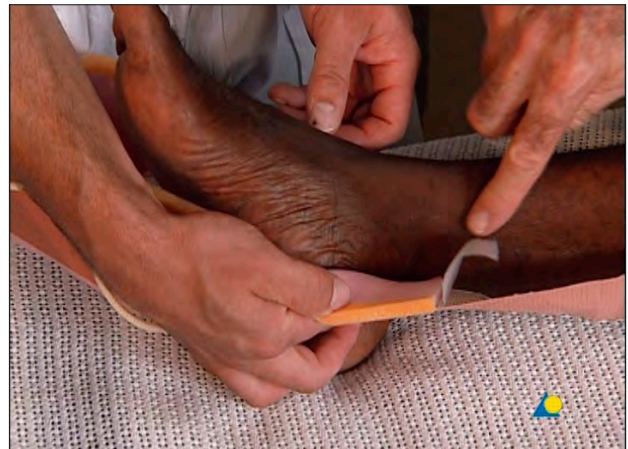

4.2 Application of adhesive traction strip

The adhesive traction assembly will now be applied. It is important that the material does not stretch lengthwise.

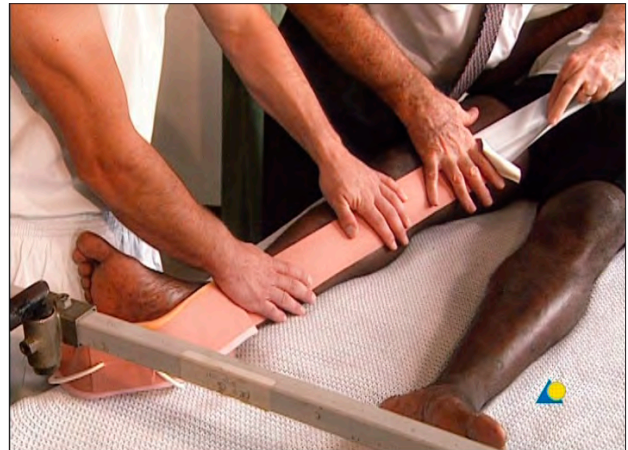

The lower part of the strip is padded, to prevent pressure sores forming over the medial and lateral malleoli.

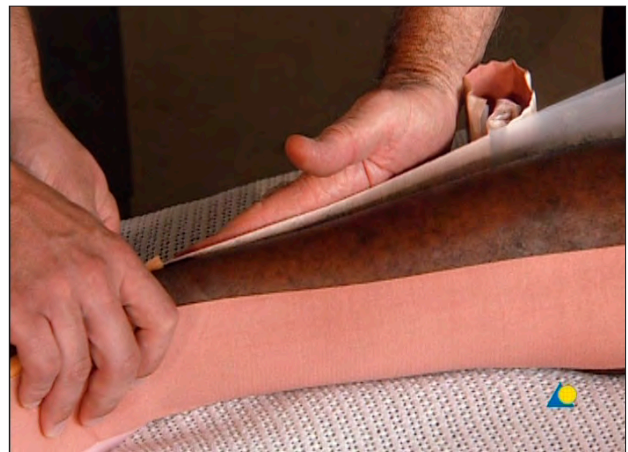




The backing is removed, and the adhesive strip is applied on the medial side, reaching proximally up to the groin.



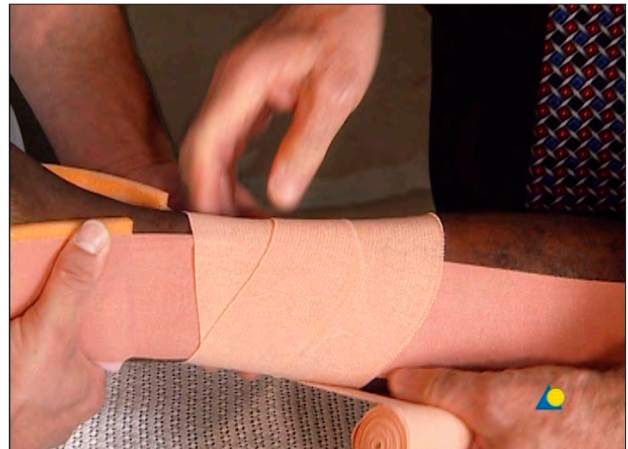
On the lateral side, the backing is removed, and the adhesive strip is applied as far as the greater trochanter. Care is taken to verify that there are no wrinkles in the strip, as they can lead to pressure sores.



4.3 Bandage

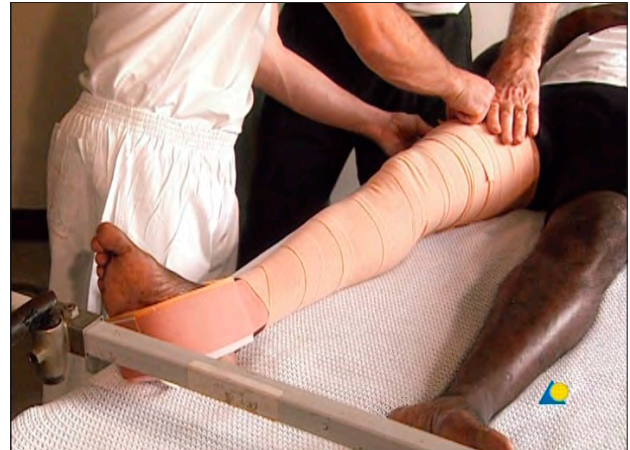Starting four finger-breadths above the ankle joint, a circular crêpe bandage is wound proximally, with moderate tension, towards the groin.

Again, it is crucial that there be no wrinkles in the bandage.





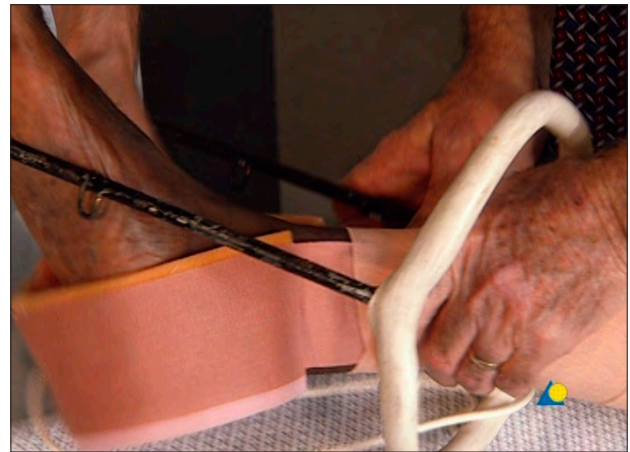A second, proximal bandage ensures that the adhesive strip is secured as far as the groin.



5 Application of Thomas's splint

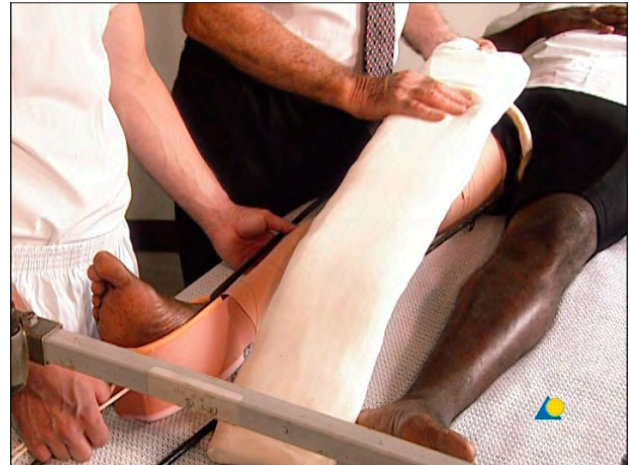5.1 Passing the splint over the leg

The Thomas's splint is applied by passing it over the leg, upwards, to the groin.



5.2 Limb support

Either the Thomas's splint is fitted with slings to support the limb prior to passing it over the leg, or a Kramer wire, which must be very well-padded, in order to prevent pressure sores, is placed under the patient's leg. Proximally the support extends to the ring of the splint.

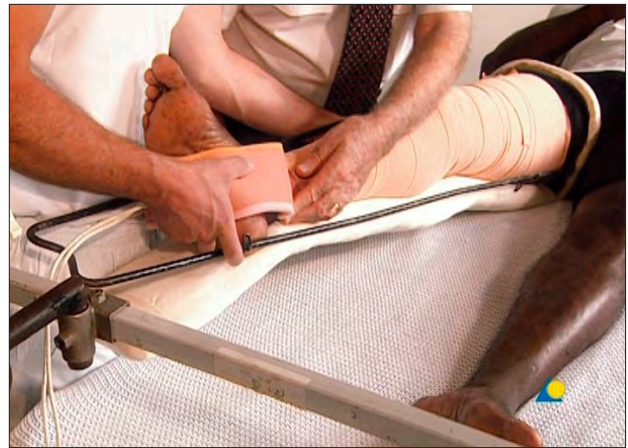



If a Kramer wire support is used, it should be bent slightly under the patient's knee.

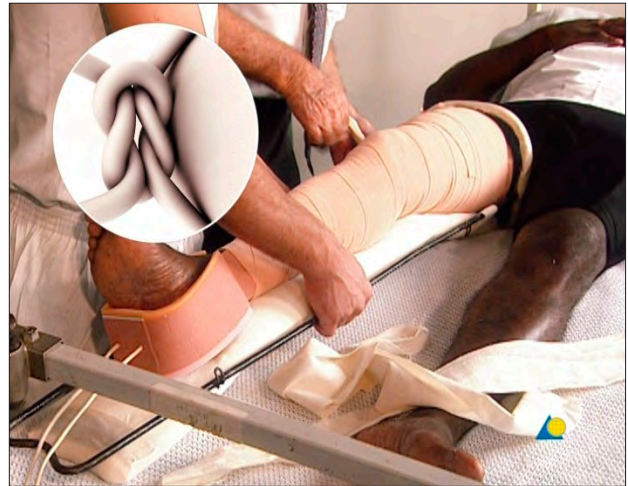

The Kramer wire must be further bent to the angle of the heel, in order to prevent pressure sores under the heel.



5.3 Secure leg and Thomas's splint
Flannelette bandage slings are used to support the leg on the Thomas's splint, whilst also providing support to the Kramer wire.

To complete the bandaging proximally it is passed over the ring of the Thomas's splint, under the Kramer wire, around the Thomas's splint, back under the Kramer wire, and is secured on the lateral side with a reef knot.





3 Femoral fractures

3.12 II Femoral shaft fractures - Temporary Thomas splint

The second and third flannelette slings are applied in the same manner.
The second bandage is located behind the knee.

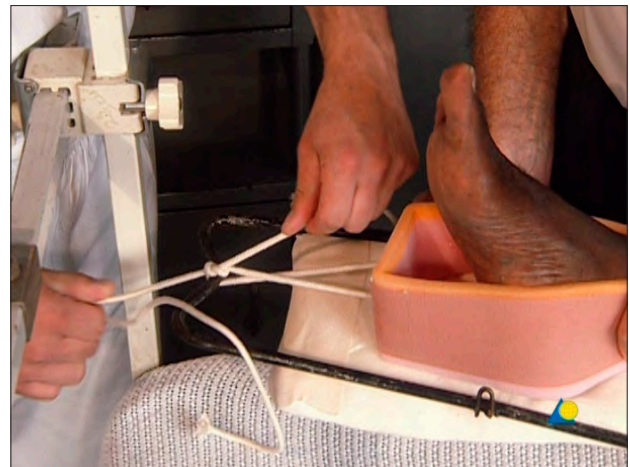

The third bandage is located just above the ankle, posterior to the Achilles tendon.



5.4 Traction

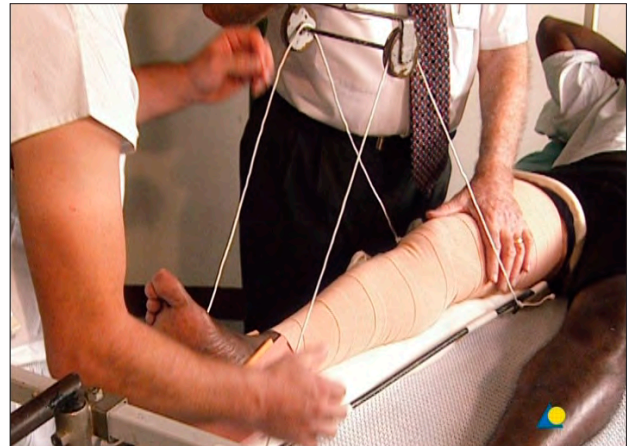Traction is applied to the fractured femur by tightly tying the cord at the end of the traction strip assembly to the distal end of the Thomas's splint.



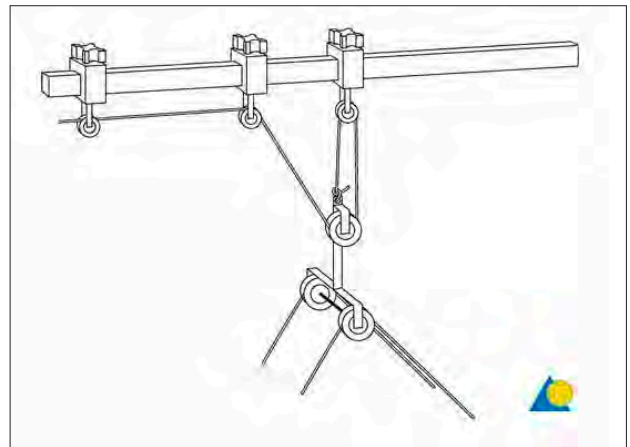


6 T-pulley installation


The T-pulley does not exert traction, but it suspends the patient's leg dynamically to allow the patient to use a bed pan, to be bathed, etc.



The T-pulley is fixed in place. It is suspended by tying the cord securely to the top. The cord is passed over a proximal pulley of the traction frame, downwards and under the top T-pulley, then it goes upwards, over a second more proximal frame pulley.




The cord is passed distally, over the remaining frame pulleys ...






... and sufficient weights are attached to suspend the patient's leg.



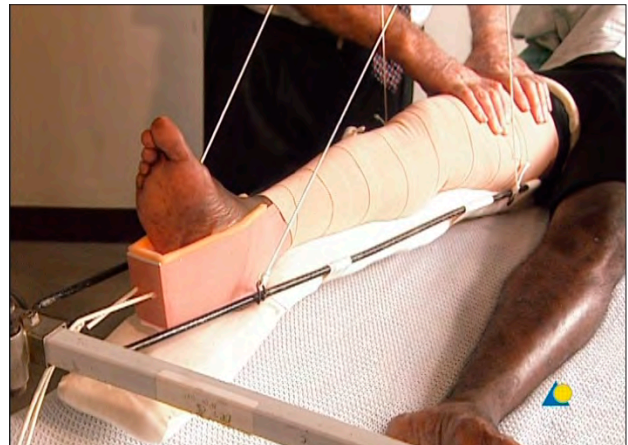7 Re-tightening of splint

Additional traction may be applied by re-tightening and knotting the traction cord at the distal end of the Thomas's splint.



8 Reduction

The hands may be used to reduce the femoral fracture.







9 Final splint adjustments

9.1 Counter traction

It should be noted that tightening the distal end of the traction cord forces the ring of the Thomas's splint proximally, possibly risking pressure sores at the groin. To prevent this proximal displacement, counter traction with weights is applied to the end of the Thomas's splint, as shown here.



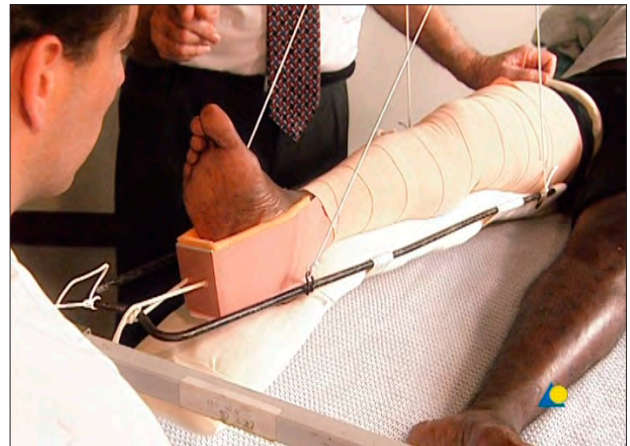Eight kilograms are generally sufficient for an adult patient, with less weight used for a younger person.



9.2 Elevation of foot of the bed

The weights at the distal end of the splint will cause the patient to tend to slip gradually towards the foot of the bed.

To prevent this, the foot of the bed is elevated, so that the weight of the patient balances the weight at the distal end.



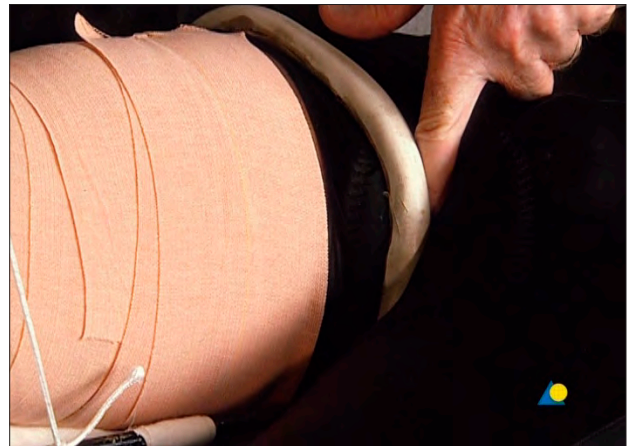


3 Femoral fractures

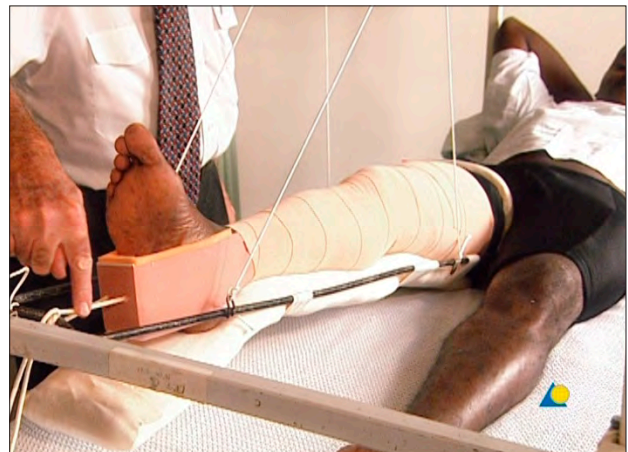
3.12 II Femoral shaft fractures - Temporary Thomas splint

9.3 Pressure points

A finger is passed around between the ring of the Thomas's splint and the groin to verify that there are no pressure points.

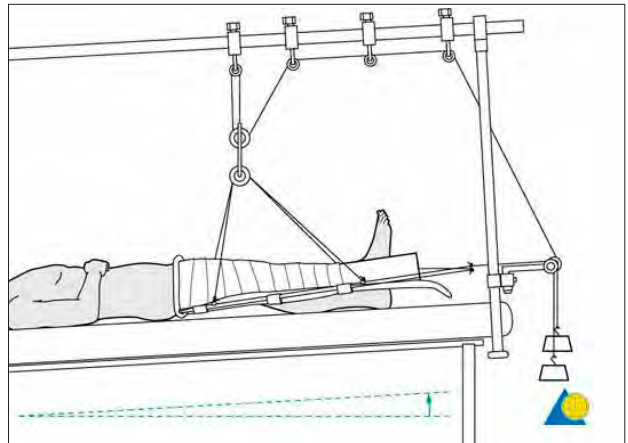


If pressure points are found, then the tension in the traction cord tied to the Thomas's splint should be relaxed a little.



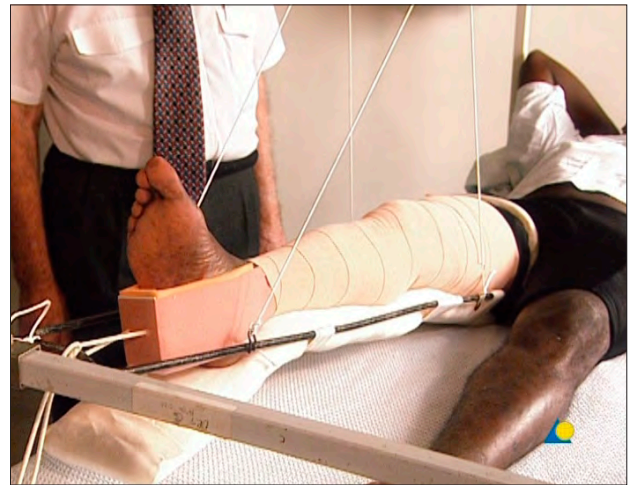10 Completed Thomas's splint

The application of the Thomas's splint ...





... is now complete.



11 Aftertreatment for a definitive treatment by Thomas's splint

When traction on a Thomas's splint is used as a definitive treatment, a minimal 12 week period of immobilization is desirable. The fracture is usually judged to be healed when the patient can actively straight leg raise,

off traction. Thromboprophylaxis should be administered according to the protocol of the clinic.

After the immobilization, depending on the clinical and radiographic evidence of fracture healing, the patient can be mobilized with toe-touch weight bearing, gradually progressing to full weight bearing.

3 Femoral fractures

3.13 I Distal femoral and patellar fractures - Treatment with a long leg cast

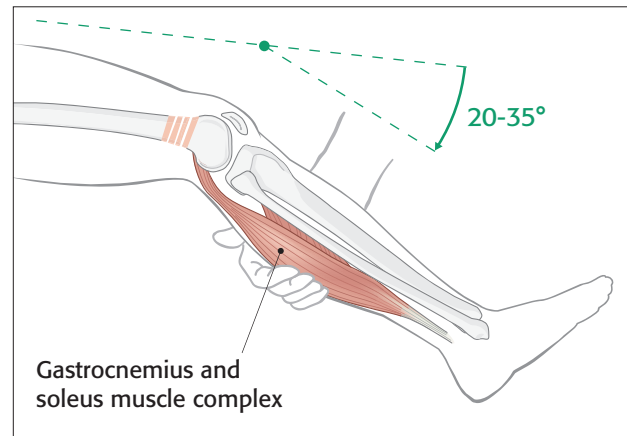
Indication **33-A and 33-B, 34-A and 34-B type fractures**

1 Principles

Common deformity

It is recognized that perfect realignment of a displaced distal femoral fracture will be impossible with a long leg cylinder splint. However, it helps to bring the fracture out to length and to correct some of the common hyperextension deformity.

Note: If the splint is not able to control the length adequately, this would be an indication for tibial skeletal traction, when a spanning external fixator could not be made available for provisional stabilization.



The surgeon applying the long leg splint must remember that the common deformity of a supracondylar femoral fracture (A- or C-type fractures) is shortening and hyperextension of the distal fragment. In order to counteract the hyperextension, either a bolster can be placed under the supracondylar region, or preferably

the knee can be sufficiently flexed by bringing the leg off the end or side of the table.

In order to maintain the length of the fracture in the long leg splint care must be taken to provide good supracondylar molding.

2 Preparation

2.1 Material

To apply the long leg circular cast, the following materials are needed:

- A stockinette, or tubular gauze bandage
- Scissors
- Cotton wool, or dedicated under-cast padding
- Plaster-of-Paris bandages, which come in rolls of varying widths

- Plaster slabs, generally five layers thick, and available in differing widths
- Water, or another wetting agent

The water should be tepid, or lukewarm, with an ideal temperature between 22° and 25° C.

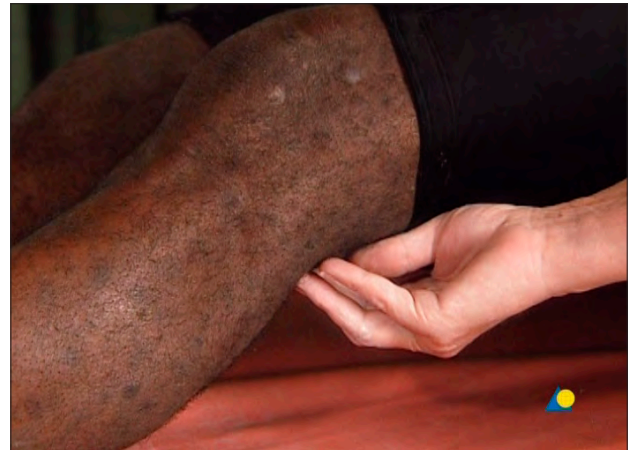It should be noted that colder water, or a bandage that is wetter, will allow for an increased working time, while warmer water, or a bandage that is drier, reduces the working time.

2.2 Patient positioning

The patient should be lying supine, with the ankle over the edge of the table. The foot should be plantigrade.

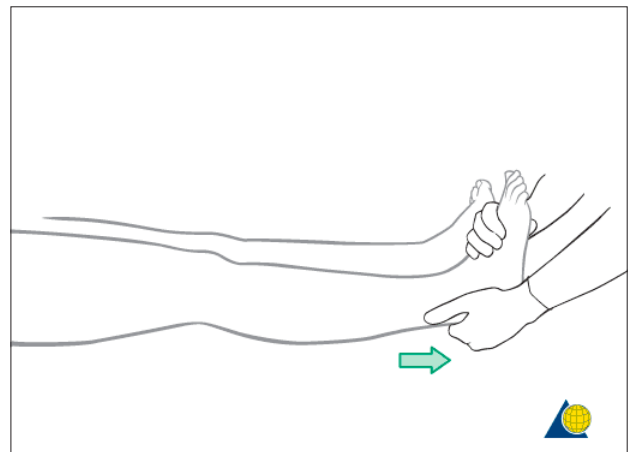
The patient's knee should be flexed to approximately 20-35°, which will relax the gastrocnemius muscle. This will reduce the hyperextension.

The buttock on the side of the injury should be elevated from the table with a bolster, if possible.



3 Reduction

The long leg cast is generally applied several weeks after the fracture has occurred. Nonetheless, the surgeon should be aware of the tendency of the fracture to shorten and to fall into hyperextension. Manual traction, as depicted, can counteract the tendency for shortening, as previously described. A bolster placed beneath the supracondylar region will counteract hyperextension deformity.



4 Padding

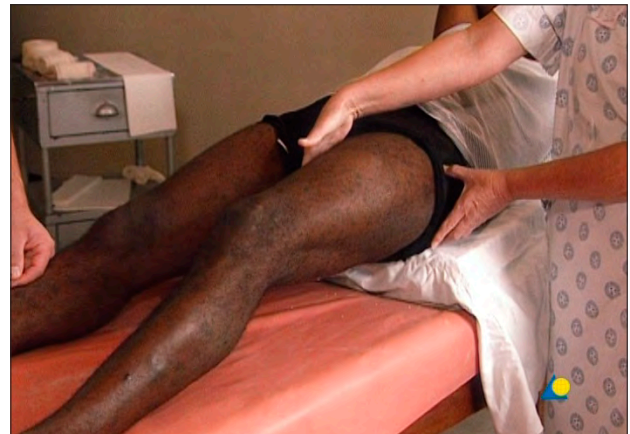4.1 Leg support

After reduction, an assistant supports the leg, and checks to ensure that there is no rotation of the fracture, by verifying that the second toe, patella and superior iliac spine remain in line.

The distal edge of the cast will be located at the level of the metatarsal heads, while the toes should remain free.

The proximal edge lies just below the greater trochanter on the lateral side, and just below the groin on the medial side.

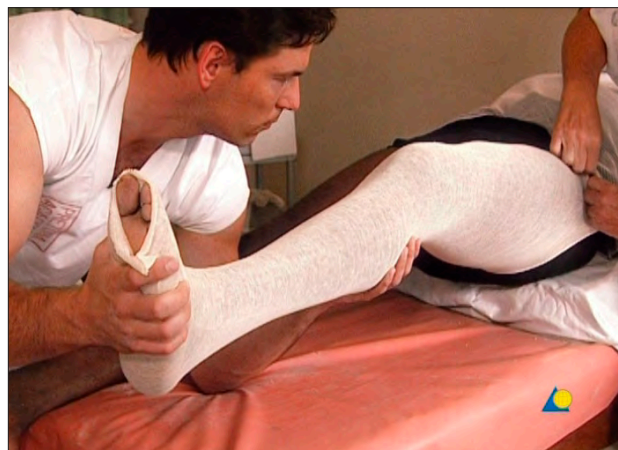Take care to avoid pressure over the fibular head and neck area, to prevent pressure on the common peroneal nerve that could cause neurapraxia, or nerve damage.





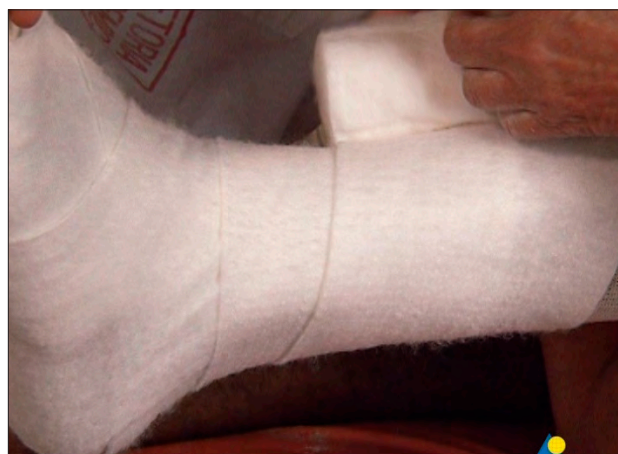4.2 Stockinette application

Apply a stockinette and cut it slightly longer than the final cast will be.



4.3 Cotton wool padding

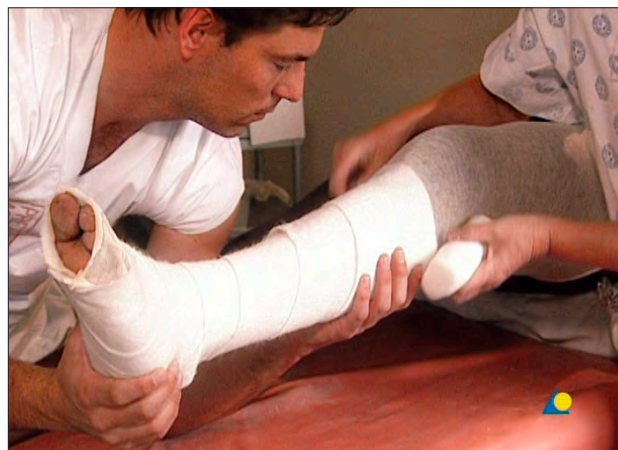Starting at the distal border, gently wind on the cast padding, once around the foot and then around the ankle several times in a figure-of-eight. Make sure that the edge does not cut into the 90° bend of the ankle.



Wind the cast padding towards the knee, with an overlap of 50%.

The overlap creates a double layer of padding, which is sufficient in most cases.

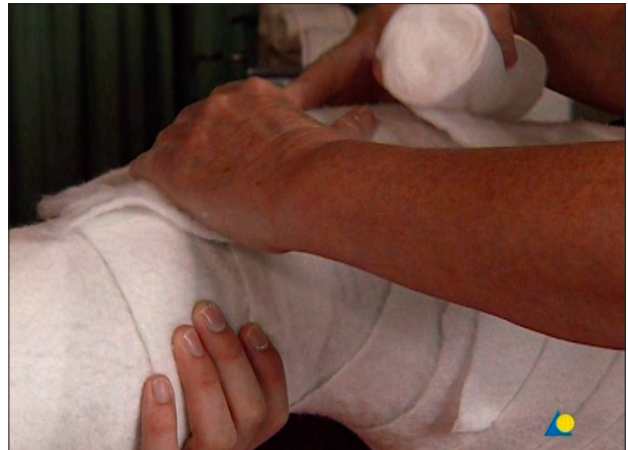The cotton wool extends slightly beyond the planned length of the cast, so that when the end of the stockinette is folded over, the end of the cast will be padded.



4.4 Additional padding

Apply additional cast padding over the patella, the malleoli and over the heel, to protect the pressure points against pressure sores.

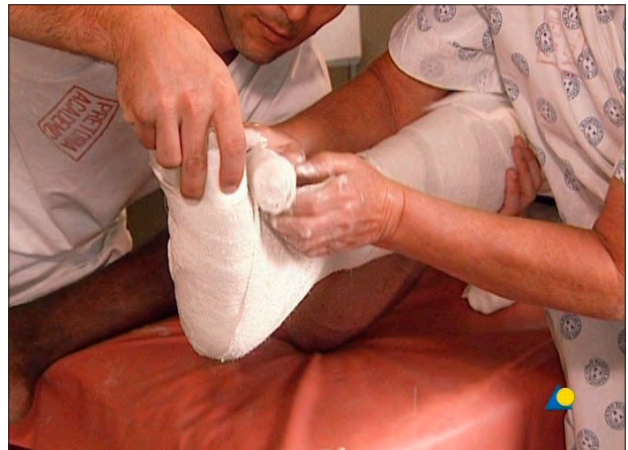It should be kept in mind that, when more padding is applied, there will be less support to the injury site.



5 Plaster application

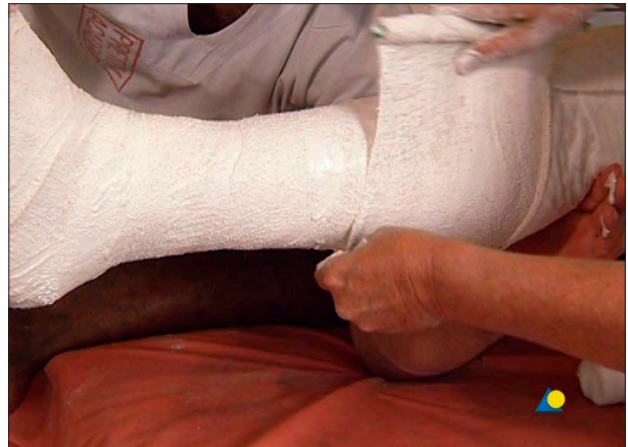5.1 Plaster bandage

Dip the plaster bandage into the water and remove the excess moisture by gently squeezing the bandage. Starting with the bottom of the foot, wrap the plaster bandage around the ankle in a figure-of-eight.



Pass the bandage over the heel and then towards the knee with a 50% overlap, in the same manner as the cotton wool.

In this case a 200 mm wide plaster bandage is used. A 150 mm wide bandage may also be used, however, it will take longer to apply.



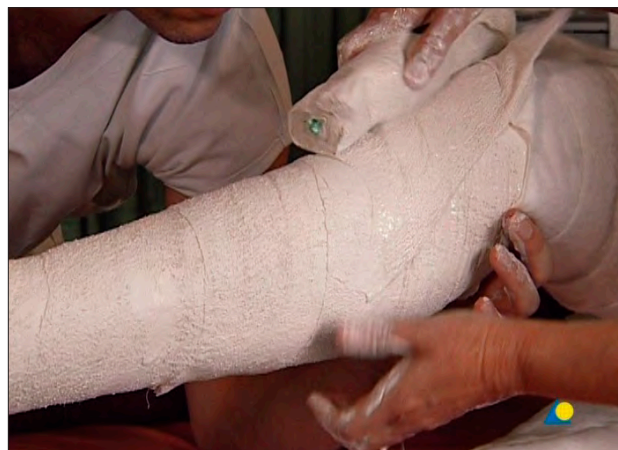

5.2 Additional plaster bandage

Apply a second plaster bandage beginning over where the first one ended.

It continues proximally towards the planned upper edge of the cast and then returns towards the ankle.

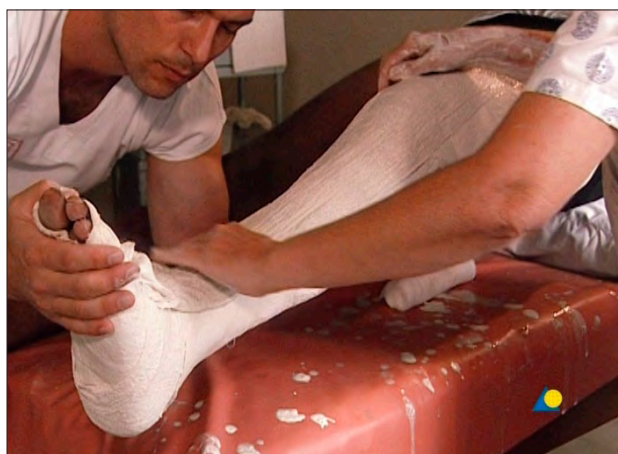As additional plaster bandages are required, they should begin with the end of the previous one, in order to ensure even thickness of the cast.



5.3 Gaining cast strength

To strengthen the cast, apply plaster slabs to both the anterior and posterior aspects.

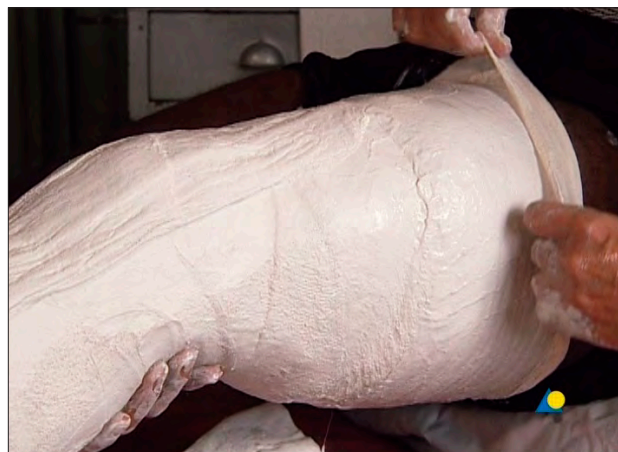A third slab may also be applied to reinforce the proximal edge.



5.4 Forming the proximal end of the cast

Fold the loose end of the stockinette over the proximal edge of the cast.

Starting just below the proximal edge add another plaster bandage. This will secure the loose end of the stockinette and the plaster slabs.



5.5 Knee flexion

You may now place a pillow under the patient's leg, although the knee should continue to be supported manually.

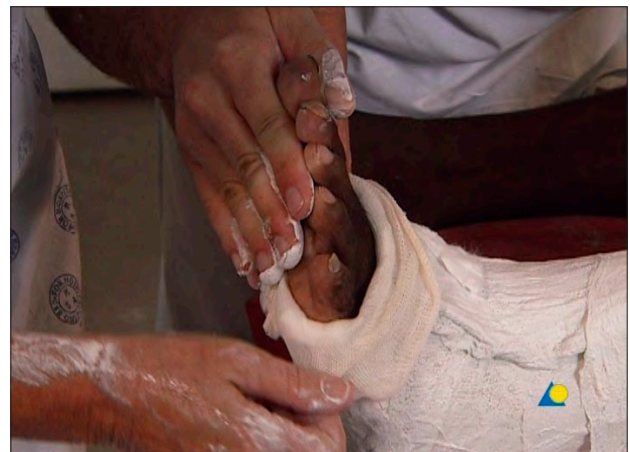Knee flexion of 20-35° will relax the gastrocnemius, as previously discussed. This can be accomplished by a bolster or pillow underneath the supracondylar region, or by bringing the leg off the side, or end, of the table.



5.6 Forming the distal end of the cast

Note the extra plaster covering the toes. This ensures adequate support for the metatarsal heads.

Remove the excess plaster with the scissors and fold the stockinette over the distal end of the cast.

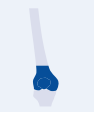

Apply another plaster bandage to secure the ankle and the loose end of the stockinette at the distal edge.

As before, apply it in a figure-of-eight around the ankle.

Attempts should be made to ensure that the foot is at 90° to the lower leg. If the foot drops into equinus, it will be difficult to correct a soft-tissue deformity later.





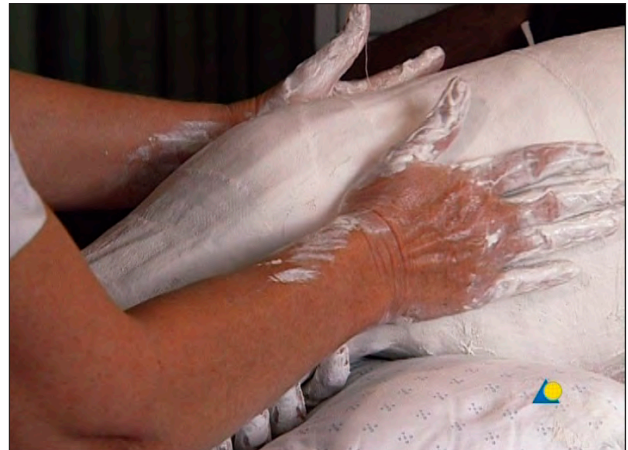5.7 Final molding

While the plaster is still soft, mold it gently to the curve of the tibia and around the knee. In addition, a supra-condylar mold is important for the cast to control the length of the limb.

Check to ensure that there is no rotation of the fracture, by verifying that the second toe, patella and superior iliac spine remain in line.

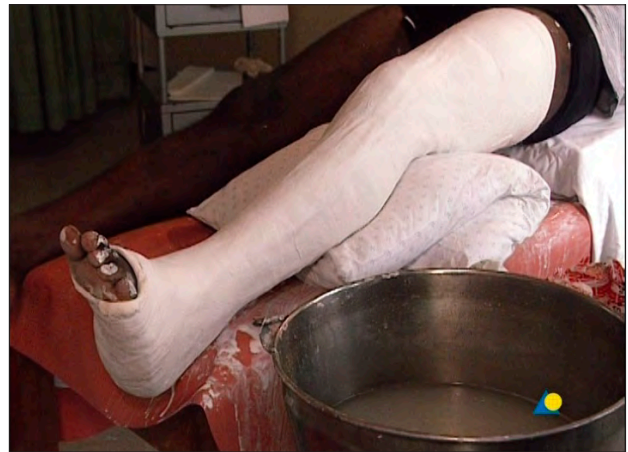To ensure that the foot is plantigrade, apply gentle pressure to the sole of the forefoot.

The pressure should be continued until the plaster hardens. However, the plaster will not achieve full strength for 36 hours.



5.8 Completed cast

The application of the long leg circular cast is now complete.





6 Aftercare following long leg cast application

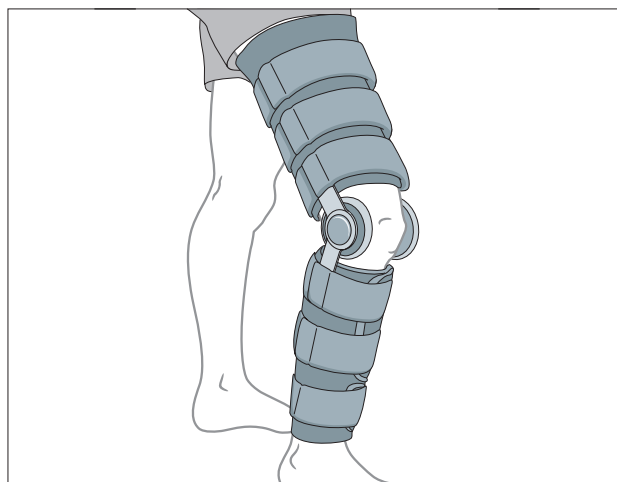
The long leg circular cast is not intended to be a weight-bearing cast, so the patient will need to use crutches, or a walker. The leg should be kept elevated, whenever possible, to prevent additional swelling.

The exercises for the patient should be explained and demonstrated. These include: flexing the toes and lifting the leg.

A major concern with the use of a long leg cast for a distal femoral fracture is knee joint stiffness. Therefore, the duration of treatment in the long leg cast should be as short as possible (4-6 weeks). After this period, the cast will be changed to a hinged knee brace, or hinged knee cast to allow knee flexion and extension. This would be applied as soon as firm callus formation is present.

6.1 Weight bearing

Weight bearing would be started at approximately 8-12 weeks following injury.



6.2 Radiological review

There should be regular radiological review until fracture union.

6.3 Thrombo-embolic prophylaxis

Consideration should be given to thrombo-embolic prophylaxis, according to local treatment guidelines.



3 Femoral fractures

3.13 II Distal femoral fractures – Temporary long leg splint

Indication **All 33-A, 33-B, and 33-C type fractures**

1 Principles

1.1 General considerations

Long leg splintage is a useful technique for temporary immobilization of a fracture involving the distal femur. It can be used in the emergency room to immobilize the limb of a patient with an isolated injury. It can also be used as a temporary aid to fracture stabilization in the multiple injured patient.

1.2 Types of splint

The splint is both inexpensive, and both easy and quick to apply. It is not possible, however, to obtain good three point immobilization of distal femoral fractures with any splint. The conical shape of the thigh will not allow for close apposition of a splint.

1.3 Common deformity

It is recognized that perfect realignment of a displaced distal femoral fracture will be impossible with a long leg cylinder splint. However, it helps to bring the fracture out to length and to correct some of the common hyperextension deformity.

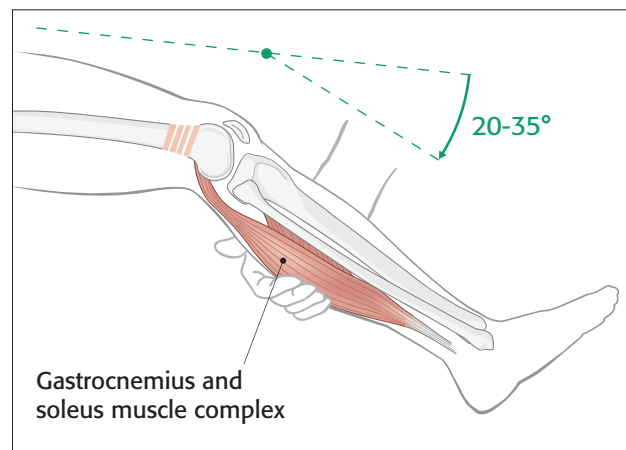
Note: If the splint is not able to control the length adequately, this would be an indication for tibial skeletal traction, when a spanning external fixator could not be made available for provisional stabilization.

The surgeon applying the long leg splint must remember that the common deformity of a supracondylar femoral fracture (A- or C-type fractures) is shortening and hyperextension of the distal fragment. In order to counteract the hyperextension, either a bolster can be placed under the supracondylar region, or preferably the knee can be sufficiently flexed by bringing the leg off the end or side of the table.

Care should always be taken with any splint to protect pressure areas, such as the Achilles tendon, lateral and medial malleoli and the heel, as ulceration in these areas can be extremely difficult to treat.

Fixed splints should not be applied to patients that have other pathological conditions in the lower limb, neurological compromise that causes sensory defects, such as spinal injury, or diabetes with peripheral neuropathy, or in patients who are unconscious.

For treatment of distal-femur fractures alone the ankle does not need to be immobilized and therefore a cylinder splint can be used. If there is an ipsilateral ankle, or foot, fracture, the long leg cylinder splint can be converted to one that incorporates the ankle and foot. A cylinder long leg splint is described here, as it is the most commonly used.

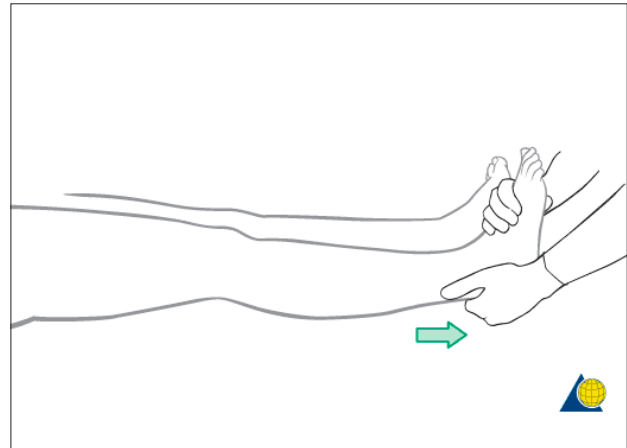


In order to maintain the length of the fracture in the long leg splint care must be taken to provide good supracondylar molding.

2 Splint application

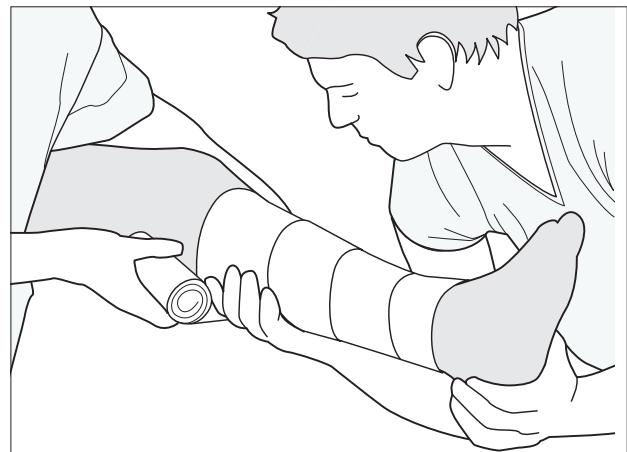
2.1 Manual traction

A preliminary reduction of the distal femoral fracture is performed. An assistant is needed to provide manual traction through the ankle while the splint is being applied.



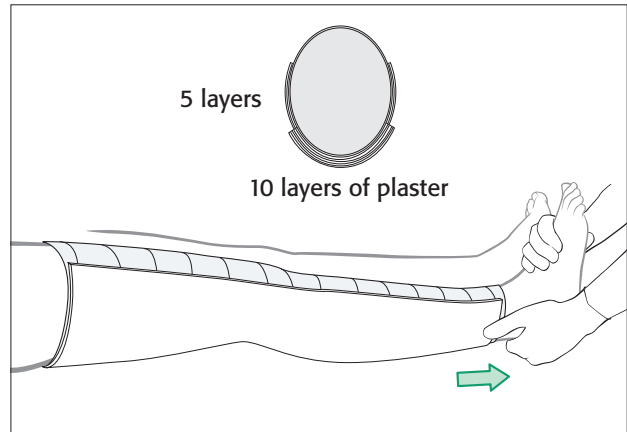
2.2 Splint padding

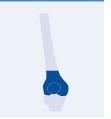With the leg under manual traction and the knee flexed 20°, ample splint padding is then placed around the leg. The padding starts at the supramalleolar region and extends up to the top of the thigh. It is important to make this several layers thick above the ankle and at the upper thigh to reduce the risk of pressure problems in these areas.



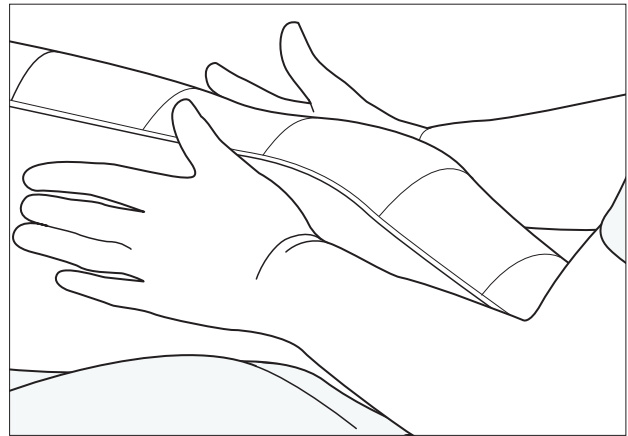
2.3 Splint application

12.5 cm wide plaster slabs are used medially, laterally, and posteriorly. Medially and laterally, 5 layers of plaster are used. Posteriorly, 10 layers of plaster are used. The plaster is wetted, placed on the leg and then secured with additional cast padding and elastic bandages.



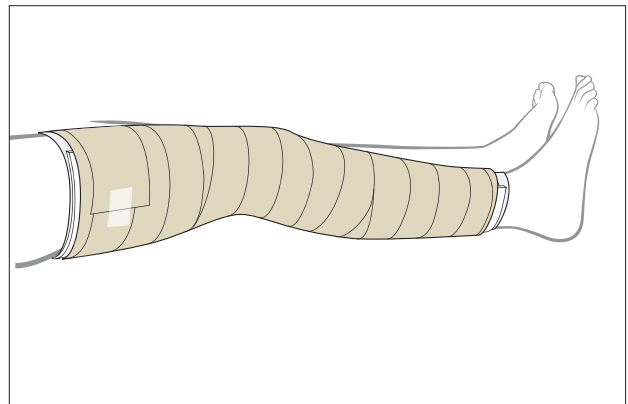


While the plaster is drying supracondylar molding is performed and held until the splint material is hard.



2.4 Elastic bandage

The elastic bandage should not be placed too tightly around the leg. The advantage of the non-circumferential splint is that it allows for swelling and it is therefore ideal during the early days following a fracture.



3 Aftercare following long leg splint application

The splint is intended for provisional stabilization and can be used for up to 2-3 weeks. In general, it is taken off in the operating room before operative management. In the rare case of definitive nonoperative treatment, it can be converted to a long leg cast at 1-2 weeks, after the swelling has subsided.

3.1 Thrombo-embolic prophylaxis

Consideration should be given to thrombo-embolic prophylaxis, according to local treatment guidelines.

3 Femoral fractures

3.13 III Distal femoral fractures - Temporary skeletal traction

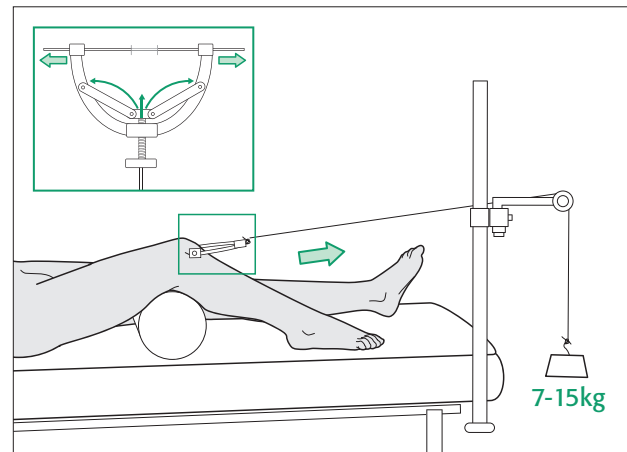
Indication **33-A1.2/3, 33-A2, 33-A3 and 33-C type fractures**

1 Principles

In cases where it is not possible to proceed to early definitive osteosynthesis (polytrauma, soft-tissue problems, patient condition, limited resources), a spanning external fixator is often used. A long leg splint can also be applied.

Temporary, proximal tibial, skeletal traction is reserved for those cases in which it is not possible to place a spanning external fixator, or use a long leg splint.

Care should be taken to protect pressure points on the skin.



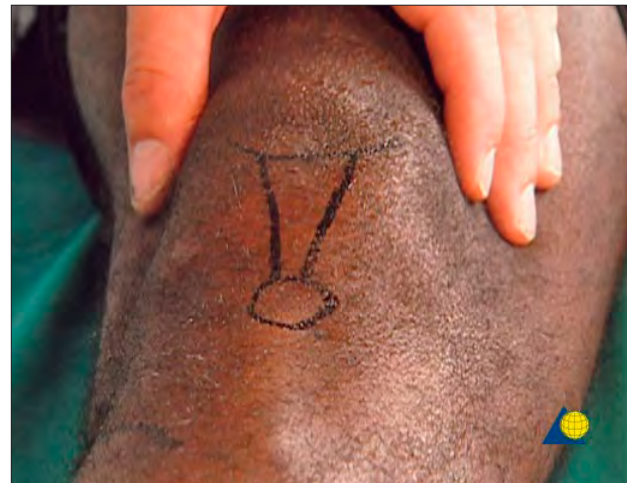2 Surface anatomy

Tibial tuberosity/patella/common peroneal nerve
Bend the knee to make identification of the surface anatomy easier.

First, locate the prominence of the tibial tuberosity and circle it with a skin marker.

Next, identify the patella, followed by the infrapatellar tendon.

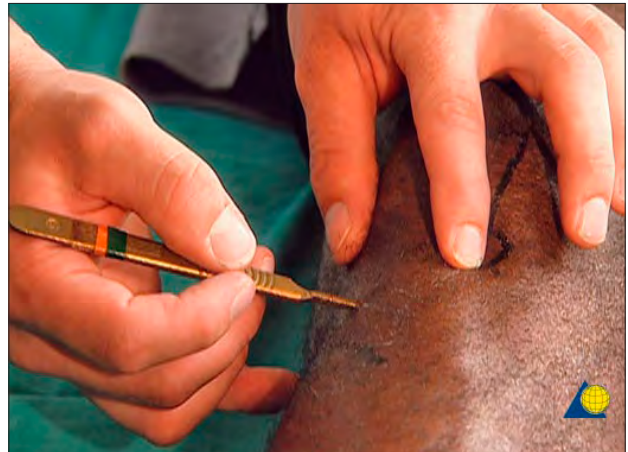Rotate the leg internally and palpate the fibular head. The location of the peroneal nerve is just posterior to the fibular head. This area should be avoided during pin insertion.



3 Pin insertion

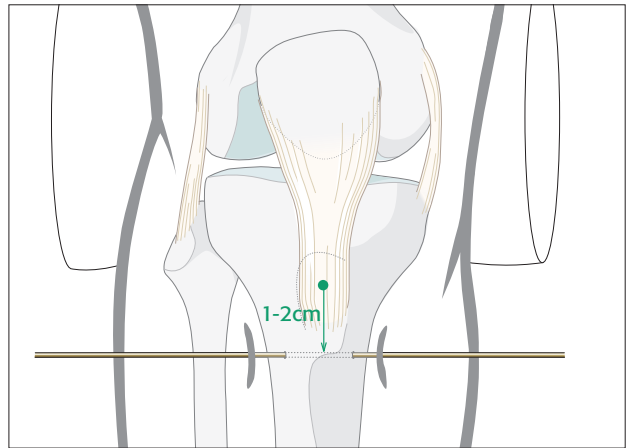
3.1 Stab incision

Use a local anesthetic injected subcutaneously down to the tibial periosteum. Make a stab incision approximately 2.5 cm posterior to the tibial tuberosity avoiding the peroneal nerve.



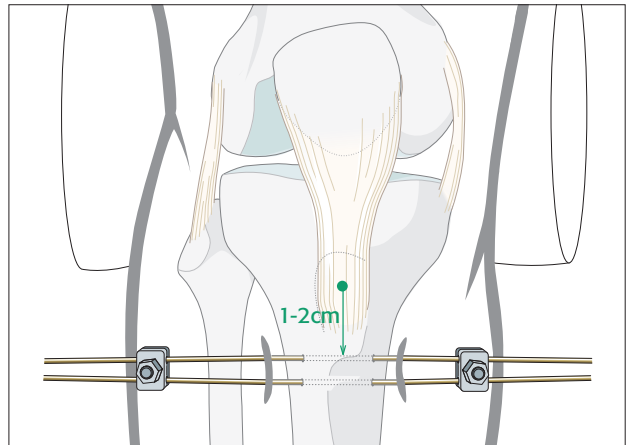
3.2 Wire insertion

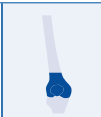Insert a large K-wire, or a strong Steinmann pin, 1-2 cm distal to the level of the tibial tubercle. Ensure that the pin is inserted 1 cm posterior to the anterior cortex of the tibia to ensure that it does not cut out of the tibia.



In elderly patients with osteoporotic bone if long term temporary fixation is required the pin may need to be incorporated into a below knee plaster.

Alternatively, two parallel pins, about 1 cm apart, pre-loaded, and linked medially and laterally with Hoffmann-type external fixator clamps, will reduce the risk of cutting out.

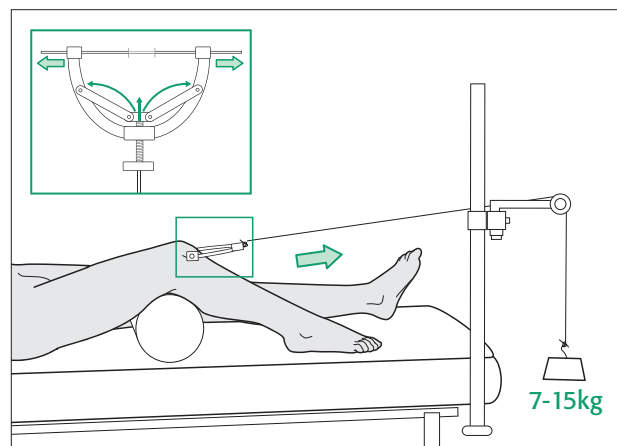




4 Application of skeletal traction

After the wire has been inserted, connect it to an appropriate stirrup with 7-15 kg skeletal traction. Place a padded bolster in the supracondylar region to allow for knee flexion.

There may need to be some counter traction and the foot of the bed may need to be elevated.



5 Aftercare following skeletal traction application

Skeletal traction is usually a temporary device for stabilization of the polytraumatized patient, if a spanning external fixator is for some reason not possible. In general, it would be left on for several days, up to 2 weeks. After this time, definitive surgical stabilization of the distal femoral fracture would be performed.

The traction pin sites require regular dressing. If pin

site infection occurs this will need to be treated with appropriate antibiotics and topical antiseptic application.

Inherent in this temporary stabilization are the problems of immobility, pain control, bed sores and heel ulcers. These issues must be carefully addressed during the period of skeletal traction.

Thrombo-embolic prophylaxis

Consideration should be given to thrombo-embolic prophylaxis, according to local treatment guidelines.



4 Tibial and malleolar fractures

4.11 I Proximal tibial fractures – Nonoperative treatment

Indication **All 41-A, 41-B, and 41-C type fractures**

1. No immobilization, non-weight bearing and early motion

1.1 Indication

Undisplaced fracture which is perfectly stable. Nonoperative treatment is indicated if the fracture is undisplaced or minimally displaced and the joint is absolutely stable and there are no other indications for surgery (eg., neurovascular injury, compartment syndrome).

Never immobilize in plaster. If splinting is necessary, then immobilize in a hinged fracture brace. Start early active range of motion as soon as possible.

2 Posterior plaster splint

2.1 Indication

Only as a means of temporary splinting.

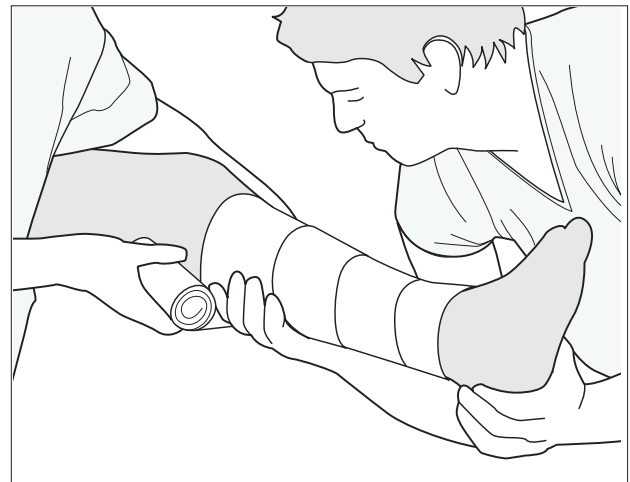
3 Cylinder cast (stove pipe)

3.1 Indication

For stable extraarticular fractures as a means of definitive treatment.

3.2 Splint padding

With the limb in extension and supported, apply splint padding around the leg. Begin high in the thigh and extend it four finger breadths above the malleoli. Make the padding five layers thick in the upper thigh and particularly above the malleoli to prevent pressure problems. Cylinder cast (stove pipe)



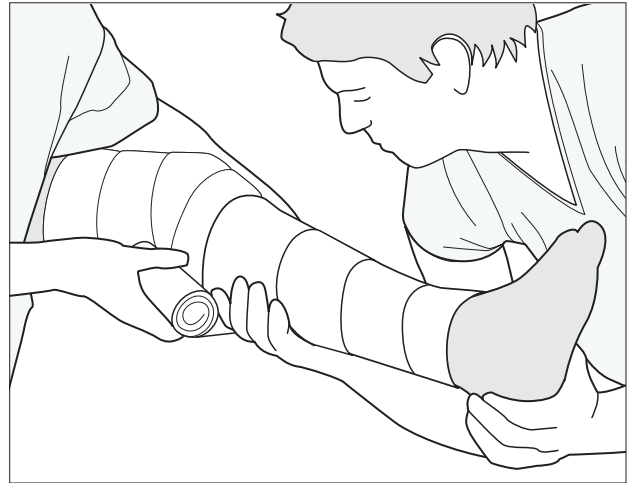


4 Tibial and malleolar fractures

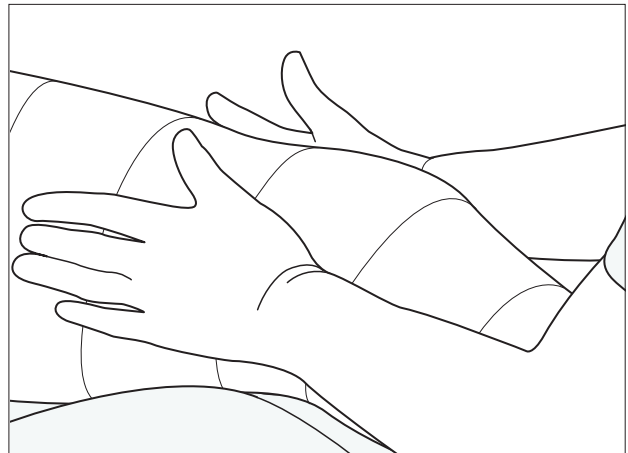
4.11 Proximal tibial fractures— Nonoperative treatment

3.3 Plaster application

15 cm wide plaster is applied in a circular way around the lower limb starting from high on the thigh until the supramalleolar region. Use 5 layers of plaster.



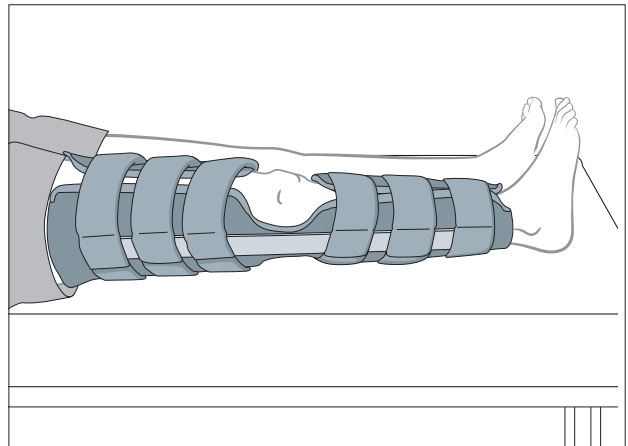
While the plaster is drying a supracondylar mold is placed and held until the cast material is hard.



4 Non-hinged fracture brace (Zimmer knee brace)

4.1 Indication

All fractures as a means of temporary splinting.





5 Hinged fracture brace

5.1 Indication

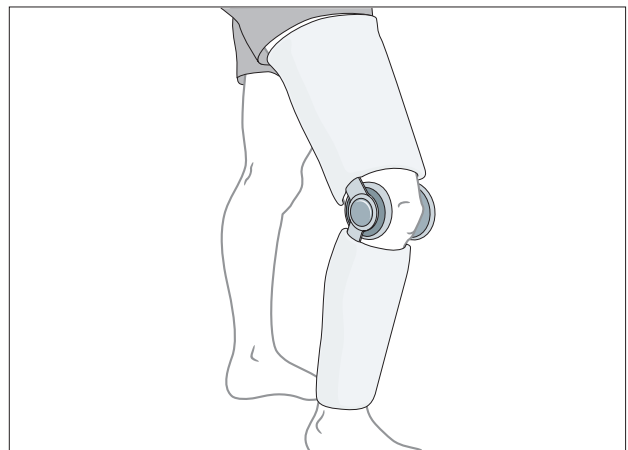
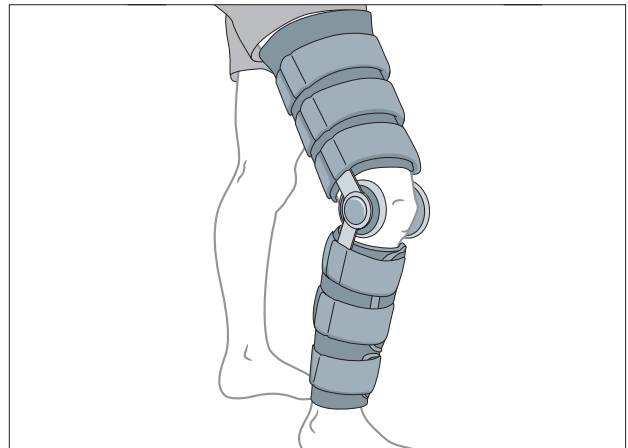
Angular splinting of the extremity allowing early knee motion.

As a means of definitive splinting allowing early motion.

5.2 Fracture brace

Never immobilize in plaster. If protection is required to prevent displacement, use a hinged fracture brace to permit early motion.

Axial splinting allowing knee motion.





4 Tibial and malleolar fractures

4.12 I Tibial shaft fractures – Management with limited resources

Indication **All tibial shaft fractures**

1 General considerations

The primary goal of treatment for tibial shaft fractures is to restore normal anatomy («reduction» i.e. realignment of the fracture) and normal function of the leg. Treatment should be effective and avoid unnecessary risks.

1.1 Essential operative treatment

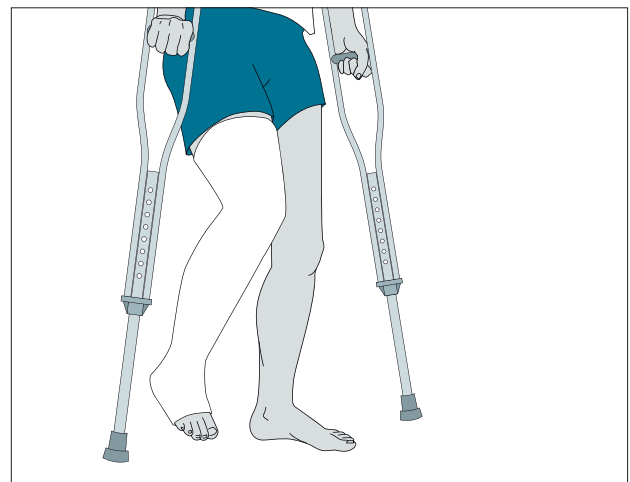
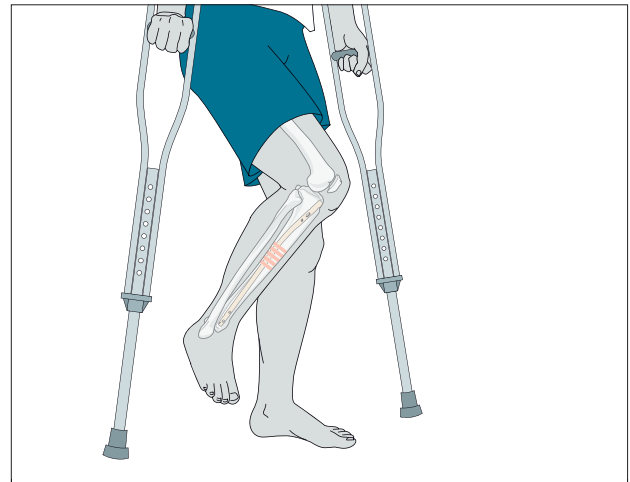
Surgical treatment is necessary for open fractures (wound debridement), compartment syndromes, and repair of arterial injuries. These issues are covered elsewhere.

1.2 Operative fracture management

Operative treatment of displaced unstable tibia shaft fractures is the treatment of choice if it can be performed in facilities with the necessary equipment and skills.

1.3 Nonoperative fracture management

Nonoperative treatment of these injuries is chosen when safe, appropriate operative treatment is unavailable. Non-operative treatment options to immobilize the fracture include splints, traction, or in most cases circular casts plaster of Paris (POP). Splints are used as a first aid emergency treatment or short term initial management. Fiberglass / resin cast material is an alternative to plaster of Paris, more expensive, but more durable and lighter. If available, a thin layer of fiberglass may be used to reinforce a plaster cast.





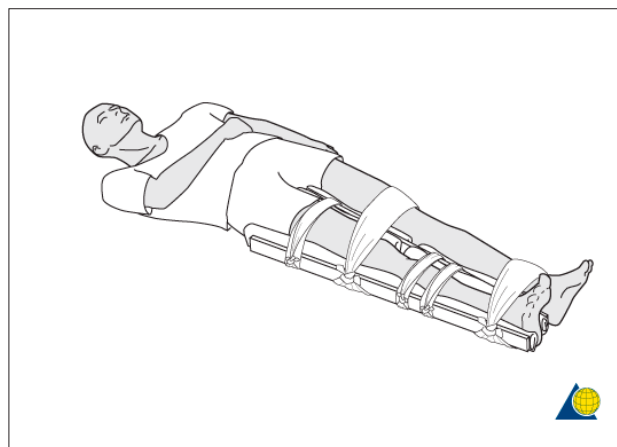
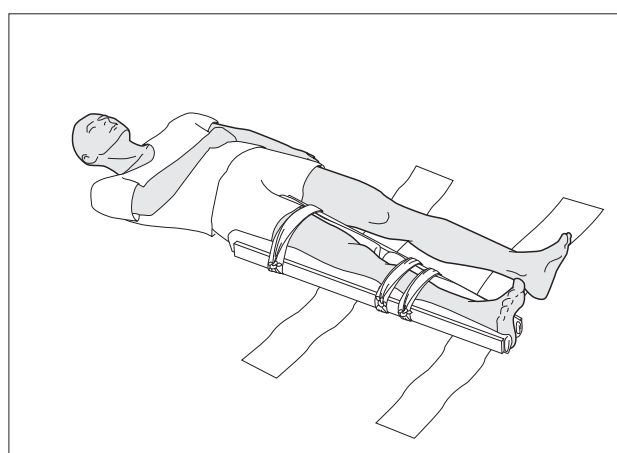
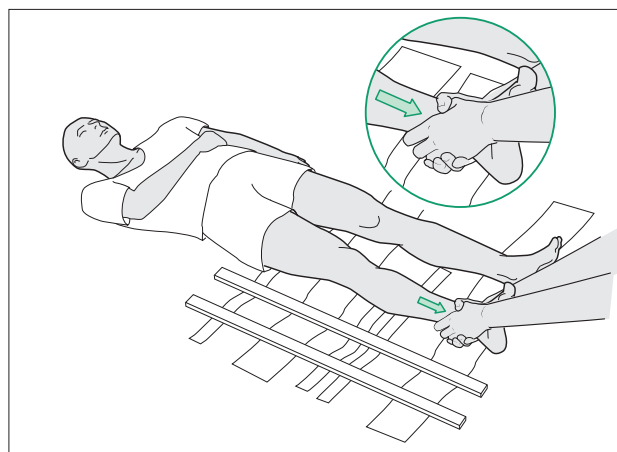
2 First aid for tibial fractures

The ABCs of primary care for the injured always take precedence over fracture treatment. Once the safety of the patient is established, attention is turned to the fracture.

An important step in treating a tibia shaft fracture is promptly to realign the deformed leg and to splint it in corrected alignment. Splinting can be done with two firm boards, or sticks alongside the leg, from above the knee to below the ankle.

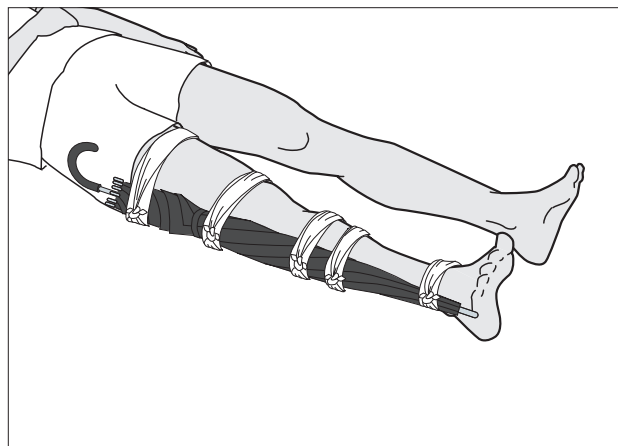
It is essential to apply padding between a splint and the injured leg. Any soft material such as clothing, blankets, etc. can be used as emergency padding. The splints should then be kept together by bandages around both splints and the leg.

Additional stabilization can be achieved by splinting the fractured leg to the contralateral normal lower extremity.





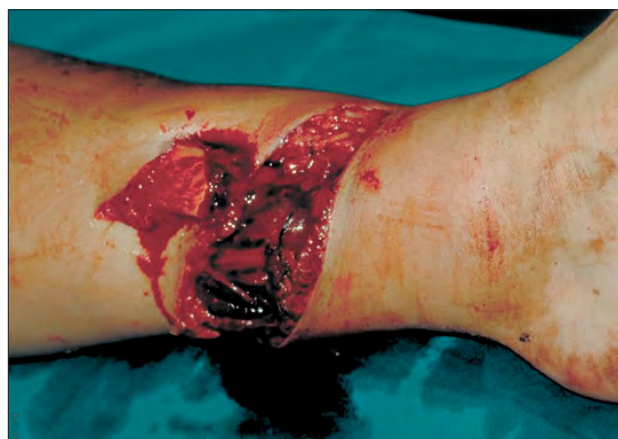Any padded splintage is better than none, but circumferential wraps must not be so tightly applied that they interfere with blood flow.



3 Open fractures

For open fractures, the wound should be covered with the cleanest material available, preferably a sterile dressing.

This initial temporary cover should not be disturbed until the patient is in the cleanest available hospital setting.



3.1 Wound Debridement

Adequate surgical debridement is essential to decrease the risk of infection, a major concern for all open fractures. Dressing and splint should remain in place until the patient is anesthetized for debridement in the operating room. Debridement involves excising

dead tissue, removing foreign material, and thorough irrigation. Typically, wound closure is delayed, and the wound is covered with a moist sterile dressing. Post-debridement immobilization is typically provided with skeletal traction, splints, or circular cast, but if available, a properly applied external fixator is often better.

4 Calcaneal pin traction

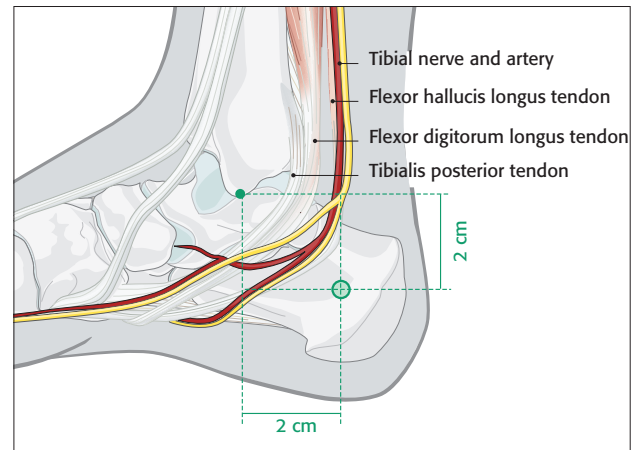
4.1 Application of calcaneal pin traction

If an external fixator is not available, open fractures, especially if they need repeated wound care, can be treated in the short term with calcaneal pin traction on a Braun frame.

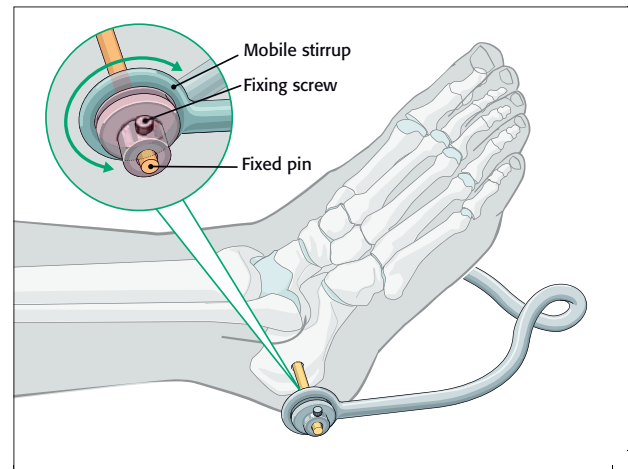
4.2 Calcaneal pin insertion

If the patient is not under general or regional anaesthesia, the pin is inserted under local anesthetic (eg, 2% lidocaine, 5 ml on each side of the calcaneus) 2 cm below and 2 cm behind the medial malleolus.

Skeletal traction on a Braun frame is also valuable for maintaining length of unstable multifragmentary closed tibial fractures (those for which stability cannot be restored with realignment alone.)



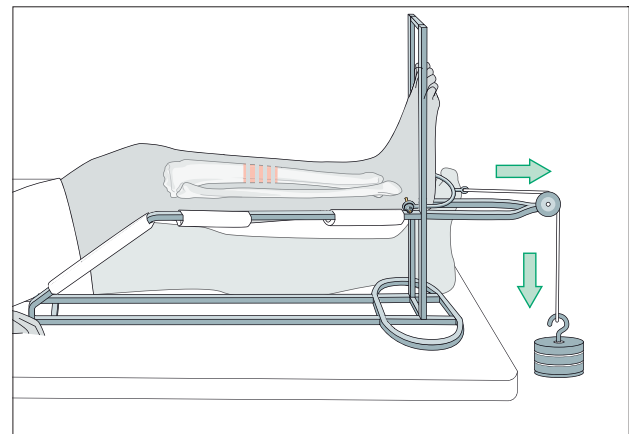
It is important that the stirrup is able to rotate around the Steinman pin to prevent rotation of the pin in the bone. Rotating pins loosen quickly. Loose pins significantly increase the risk of pin track infection.



4.3 Positioning in Braun frame with 3-4kg traction

The illustration shows a tibia fracture immobilized with calcaneal traction and supported on a Braun frame. The frame supports the thigh and the proximal tibial segment. Pressure against the thigh provides counter traction. The traction force and frame with fabric supports maintain fracture alignment.

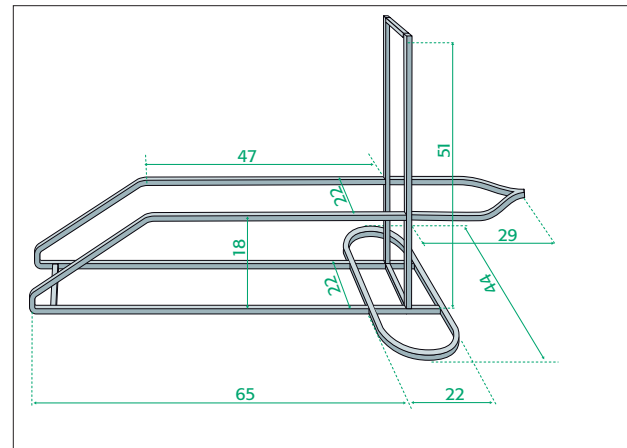
The non-elastic supports on the Braun frame are arranged to leave a gap, which allows wound care without changing the leg position.





4.4 Construction of a Braun frame

Braun frames may be difficult to obtain. A satisfactory Braun frame can be made from metal bar stock (5 mm x 20 mm) according to the illustration.



5 Introduction to tibial fracture reduction and cast application

If there is no need for wound care, and the fracture is length-stable, either from its configuration and/or reduction, or after development of sufficient callus, a cast can be applied.

Usually, for a tibial shaft fracture, particularly if proximal, this cast should extend above the knee – a half to two-thirds the length of the thigh.

Tibia fractures rarely shorten more than the amount present on the initial x-ray (presuming this is obtained without traction). If shortening is greater than 1.5-2 cm, and if a length-stable reduction (transverse; end-on-end, and supported effectively by the cast) cannot be achieved, traction, or surgical fixation (external or internal fixation) will be necessary to prevent shortening. Lesser degrees of shortening are usually well tolerated.

6 Preparation for cast application

It is essential to prepare the patient and all necessary material and equipment before beginning the processes of fracture reduction and cast application.

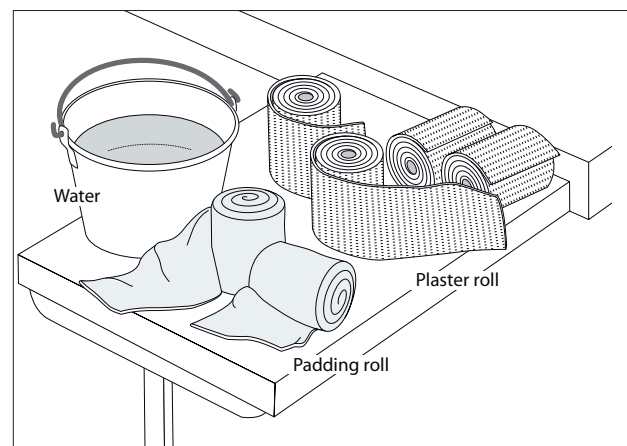
6.1 Anaesthesia

Both fracture manipulation and motion relation to cast application are painful. Fracture reduction is therefore best done with a regional or general anaesthetic. Occasionally a fresh closed fracture can be anaesthetized with sterile injection of local anaesthetic into the fracture hematoma.

6.2 Required material

- Examination couch or table
- 2-4 rolls 150 mm padding
- 8-9 plaster of Paris (POP) rolls, 150 mm wide
- Bucket with cool water
- Pillows to support casted leg
- Aprons to protect team members and patient
- Paper to cover the floor

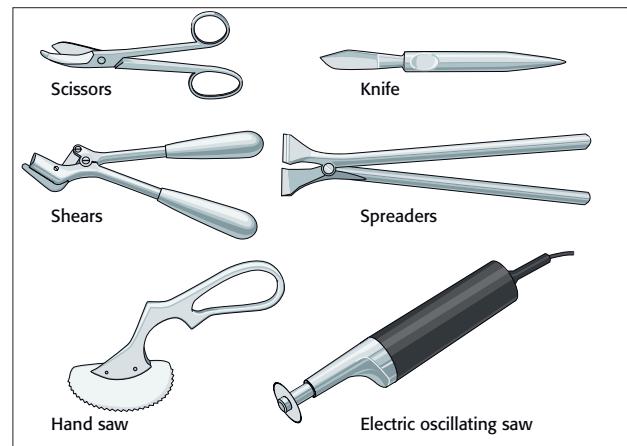
Everything must be assembled and ready before beginning the procedure.



6.3 Required equipment

Scissors and knife can be used to cut POP cast when still wet, just before it sets.

The other tools are required for dry POP.



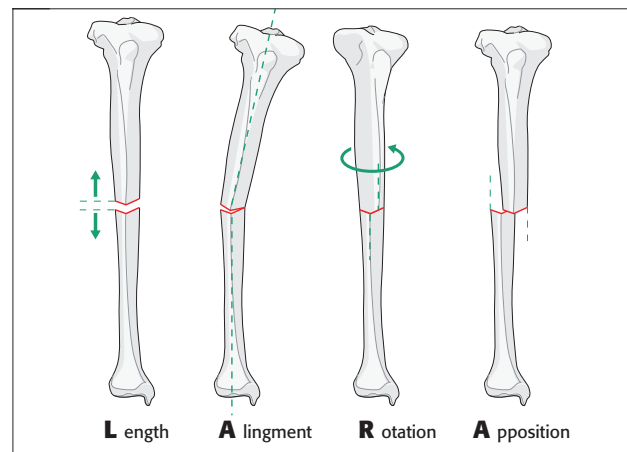
7 Fracture reduction

7.1 Reduction principles

Reducing a fracture means restoring acceptable alignment. Proper reduction of a tibial shaft fracture requires correction of

- length
- axial alignment
- rotation
- apposition (bone contact)

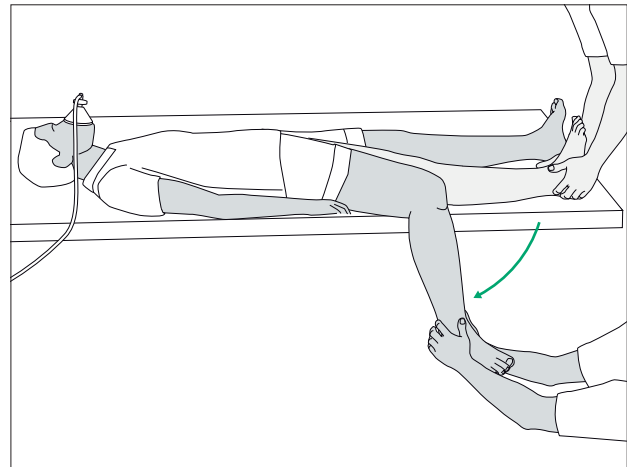
If no x-rays are available during the procedure, the reduction is orientated with reference to the uninjured leg.



7.2 Reduction

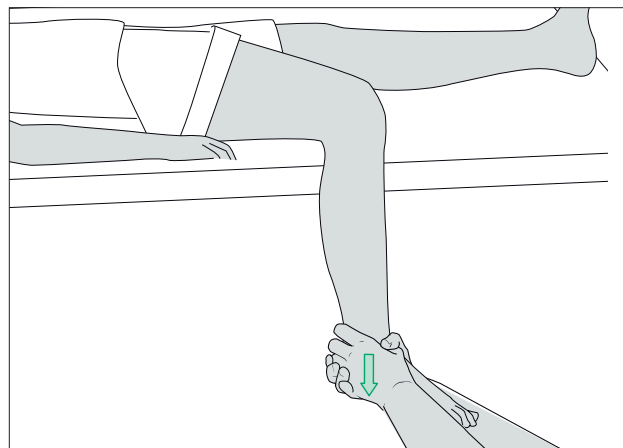
During fracture reduction, the patient needs pain relief and muscle relaxation. Depending on the resources, this might be analgesia plus sedation, but preferably regional or general anesthesia.

Once the pain relief takes effect, the splint can be removed and the knee gently bent so that the lower leg is in a hanging position.



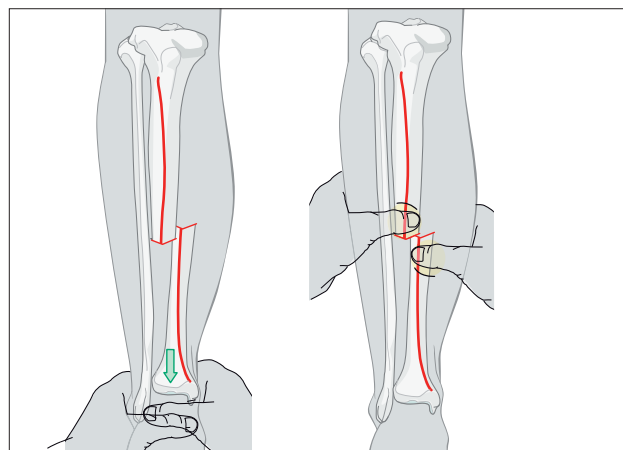


Fracture reduction is easiest with the leg hanging beside the table, with enough space between the leg and the table edge to apply the cast. The fully flexed knee relaxes the calf muscles, helps control rotation, and permits ankle dorsiflexion to neutral (90° to the leg). The person treating the fracture pulls with both hands on the heel and ankle to overcome any shortening.

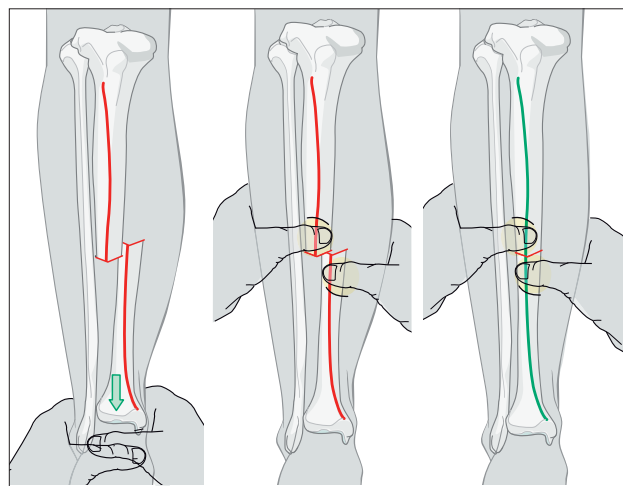


The illustration demonstrates reduction of a transverse fracture. Reducing the distal fracture fragment anatomically restores length. The length is stable as long as the distal fragment is «hooked onto» the proximal one. A cast can maintain this length-stable reduction fairly easily.

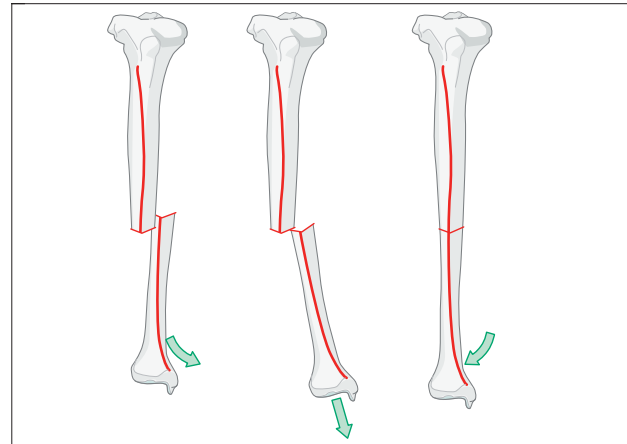
Fractures which are not transverse (spiral, oblique, or multifragmentary) cannot be «hooked on» and thus lack length stability. Shortening of 1 cm or even 2 cm is acceptable, but axial alignment, rotation and apposition are still important to restore.



Rotation and apposition can be judged and corrected by aligning the anterior tibial crest of the distal fragment with the proximal one. This part of the reduction is aided and confirmed by local palpation. Rotational alignment is indicated by the angle between the foot axis and that of the thigh. This angle should match that of the opposite lower extremity.



End-on-end apposition of a transverse fracture can be difficult to achieve with traction and transverse pressure. In this case, as illustrated, increasing angulation may allow the fracture ends to be hooked, followed by deangulation to correct the tibial axis.



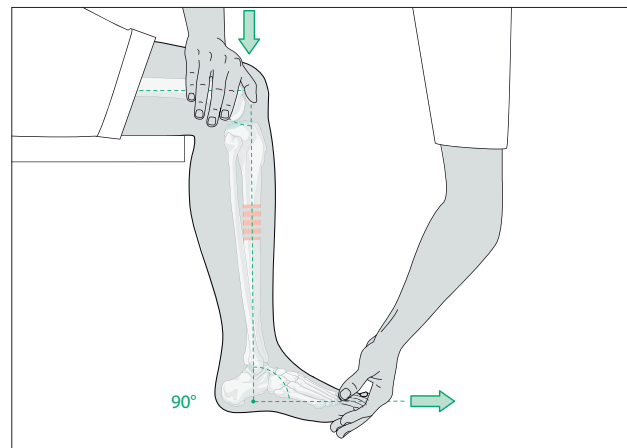
8 Cast application

Cast application is far easier with the aid of an assistant. One person holds the reduction while the other (operator) applies the cast. If both are skilled in cast application, typically the one in charge takes responsibility for holding the reduction. If he or she must personally apply the cast, the assistant holds the leg. Reduction should be repeatedly verified during cast application.

8.1 Holding the reduced position

The leg-holder stands on the medial side of the injured leg and controls the knee and thigh position while holding the ankle dorsiflexed to neutral. Rotational alignment is approximated by holding the big toe in line with the patella, as seen from superiorly or anteriorly. This maintains the normal slight external rotation of the tibia. This technique usually holds the reduction that has been achieved, and allows the operator to apply the padding and the plaster cast.

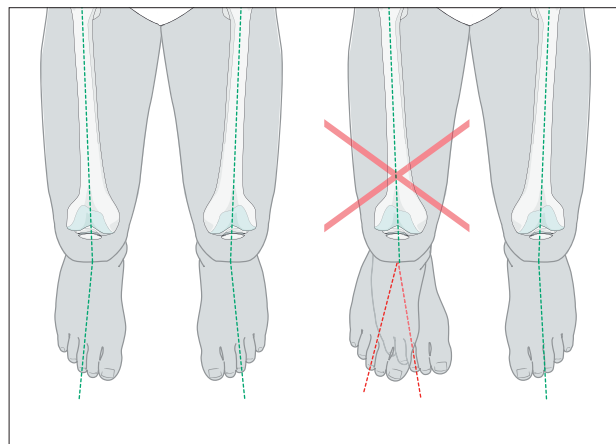
Tip: Avoid strong dorsiflexion of the foot as this can cause recurvatum (apex-posterior angulation) of the lower leg.





8.2 Assessment of rotational reduction

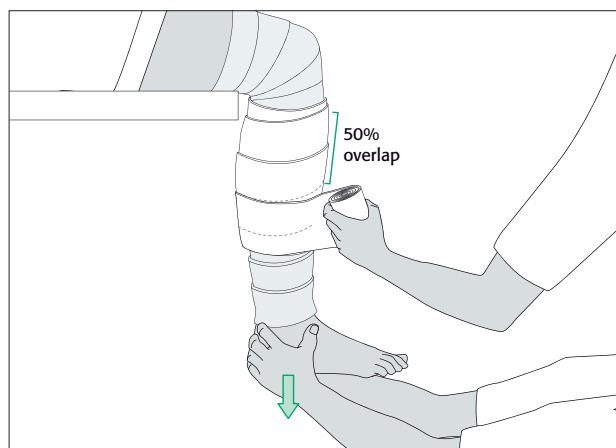
The best way to assess the rotational alignment of the tibia is by means of the angle between the long axes of the thigh and of the foot. If the rotational reduction is correct, the long axis of the foot is slightly externally rotated relative to the axis of the thigh. This foot-thigh angle should be the same as for the opposite lower extremity.



8.3 Application of POP

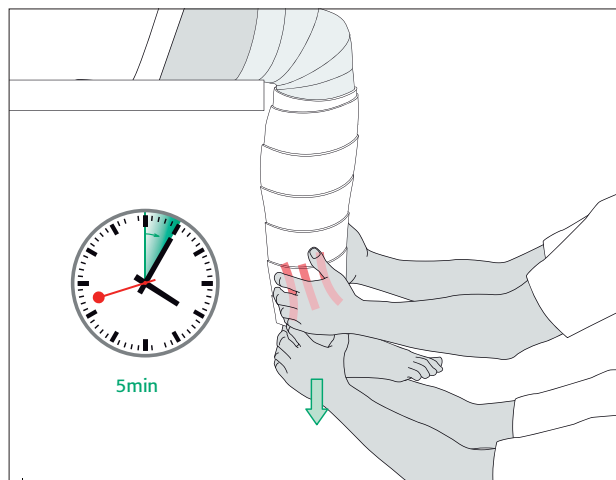
One of the treating team applies the padding from below the ankle to just above the knee.

Next, while maintaining the fracture reduction, apply around the lower leg 2-3 rolls of POP (dipped in cold water to give more time until hardening).

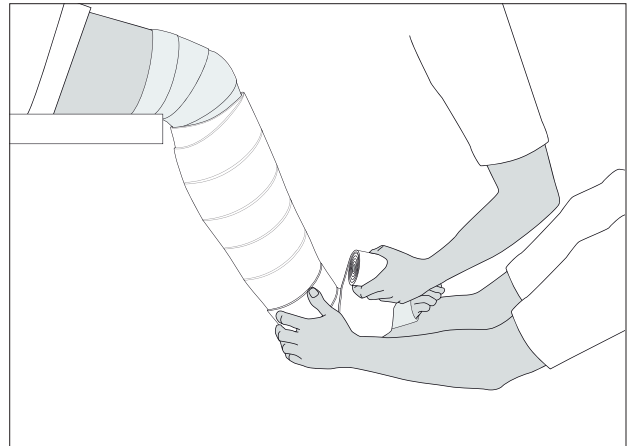


The POP cuff is molded firmly to the lower leg whilst keeping traction on the heel. Relax the molding pressure only when the POP cuff is firm (4-5 minutes).

Tip: With the tibial axis properly aligned («straight»), the form of the lower leg appears slightly bowed, convex laterally, concave medially, like the opposite tibia. The external appearance of a cast should be similar. If the cast looks absolutely straight, then the tibia is likely to be aligned in valgus.

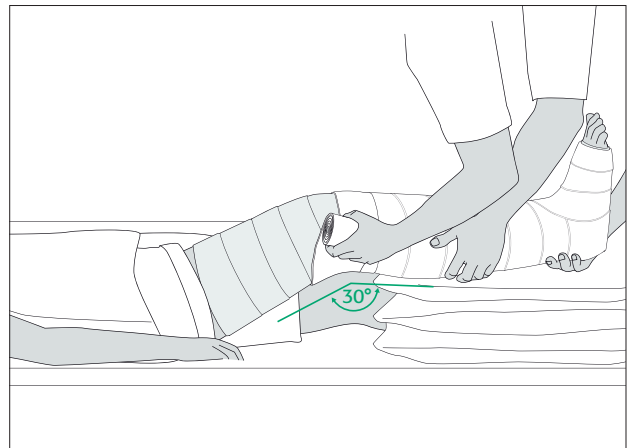


Once the plaster cuff around the lower leg has dried and stabilizes the fracture, the padding and the plaster are extended down around the ankle and the foot as far as the metatarsophalangeal (MTP) joints. Take care not to extend the plaster over the dorsum of the MTP joints, as this blocks dorsiflexion. Do not let padding lie between layers of plaster.



Once the below knee plaster cast is firm, the knee is extended and the lower leg lifted onto a cushioned leg support. One caregiver holds the foot and lower leg to maintain flexion of the knee at about 30° and the other extends the padding and the plaster as high as the upper thigh, remembering not to place padding between layers of plaster.

Always support the wet plaster with the flat hand, do not press dimples into the plaster with the fingertips, as this can cause pressure points inside.



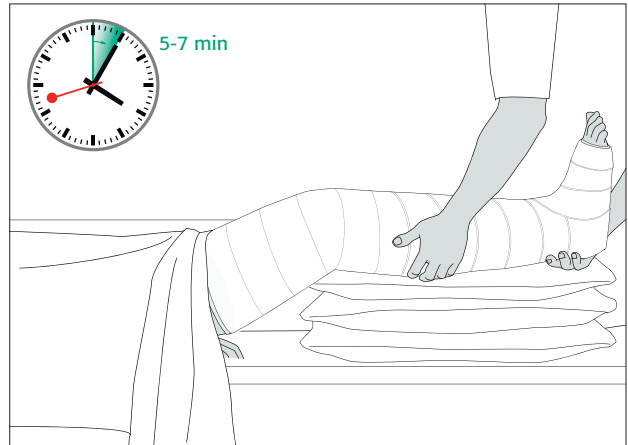
It is important to hold the knee position until the entire cast is firm.

The weak point of the plaster is the junction between the already well-dried below knee POP and the extension to the above knee cast.

This region should be reinforced with an extra roll of plaster.

Elevate the lower leg on 2-3 pillows for three to five days, until it is both firm and fully dry.

X-ray control after reduction should be delayed until the POP is quite dry (24-48 hours). The x-ray will confirm whether the position is acceptable or not.

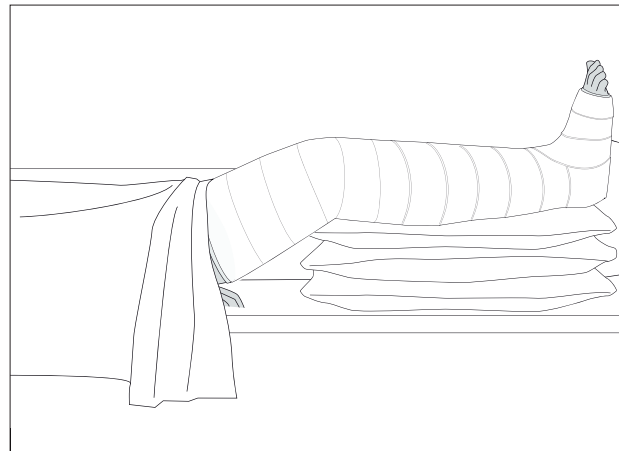




9 Drying of the cast

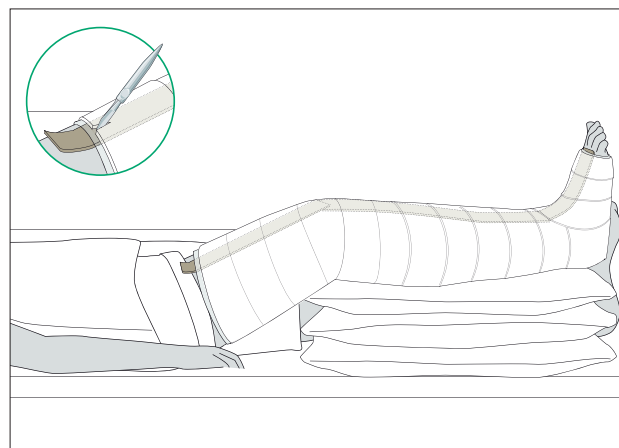
The patient should be warned that the leg in the plaster will feel warm initially and then become cool and moist. The heat is due to the chemical reaction of the plaster's setting; it then cools because of the evaporation of water from the plaster. Once the cast is dry, the moist, cold feeling will disappear.

During the evaporation period, the casted limb should remain exposed and not fully covered by blankets.



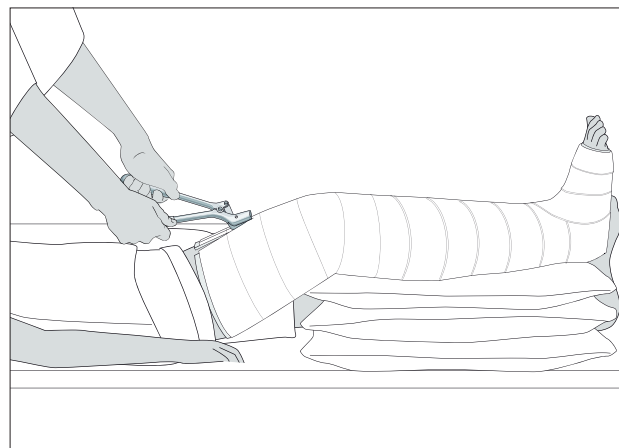
10 Splitting of a plaster

When significant swelling is expected, it may be advisable to split and loosen the plaster. This can be made easier by placing a protective leather or plastic strip over the leg under the plaster before the cast is applied. If the plaster is still damp, it can be cut with a very sharp knife, onto that protective strip which is then removed. Instead of a single split in the cast, a 1-2 cm strip of plaster can be removed. This makes it easier to release the underlying padding.



Alternatively, the plaster can be split using a plaster cutter. An oscillating saw is the easiest way to cut dry plaster, however is not effective if the plaster is still wet. Either way, splitting alone does not loosen the cast. It must be spread to increase its volume.

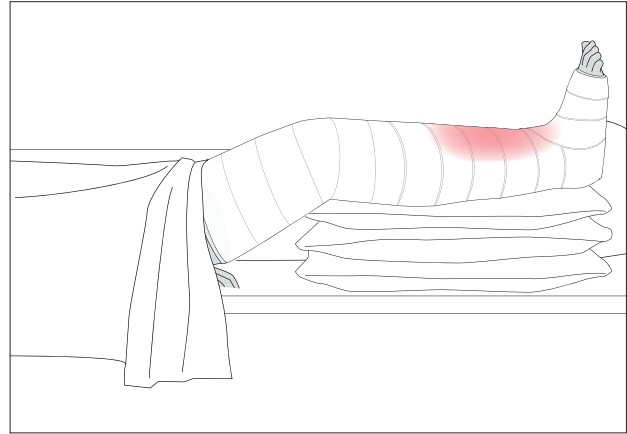
Cast padding must also be cut completely to the skin. Do this carefully using guarded scissors. Even a small strand of hardened padding can act as a circumferential band and cut into a swollen leg.



11 Compartment syndrome

Any plaster, especially one without adequate padding, or applied tightly to an injured leg that is likely to swell (fresh fracture or after significant manipulation), carries a risk of obstructing circulation and causing compartment syndrome.

In case of inappropriate and/or increasing pain, made worse by passive dorsiflexion or plantarflexion of the toes, the plaster and padding should be split immediately down to skin, over its whole length, and spread open enough to ensure that no constriction remains. Then, the leg should be watched carefully. In the absence of rapid recovery, a compartment syndrome may be present. This would require emergency fasciotomy. Loosening the cast, even if it leads to loss of reduction, is better than risking muscle necrosis.



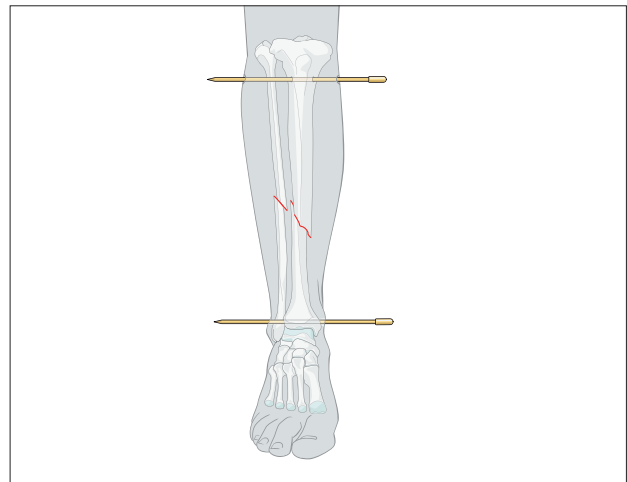
If the slightest suspicion of compartment syndrome remains, ensure that the plaster is completely loose and consider urgent dermatofasciotomy.

12 Pins in plaster

12.1 Steinmann pins as reduction aids and prevention of displacement

Caution: this technique is far inferior to external fixation: pin track infection is common and the method is only to be used if an adequate external fixator is not available.

In unstable, oblique, and multifragmentary fracture types (42-B2/3 and 42-C), in which a stable apposition at the fracture site is not possible, displacement, especially shortening, can be prevented by first passing Steinmann pins through the tibia proximally and distally.



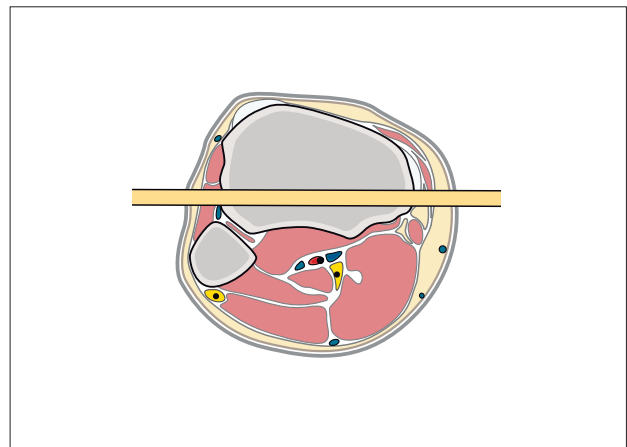
12.2 Insertion of proximal pin

At the entry point, a stab incision is made through the skin with a pointed scalpel.

A Steinmann, or preferably a Denham pin (a Denham pin has a short threaded section in the centre to prevent side-to-side motion of the pin in the bone), mounted in the T-handle, is inserted manually at a point about 2 cm dorsal to the tibial tuberosity.

As the pin is felt to penetrate the far cortex, check that the exit will coincide with the area of local anaesthetic infiltration. If not, inject additional local anaesthetic. Once the point of the pin clearly declares its exit site, make a small stab incision in the overlying skin.

Once the pin is in place, ensure that there is no tension on the skin at the entry and exit points. If there is, then a small relieving incision may be necessary.

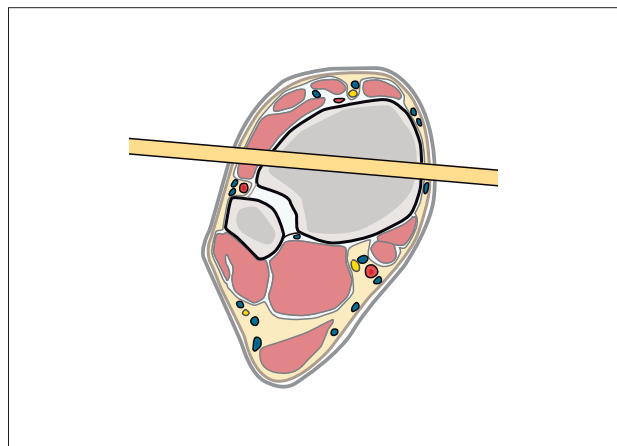




12.3 Insertion of distal tibial pin

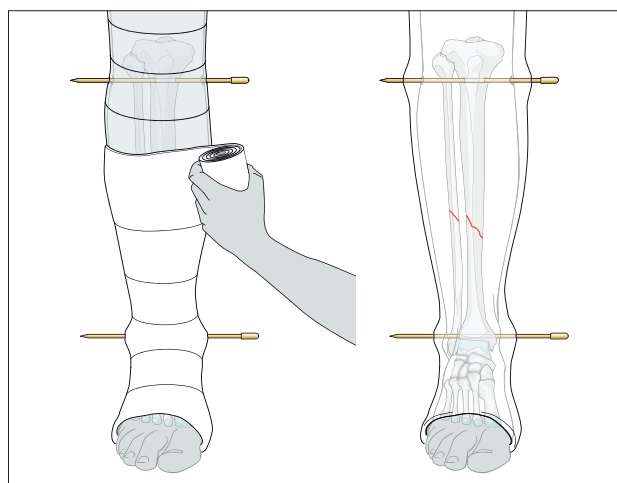
When inserting pins in the distal zone take into account the position of the anterior tibial artery and vein. Percutaneous insertion of pins in this area is dangerous. A minimal incision will allow preparation and safe insertion.

The pin should be inserted from lateral to medial through the middle of the tibia anterior to the fibula, in the frontal plane, so it emerges medially through the subcutaneous surface of the tibia



12.4 Plastering

Make sure that the skin is not under tension from the pin. Incise the skin if necessary to release it. With a small incision no sutures are necessary. Some antibacterial ointment and a sterile dressing are applied over the pin site. The cast is applied, by rolling plaster smoothly up to and incorporating the pin on each side with a thick cuff of plaster (2 cm) around each pin. Be careful not to pull the plaster tightly from one end of the pin to the other, since there should be no extra pressure on the skin. Excessive pin length can be removed with a pin cutter, but at least 2cm or so of pin should be incorporated in the plaster, both medially and laterally.



Note: The transfixion pins can be used as reduction aids. Traction, rotation, and angulation of the pins can be used to correct deformities. This is done before plaster application. Then, with the fracture held reduced, POP is applied, incorporating the pins as described. Once hard, the cast functions as the frame of an external fixator, using the transfixion pins to maintain fracture alignment.

This procedure is usually done under general or regional anesthesia.

Initially the cast should be extended above the knee for better stability and comfort. It can later (3-4 weeks) be shortened to a below knee plaster, still maintaining the pins incorporated in the plaster.

Once the fracture is likely to be sticky (approximately 6 weeks), remove the cast and pins and apply a new cast. At this point it may be appropriate to begin progressive weight bearing.

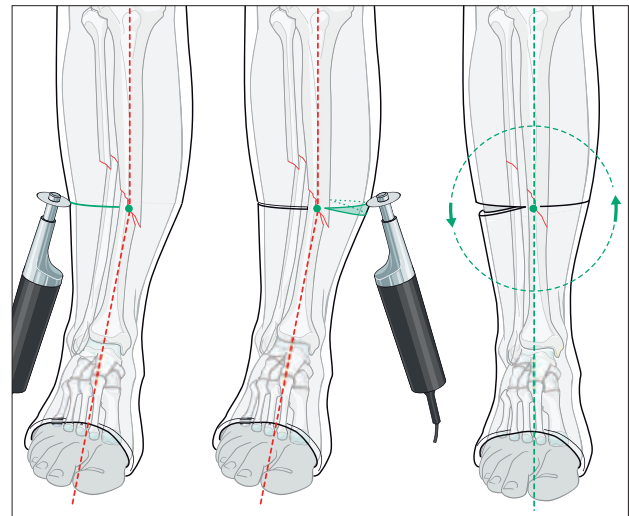
13 Cast wedging

Small angular malalignments can be corrected by wedging without changing the plaster. Wedging needs to be delayed till the plaster cast is completely hardened (day 3 or 4), or later. Wedging is safer if sufficient padding is applied during the original cast application.

Central wedging (preferred technique)

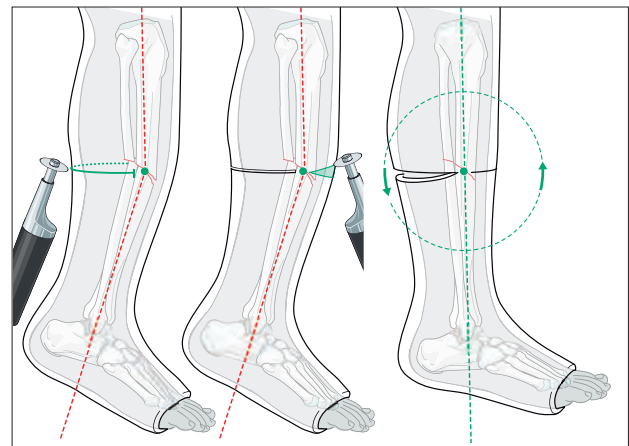
Make a half-circumferential cut in the cast on the concave side of the angulation. An appropriate half-wedge is then removed from the convex side, not quite meeting the first cut, but leaving a 1cm. bridge, as shown. The angulation is then gently corrected, the first cut being held open with a piece of cork (avoid skin pressure), while the open wedge is closed. Note that the anterior and posterior plaster bridges lie on the axis of rotation, perpendicular to the plane of angulation.

The wedging site is then repaired with fresh POP bandaging. Smoothly work the plaster into the open wedge



without skin pressure, and wrap it circumferentially around the cast, 4 or 5 cm proximally and distally, to restore its strength.

The first half-circumferential cut (opening wedge) must be placed on the concave surface, opposite the apex of deformity. The axis of deformity correction (ends of the first cut) is thus properly oriented.



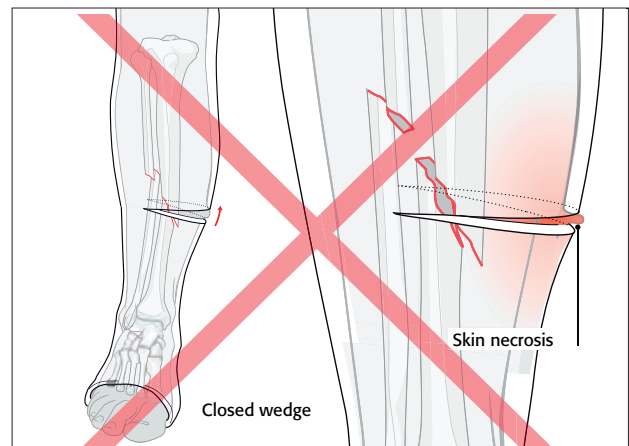
13.1 Pitfall: closing wedge

A simple closing wedge of the cast can pinch the skin and subcutaneous tissues, causing pain and, if not corrected, skin necrosis.

It also effectively shortens the cast, as well as the tibia.

13.2 Pitfall: opening wedge

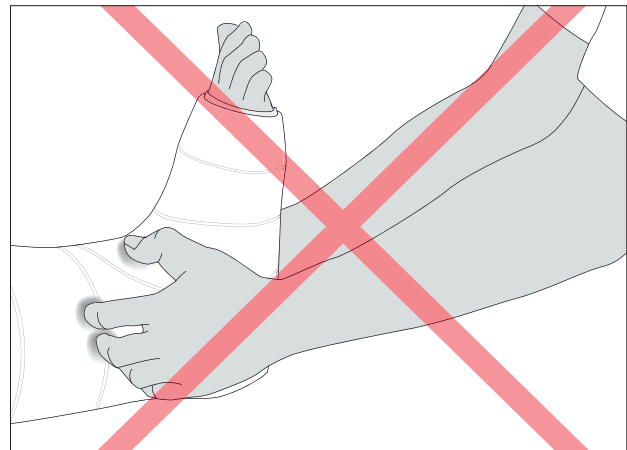
Open wedging alone can distract the fracture fragments: in a transverse fracture, this can contribute to impairment of union.





13.3 To be avoided

- Manipulation without traction
- Failure to assess inappropriate pain
- Failure to loosen cast with increasing pain, or suspected compartment syndrome
- No elevation after POP application
- Covering POP before it dries
- Creating indentations with fingertips (as illustrated)
- Failure to pad over bony prominences
- Pressure on common peroneal nerve (lateral fibular neck) or fibular head.
- Application of a thinly padded cast before swelling has ceased



14 Aftercare

14.1 General guidelines

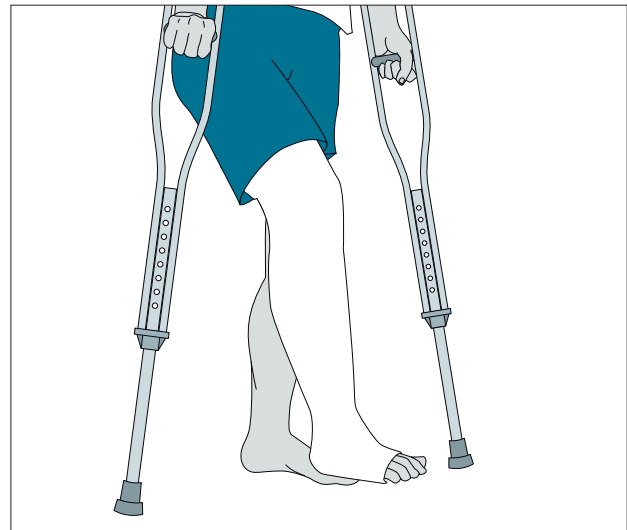
Analgesics should be prescribed for 4 to 6 weeks.

If a plaster cast becomes loose, it should be removed and replaced with a new one, preferably waiting until the fracture has become sticky enough (+/- 4 weeks) to avoid losing the reduction during the replacement procedure.

Non weight bearing should be maintained for 2-4 weeks depending on the fracture type.

Then graduated partial weight bearing should be started and increased to full weight bearing by about 6 weeks. Weight bearing requires protection of the cast bottom with a cast shoe, oversized sneaker, or equivalent.

Tibial shaft fractures usually take between 3 and 5 months for complete healing. If the foot is in a functional position, graduated partial weight bearing can begin as soon as possible comfort and presumed fracture stability permit.

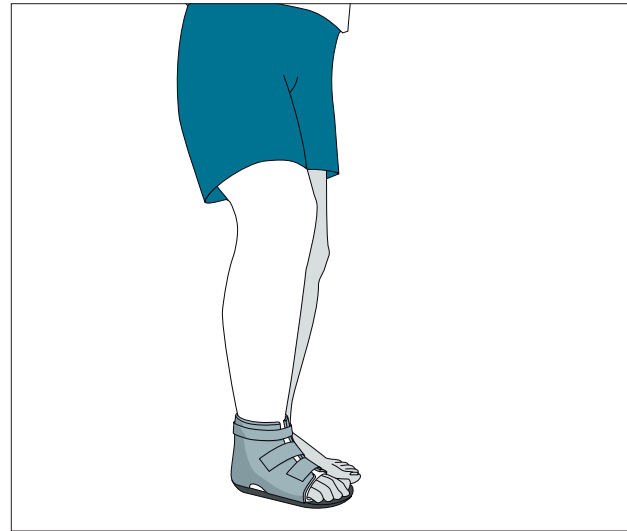


Caution: For unstable fractures or fractures involving the knee or ankle joint, weight bearing should be delayed until healing is further advanced.

The plaster cast should not be removed until the fracture is stably healed. This is usually indicated by patient's ability to bear full weight in the cast without pain. For tibial shaft fractures, this will rarely occur before 14 weeks after injury. Displaced fractures or fractures due to high energy forces usually take longer to heal. It is usually necessary to replace the first cast before the fracture is healed sufficiently. Check stability carefully when definitive removal is done. Sometimes alignment that initially feels stable will be lost during the first week or two after cast removal. It is wise to check the patient within a couple weeks to avoid missing such delayed deformity until it is very hard to correct.

After removal of the cast, and confirmation of a stable nontender fracture, rehabilitation should involve dedicated knee and ankle mobilization for a prolonged period. Even if fully weight bearing before cast removal, the patient may need crutches and partial weight bearing for a period after cast removal.

At this stage, it may be advisable to give an anti-inflammatory for four weeks.

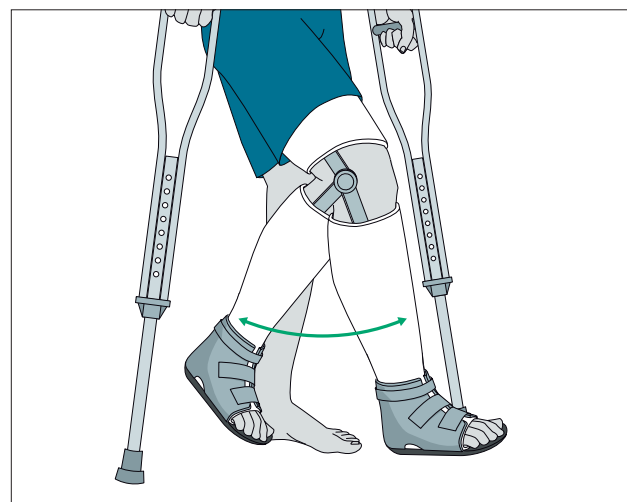
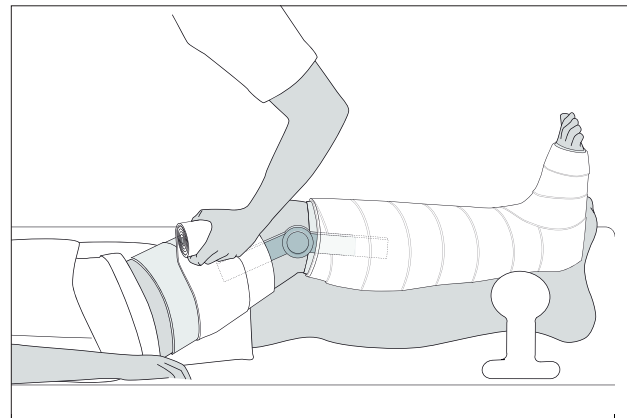


15 Alternative cast for weight bearing

15.1 Hinged knee cast-brace

For proximal tibial fractures, the knee may be mobilized with the aid of a hinged cast, this is applied when the fracture is sufficiently consolidated (typically after 6 weeks). The hinged cast involves two parts as shown. A fresh cast has to be applied below the knee as well as above. The lever arms of the hinge are incorporated in the plaster cuffs above and below the knee. Great care needs to be taken to align the axis of the hinge with that of the knee joint. Remember that the knee axis is actually proximal to the joint line, roughly at the level of the femoral epicondyles, and that it is perpendicular to the knee's arc of motion.

This cast-brace, a form of functional bracing, allows mobilization of the knee joint before the fracture is completely healed. It provides continued protection of the healing fracture, as well as progressive partial weight bearing, at the discretion of the treating surgeon. Where materials are available, such functional braces can be made of fiberglass or appropriate thermoplastics. If mobilization of the ankle is desired, a hinged foot support can be used to replace the foot portion of the cast.

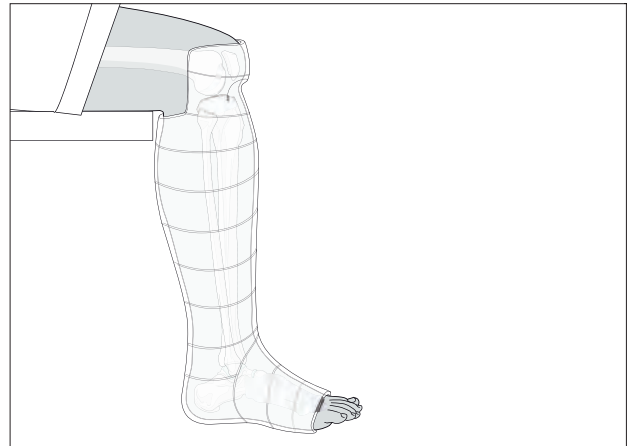




16 Sarmiento's Patellar tendon-bearing cast

In mid shaft and more distal tibial fractures, a patellar tendon-bearing (PTB) cast, as described by Sarmiento, can be applied. For more stable fractures, this cast may even be applied earlier than 6 weeks. For undisplaced tibia shaft fractures without significant swelling it might even be used as the initial cast.

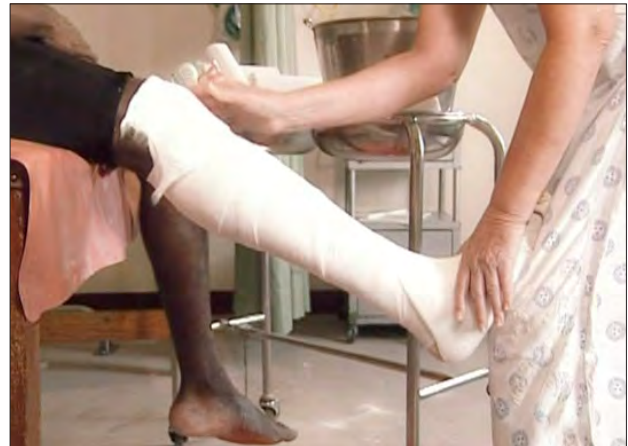The application of such a cast requires considerable experience, especially the molding in the infrapatellar region.



16.1 Application of the Sarmiento cast

Where materials are available, the cast can be made of fiberglass or thermoplastic material. Additionally a hinged foot support can be used to replace the cast around the ankle and foot, permitting also mobilization of the ankle.

The patient sits on the edge of a table. The lower leg is steadied and a stocking and padding are applied to above the knee. All bony prominences are protected by extra padding.



The POP is applied to above the knee and then later trimmed to above the patella in front and below the popliteal fossa at the back.





16.2 Molding of the Sarmiento cast

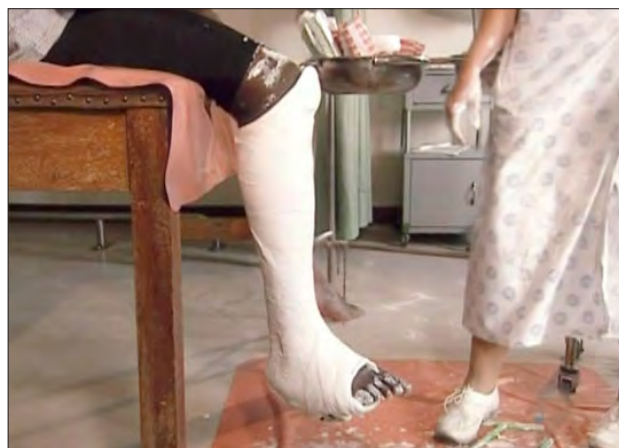Before setting, the plaster is molded to fit the contours of the proximal tibia and fibula, not only around the tibial tubercle and patellar tendon, but also the fibular head, peroneal nerve, and posterior proximal calf. The cast should be triangular in cross section, flat posteriorly, and molded to match the prominent tibial tubercle. This molding forces the cast away from the fibular head and peroneal nerve, helping to avoid local pressure.



16.3 Trimming of the Sarmiento cast

Once firm, the proximal margin of the cast is trimmed from the proximal pole of the patella, circumferentially to the proximal part of the calf. Note that the posterior trim line is thus more distal than the anterior edge of the cast, since it must be just below the popliteal flexion crease.

Check that knee extension is full, and that the knee can flex to 90 degrees. Then cast edges are padded by turning down the padding and stocking, to provide cushioning. The stocking is then secured to the outside of the cast with a little additional plaster.



16.4 Weight bearing

Once the plaster is fully hardened (24-48 hours), a cast shoe may be applied and weight bearing and knee flexion started. The cast is retained until union is sound, and

the patient can comfortably bear full weight.

Gait training in a PTB cast is essential to ensure full knee extension, which is necessary for optimal fracture stability in this cast.





4 Tibial and malleolar fractures

4.13 I Distal tibial fractures – Treatment with a cast

Indication **43-A, 43-B, and 43-C1 type fractures**

1 General considerations

Definitive nonoperative treatment with a cast is only exceptionally indicated for distal tibia fractures. The nonoperative treatment may, however, be adequate in non- or minimally displaced fractures that are stable. Exceptionally, high surgical risk may be an indication

for nonoperative treatment in additional fracture types. Stabilizing the fracture in a cast may be used for the initial management until soft-tissue situation allows ORIF. In highly unstable fractures, the cast may be inadequate in order to maintain reduction and correct shortening. Those fractures will preferably be stabilized with an external fixator.

2 Indications for a lower leg cast as definitive treatment

2.1 Indication

Indication

- Nondisplaced or minimally displaced fractures with intact soft tissues
- Fractures with acceptable reduction:
Joint surface: <1 mm intraarticular step and <2 mm intraarticular gap.
Axial alignment: <5 degrees of varus or valgus and <10 degrees of anterior or posterior angulation.
Fibular length and width of syndesmosis: <2 mm difference to the opposite, uninjured side

Contraindication

- Open soft-tissue damage
- Severe closed soft-tissue damage
- Incongruence of the articular surface ≥ 2 mm

Advantages

- No operative and no anesthesia risk



Disadvantages

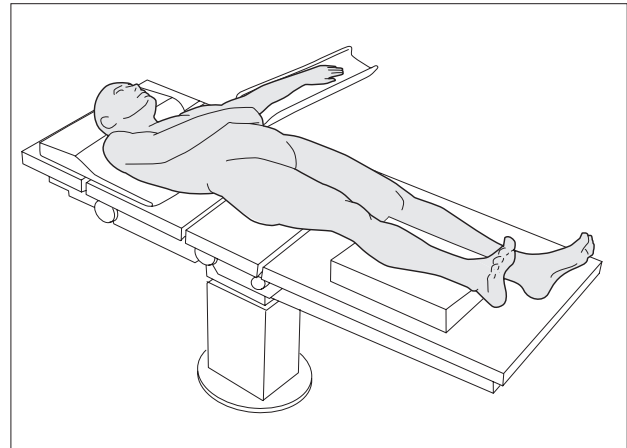
- Inability to monitor soft tissues
- Risk of joint stiffness
- Muscle atrophy
- Risk of thrombosis
- Secondary displacement possible



3 Reduction

3.1 Positioning

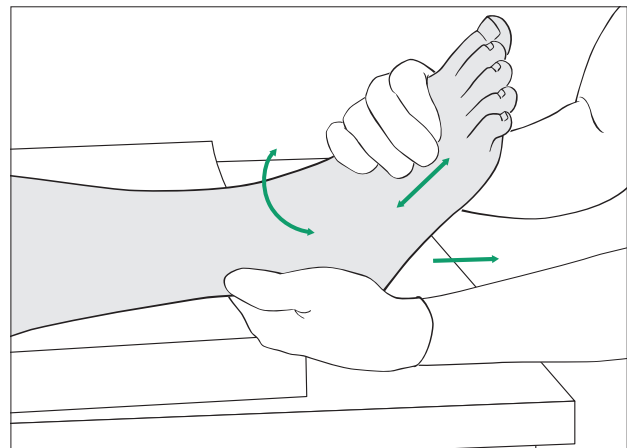
In undisplaced fractures reduction is not necessary. Displaced fractures should be reduced as soon as possible with anesthesia as necessary. The lower leg should be positioned on a pillow so that the heel is slightly elevated from the table.



3.2 Manual reduction

Hold the foot around its middle from plantar and medial. Grasp the heel with the other hand. Reduction is achieved by gentle traction and by alignment of the foot to match the axis of the lower leg, also correcting rotation.

Note: After reduction, reconfirm presence of palpable pedal pulses.



4 Cast application

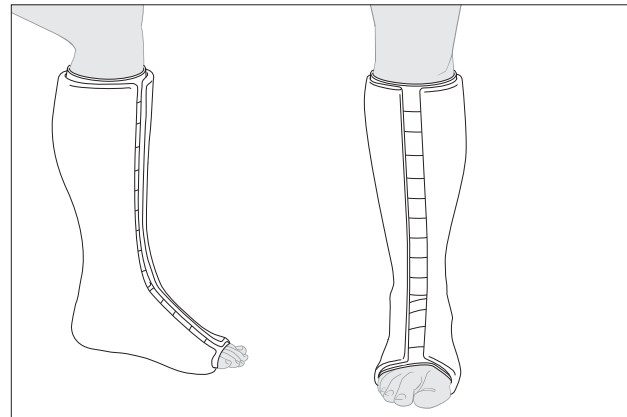
4.1 Principles

Once the fracture has been reduced satisfactorily, reduction must be maintained during cast application by gentle manual and/or gravity traction.

Apply abundant cast padding. This should not be too tight, but may include very gentle compression.

Progressive local soft-tissue swelling must be expected during the first days after injury. Therefore, a closed circular cast is usually contraindicated. The cast may be split and spread anteriorly, or «bivalved» with medial and lateral cuts. Make sure that the splitting provides room for swelling, that the padding is not too tight, and that all bony prominences are decompressed.

Plaster of Paris or fiberglass cast tape can be used. With plaster, the cast must be allowed to harden before splitting is possible.



Be aware that a compartment syndrome can occur even after a cast is split. Make sure the split cast is sufficiently stable to support the fracture.

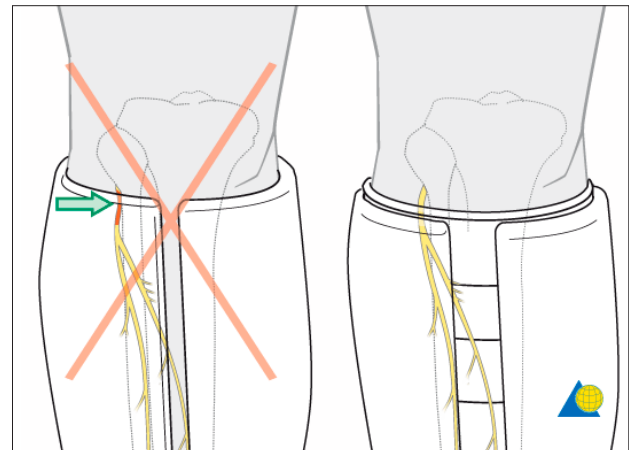




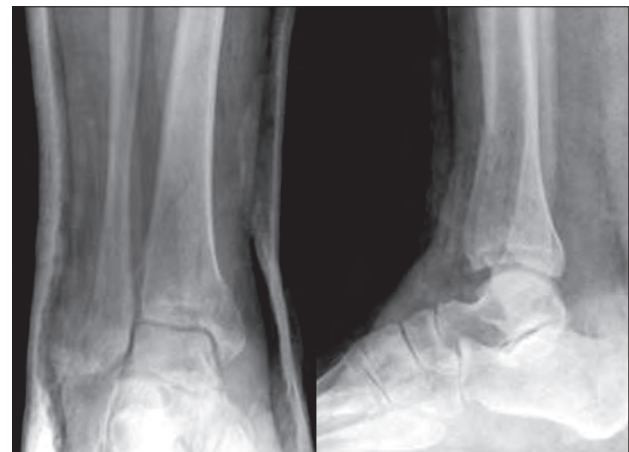
4 Cast application

4.1 Landmarks for cast application and the importance of adequate padding

Proximally, the edge of the cast lies distal to the popliteal fossa. An easy landmark is 3-4 fingerbreadths below the popliteal crease. All toes should be visible dorsally. The common peroneal nerve, superficial to the proximal fibula, may be compressed by the top of a below-knee cast. Adequate padding, and cast molding (posterior flattening and apex anterior angle) help to minimize this risk.



Note: After application of the cast, the fracture alignment should be documented radiologically.



5 Aftercare (nonoperative treatment with a cast)

Follow-up x-rays at 3, 7, and 14 days will detect early loss of reduction in cases where final nonoperative treatment is planned. In case of secondary displacement, remanipulation is possible but the fracture situation usually requires additional stability by internal or external fixation.

In cases that are scheduled for final nonoperative treatment, the split cast is changed for a circular cast after

1 - 2 weeks dependent upon the local soft-tissue situation. The circular cast is worn for another 4 - 5 weeks.

Weight bearing is not allowed during the period of cast immobilization.

After 6 weeks, progressive weight bearing is initiated over a period of 4 - 6 weeks. Thrombosis prophylaxis is necessary until full weight bearing is achieved.



4 Tibial and malleolar fractures

4.13 II Distal tibial fractures – Traction as initial provisional stabilization

Indication **All 43-A, 43-B, and 43-C type fractures**

1 General considerations

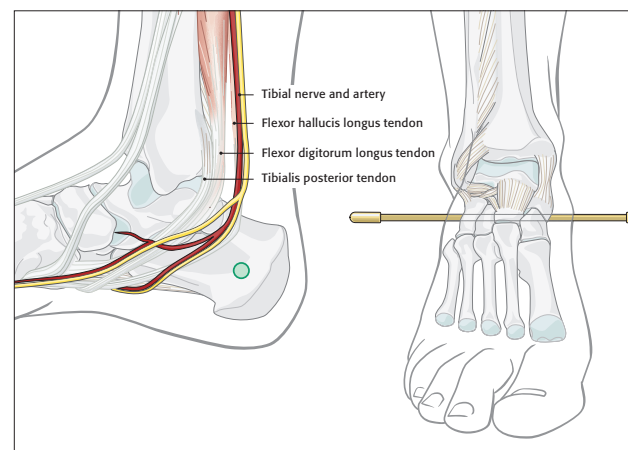
Traction is an option for initial treatment of unstable, displaced distal tibial fractures, especially in fractures with Tscherne grade I and II closed soft-tissue damage. Remember that external fixation is more stable than traction. It also simplifies nursing care.

Traction is contraindicated for open fractures and those with acute or impending compartment syndrome. Note that swelling may increase with traction because stability is suboptimal.

Except where surgical treatment is not available, traction is inappropriate for definitive treatment of distal tibial fractures. This is because it requires prolonged bed rest and may not achieve an adequate reduction.

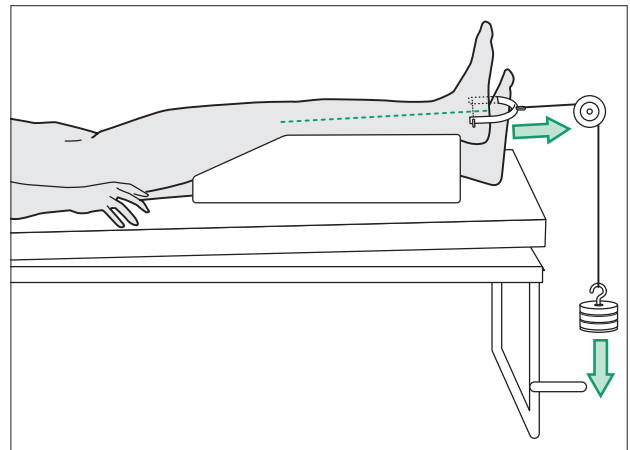
2 Application of traction

Insert a 4 mm Steinmann pin, centrally threaded if available, from medial to lateral through the calcaneal tuberosity. It is vital to avoid the posterior tibial neurovascular bundle behind the medial malleolus. A 2 mm K-wire may also be used, but it will require a tensioning clamp. If swelling permits, locate the posterior tibial pulse: if this is not palpable with certainty, examine the pulse of the uninjured leg and use its position as a guide to the probable path of the bundle at the injured side.





Subsequently, the fracture is aligned and reduction is maintained by applying 3-5 kg traction through an appropriate clamp on the pin or K-wire. Mild to moderate elevation of the injured limb helps control swelling. Adequate padding under the calf, to avoid heel pressure, is necessary to avoid skin breakdown. Traction should not be maintained longer than necessary, ie, until local soft-tissue situation permits definitive treatment. Check frequently for skin pressure from supporting frame or pin/wire clamp.



3 Aftercare

Apply dressings as needed. Pin-site care is provided according to the surgeon's routine.

Note: Watch for pin-site infection. If infection occurs, and definitive internal fixation is not yet possible, pins have to be replaced using new insertion points in a safe distance to the infected pin track. Pin-track infections may compromise definitive surgical treatment.





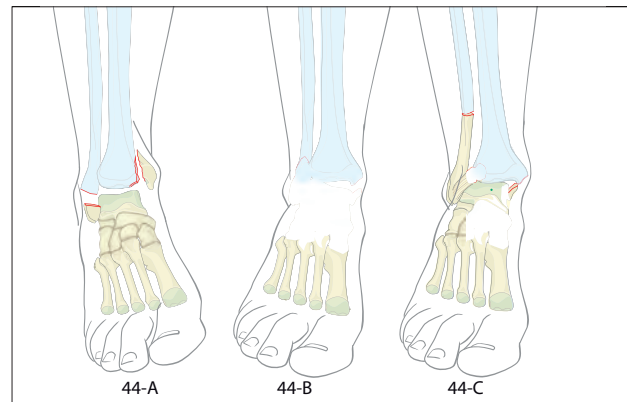
4 Tibial and malleolar fractures

4.14 I Malleolar fractures – Management with limited resources

Indication **All malleolar fractures**

1 General considerations

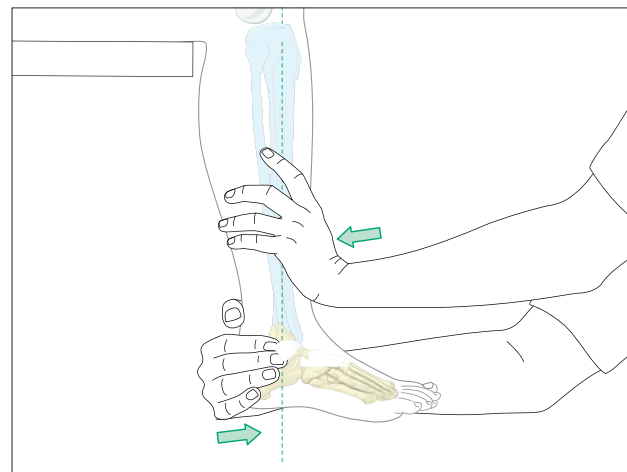
This description of nonoperative treatment considers all three types of malleolar injuries (44-A, 44-B and 44-C).



1.1 Preliminary remarks

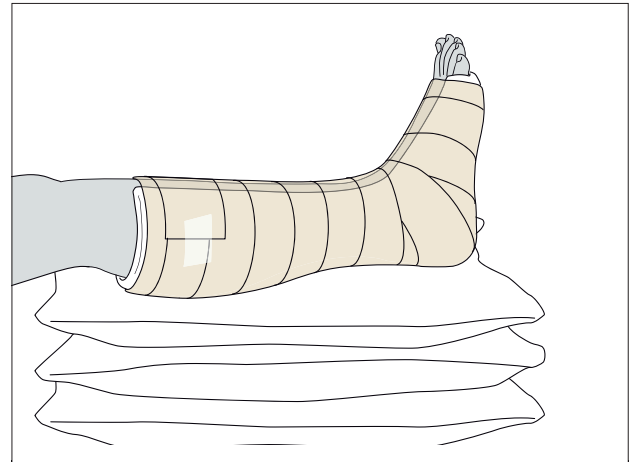
Nonoperative treatment of ankle fractures is usually only indicated for undisplaced, stable fractures. However, if the facilities and the skill for safe operative treatment are not available, nonoperative treatment is safer, and if performed correctly and skillfully, it can lead to acceptable results.

In any situation, a displaced ankle fracture should be reduced as soon as possible, even if surgery is planned for the near future.

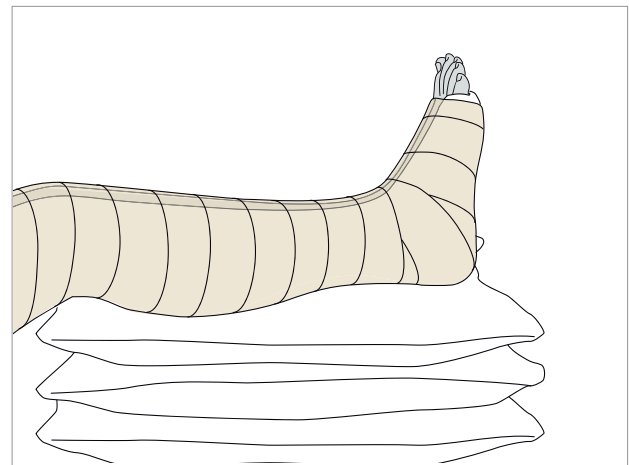




In the case of severe swelling, the provisionally reduced ankle fracture should be immobilized temporarily with a plaster of Paris (POP) back-slab, and elevated on several pillows.



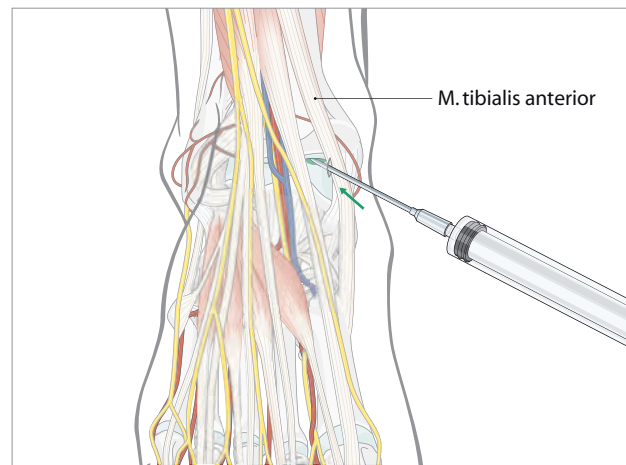
If the injury is of the rotational type, and unstable, an above-knee back-slab will be more comfortable.



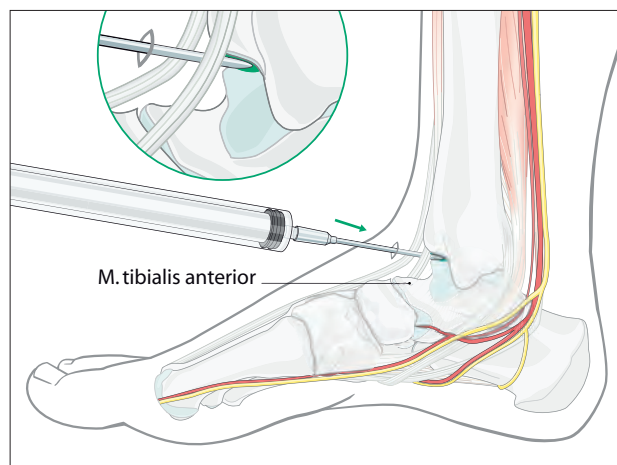
1.2 Anesthesia

In the absence of the facility for general anaesthesia, reduction can be achieved under sedation (e.g., Pethidine plus Diazepam), and/or intraarticular local anaesthesia (Lignocaine 2% 15ml).

In the case of severe swelling, the reduced ankle fracture should be immobilized temporarily with a plaster of Paris (POP) back-slab, and elevated on several pillows.

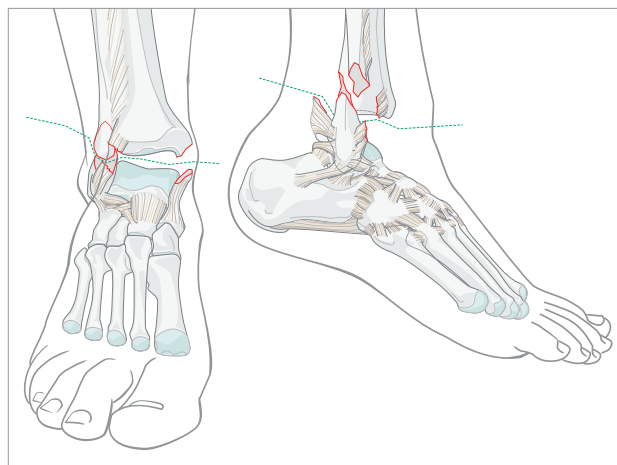


The intraarticular injection of local anaesthetic is introduced anteromedially, between the tendons of tibialis anterior and extensor hallucis longus, medial to the anterior tibial neurovascular bundle.



1.3 Typical displacement in ankle fractures

The stated mechanism of injury, the history and the clinical appearance of the foot and ankle offer hints to the clinical diagnosis.

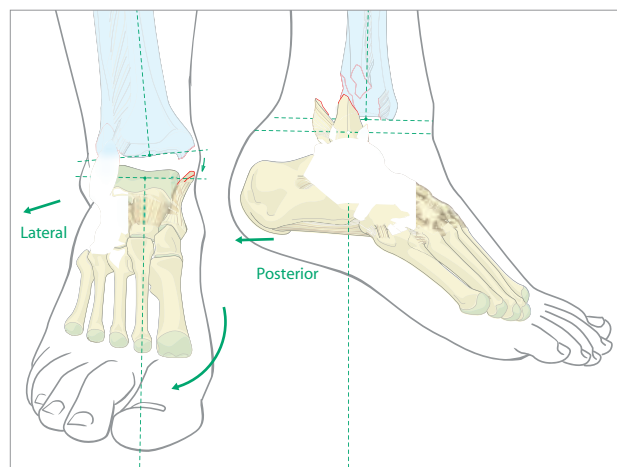


The typical displacement in most ankle fractures is posterior and lateral, usually with the foot externally rotated (types 44-B and 44-C). In the type A fractures, the displacement is medial.

Careful review of the x-ray images is essential for a full understanding of the mechanism of injury.

Regard the injury as a two-part fracture between the lower leg (tibia and fibula) proximally, and the foot distally. The task will be to get the foot into correct alignment with the leg.

If x-rays are not available, it is safer to correct the deformity clinically, rather than to leave it unreduced.



2 Reduction of displaced ankle fractures

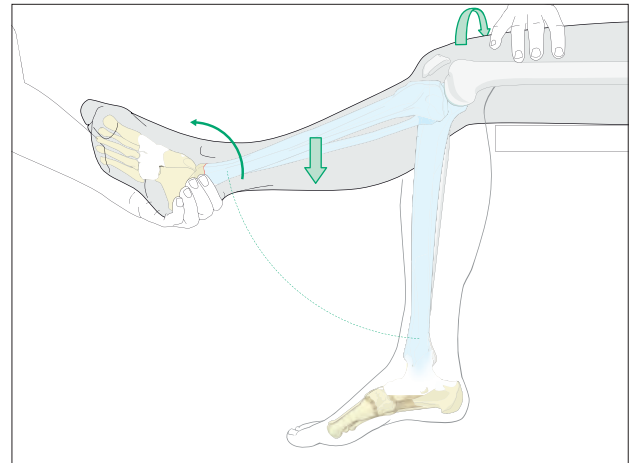
2.1 Treatment of patients presenting early

The aim of any reduction (early or late) is to correct the displacements.

Treat the patient on the day of injury, when the deformity is typical, late swelling has not yet appeared and adequate anaesthesia can be administered.

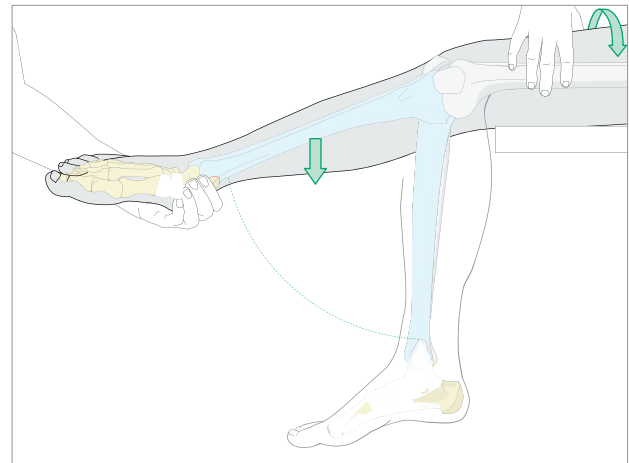
Use gravity to help to reduce the fracture.

The patient lies supine on the table, with the lower leg hanging over the end of the table. For laterally displaced and externally rotated injuries (types 44-B and 44-C), hold the heel of the injured foot as shown and lift the externally rotated leg. In this procedure the weight of the leg will, in most cases, reduce the posterior and the lateral displacement automatically. Further pressure against medial or lateral malleoli is usually unnecessary.



For medially displaced injuries (types 44-A), the reduction procedure involves holding the heel of the foot with the leg internally rotated, so that gravity tends to relocate the foot in a lateral direction.

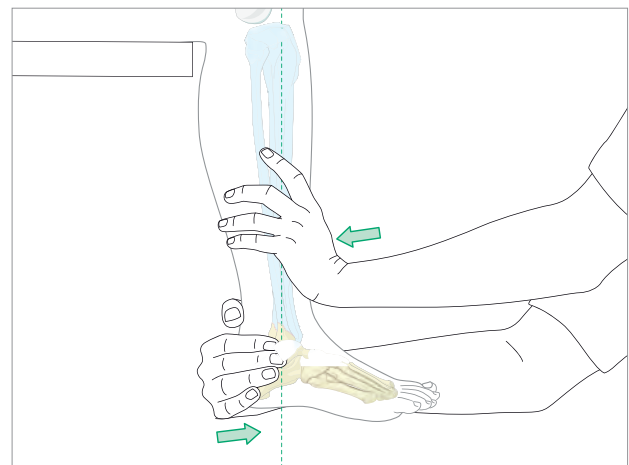
Detailed reduction will be considered later.



2.2 Treatment of patients presenting late

If the patient presents late and you have no possibility to administer general anaesthesia, so that the patient is not fully relaxed, but merely sedated, or has only local intraarticular analgesia, reduction will not be achieved by gravity alone.

Manual reduction is performed on the hanging leg, with the knee flexed to reduce the pull of the Achilles tendon.

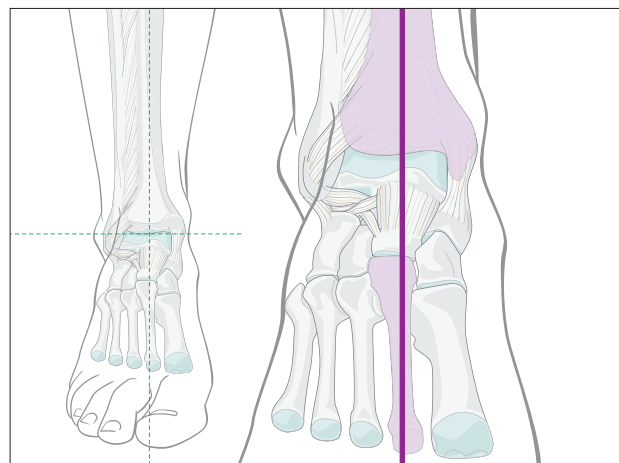




2.3 Correct alignment

The aim is to bring the foot into correct alignment with the lower leg.

Without x-rays, this is the only alignment reference available.



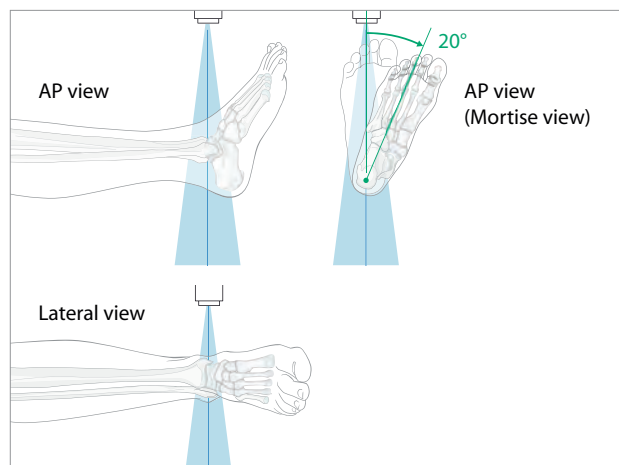
2.4 X-rays

For the choice of the correct reduction technique, it is useful to differentiate three patterns of fracture morphology.

This differentiation can only be made if x-rays are available.

Three radiographic views are taken:

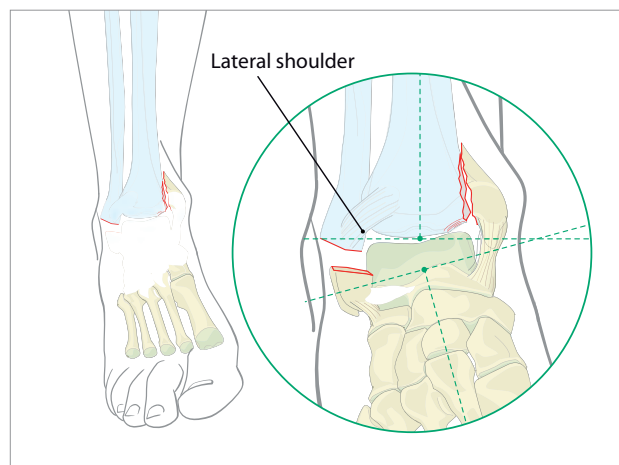
- Anterior-posterior (AP) view
- AP in 20 degrees of internal rotation (mortise view)
- Lateral view



2.5 Patterns of fracture morphology

Pattern 1) Lateral fibular buttress (44-A, adduction mechanism of injury)

The medial malleolus has been pushed off by the adducting talus. The traction fracture of the lateral malleolus, or the osseo-ligamentous injury, has left a lateral fibular buttress.

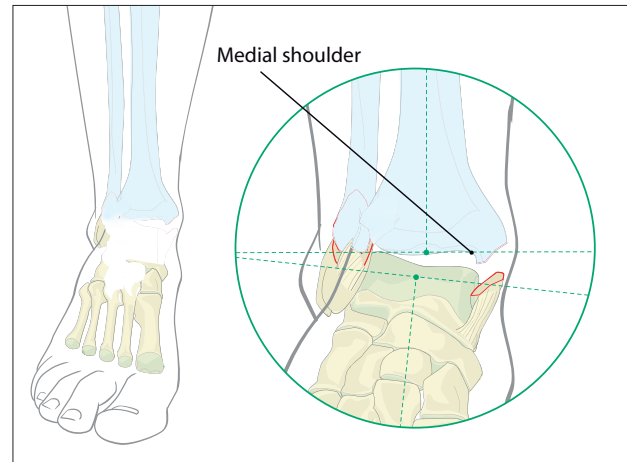


Pattern 2) Those with a medial shoulder (some 44-B, 44-C, external rotation mechanisms of injury)

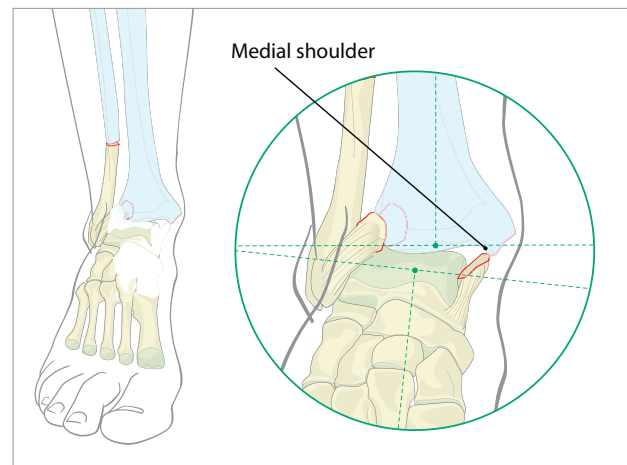
The fracture of the medial malleolus has left a shoulder (or beak) on the tibia.

Many displaced ankle injuries fall into this pattern.

The illustration shows a 44-B Type.



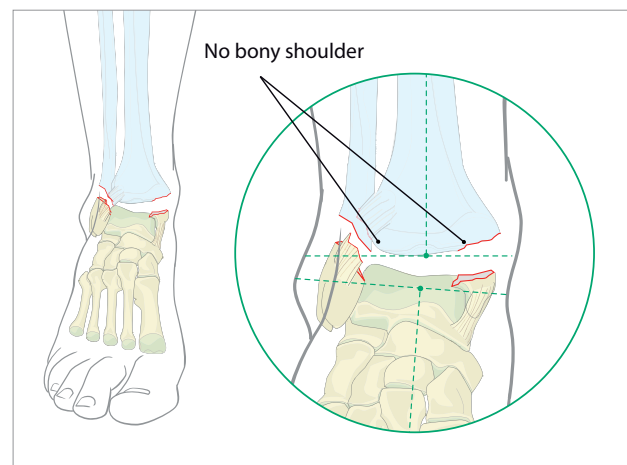
The illustration shows a 44-C Type.

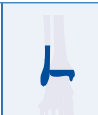

Pattern 3) Combined fractures of the lateral and medial malleoli without medial or lateral shoulder (some 44-B, 44-C, external rotation mechanisms of injury)

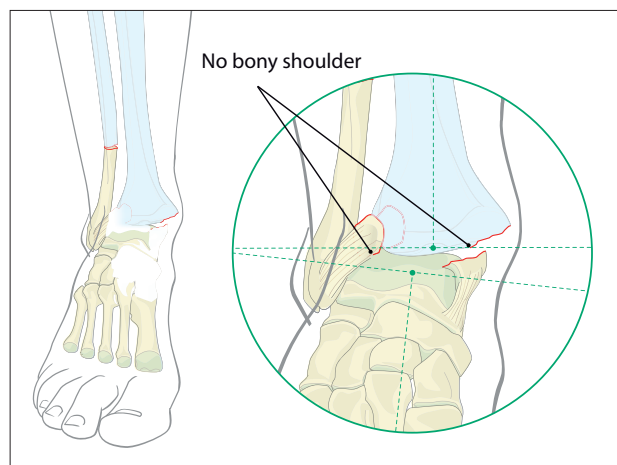
Both medial and lateral fractures are flush with, or above, the joint level, not leaving any medial or lateral bony shoulder against which to reduce the talus.

The illustration shows a 44-B Type.



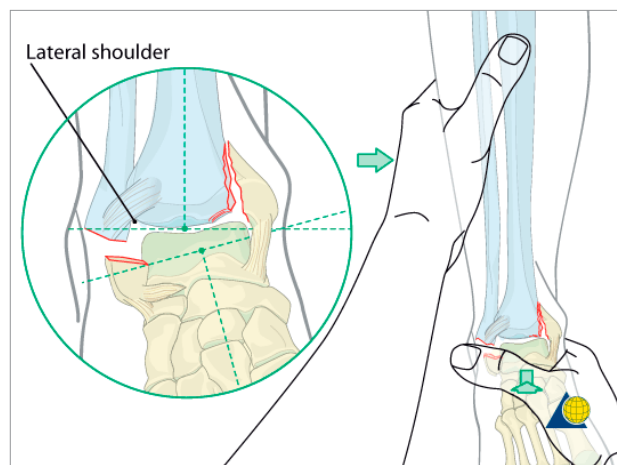


The illustration shows a 44-C Type.

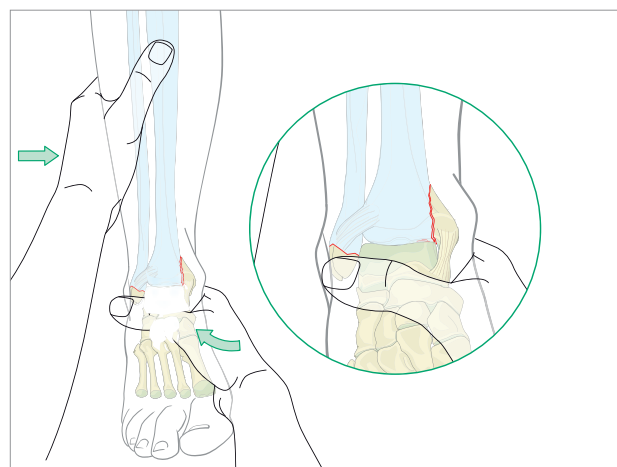


2.6 Reduction of pattern 1: Fracture with a lateral fibular buttress

Firstly, any AP displacement is corrected.
Hold the hindfoot firmly and gently pull both distally and forwards to correct any posterior displacement.



The heel then needs to be pressed upwards and laterally, buttressing the talus against the shoulder of the lateral malleolus.

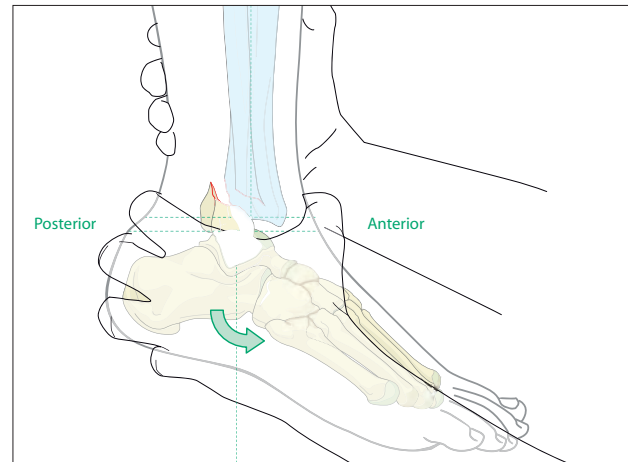




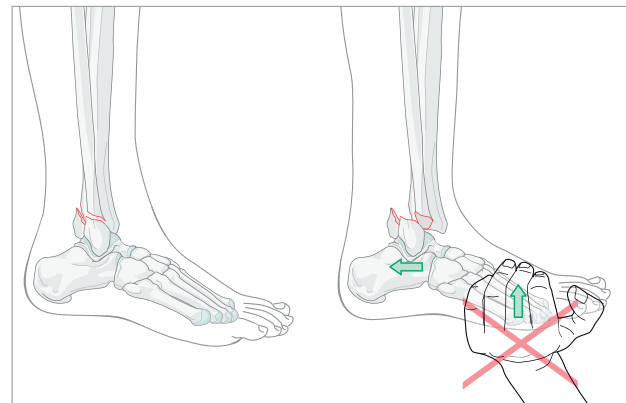
Reduction of pattern 2: Fracture with medial shoulder present

Firstly, any AP displacement is corrected. Hold the hind-foot firmly and pull both distally and forwards to correct any posterior displacement.

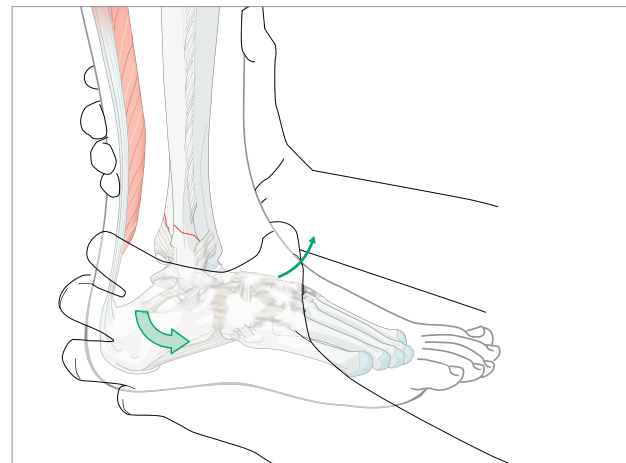
At the same time, any external rotation displacement is reduced.

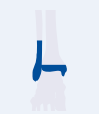

Avoid pushing the forefoot into dorsiflexion, as this tends to displace the talus posteriorly in the mortise. This is especially important when the fracture complex includes a posterior tibial marginal fracture (Volkman's fragment).

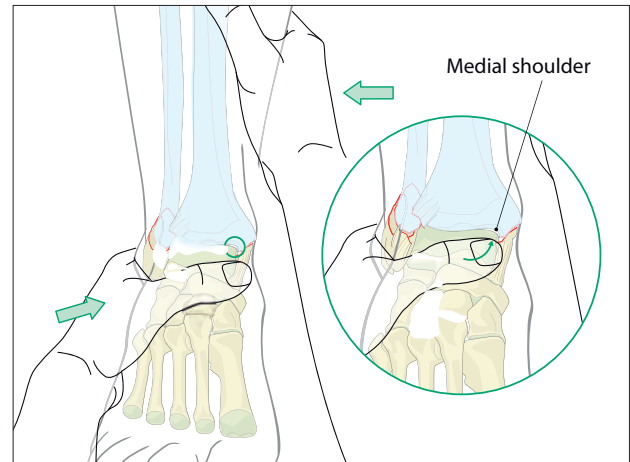


A plantigrade position of the foot is important, but needs to be achieved by manipulation of the hindfoot downwards and forwards, rather than pushing upwards on the forefoot.

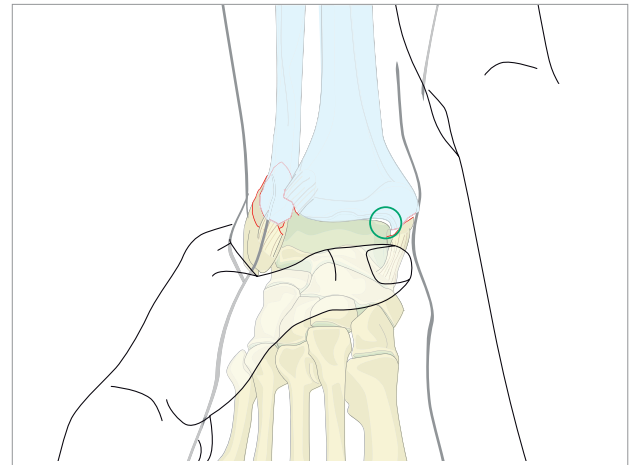




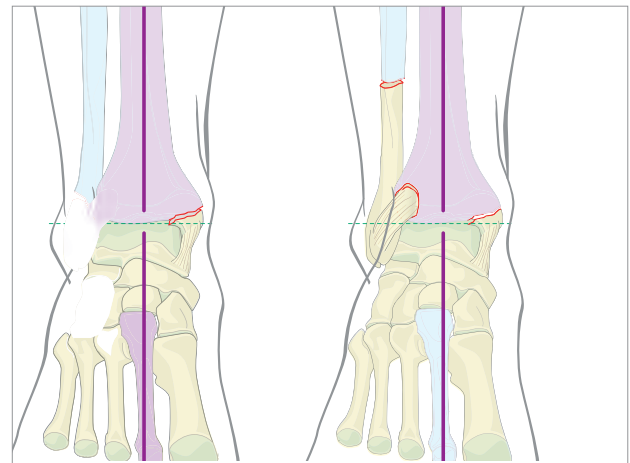
The lateral displacement is then corrected by pushing the mid - and hindfoot (heel) from lateral to medial against the counterpressure of the other hand on the lower end of the tibia as shown. This presses the talus against the medial shoulder. At the same time any external rotation deformity is corrected.



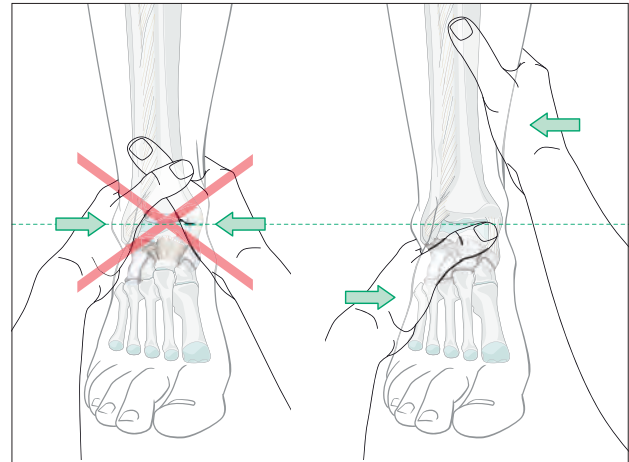
By exploiting the resistance of the medial shoulder, over-reduction is avoided.



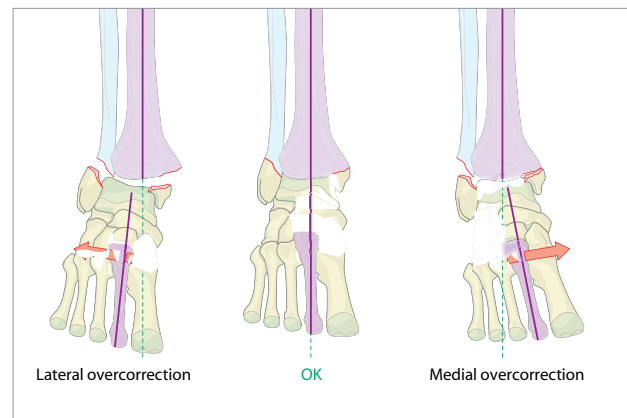
Reduction of pattern 3: Reduction of combined fractures of the lateral and medial malleoli without medial or lateral shoulder



Reduction pressure needs to be applied above (lower leg) and below (heel and midfoot) the malleoli, not directly over the malleoli.



Here, the danger is of overcorrection of the ankle medially, or laterally. In such cases, the AP displacement is corrected and the foot orientated in alignment with the lower leg, avoiding any undue medial or lateral pressure, and correcting any malrotation. It is only the soft tissues and surgical acumen that help to prevent overcorrection.

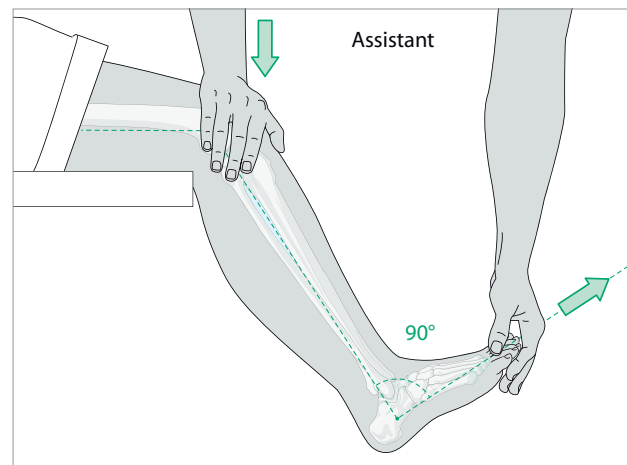


3 Holding the reduced position

3.1 With an assistant:

The assistant stands on the medial side of the injured leg and maintains some flexion of the knee and the right angle position of the ankle, pressing gently on the knee and holding the big toe forwards in line with the patella. This usually holds the reduction that has been achieved and allows the operator to apply the padding and the plaster cast.

Tip: Avoid strong dorsiflexion of the foot as this can cause posterior displacement of the talus, as previously discussed under reduction of displaced ankle fractures.



3.2 Without an assistant:

Apply the plaster padding.
Now, apply around the ankle one roll of POP (dipped in cold water to give more time until hardening), reduce

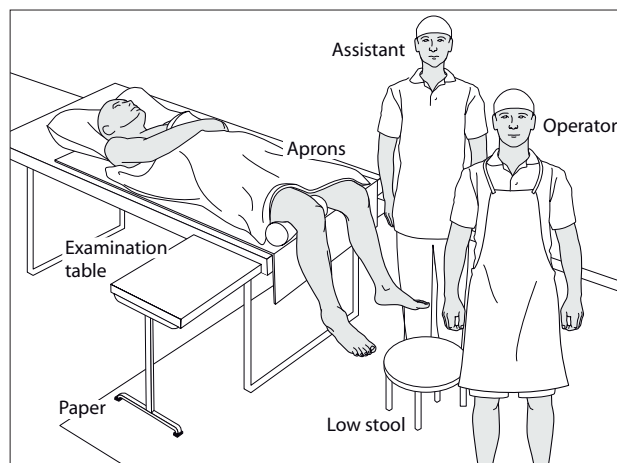
the fracture and maintain it reduced until the POP skin is hard enough to hold the reduction.
Then complete the cast.



4 Preparation for cast application

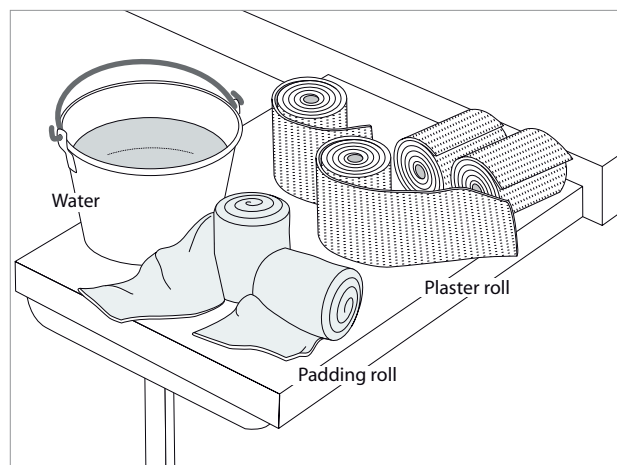
4.1 Two person team

- Operator and assistant



4.2 Materials (prepared before the procedure)

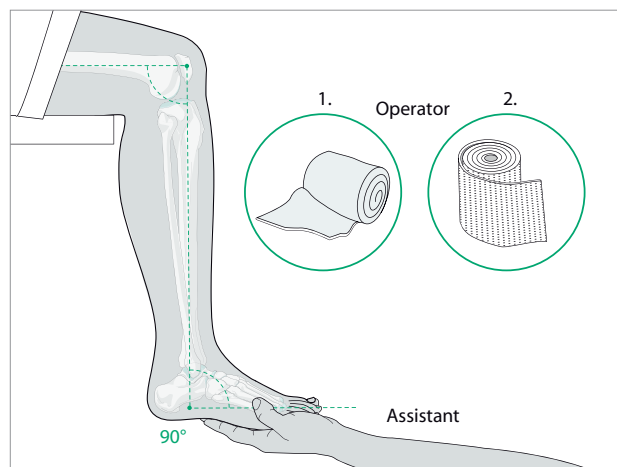
- 2 rolls 100 mm padding
- 4 plaster of Paris rolls, 100 mm wide (8 – 9 for an above-knee cast – patterns 2 and 3)
- Bucket with cold, or lukewarm, water
- Low stool
- Examination couch, or table
- Aprons to protect team members and patient
- Paper to cover the floor



5 Application of below-knee cast

5.1 Positioning in undisplaced fractures

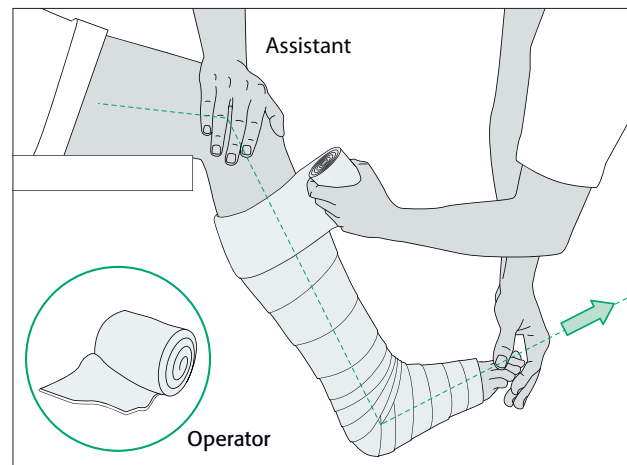
In undisplaced fractures, reduction is not necessary. The plaster cast will be applied on the hanging leg (knee flexed to 90 degrees and ankle held at 90 degrees).



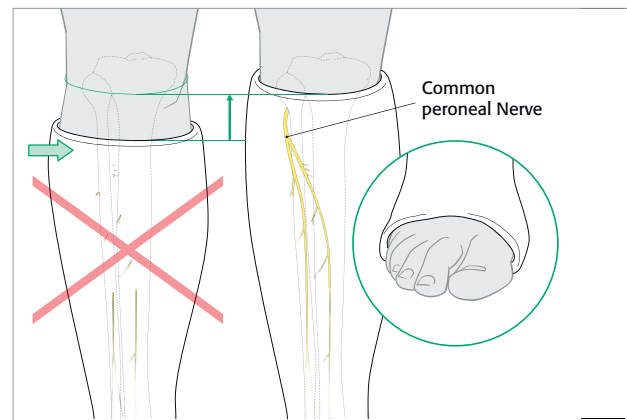


5.2 Application of the padding

First, apply the padding. This needs to be thicker over the malleoli and around the fibular head.

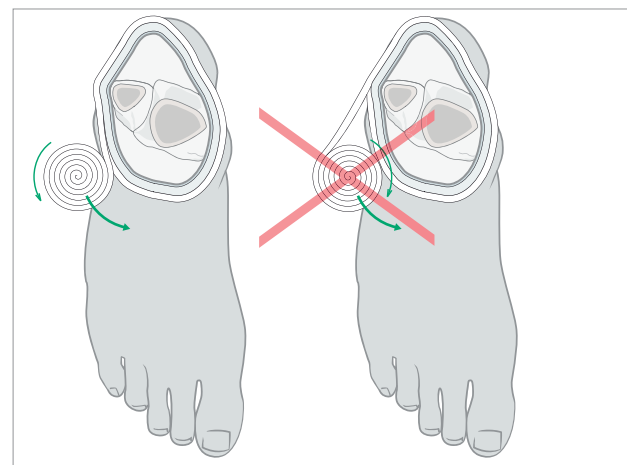


The cast should reach from the MTP joints of the toes to just below the knee joint, avoiding the upper end of the plaster's being at the level of the neck of the fibula, where the common peroneal nerve crosses.



5.3 Handling of plaster bandages

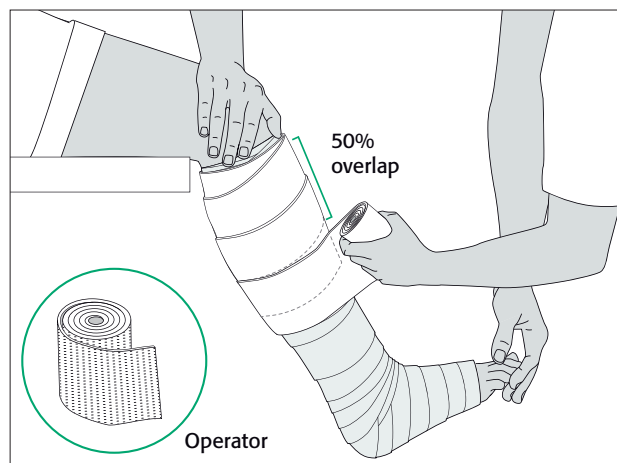
It is important to hold the plaster rolls correctly during application, so that they can be rolled on, rather than pulled on.





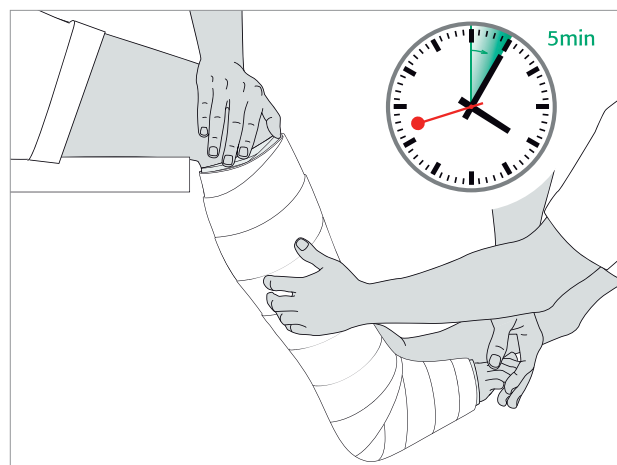
5.4 Application of plaster bandages

It is easier to start proximally, overlapping by half the width of the roll and moving down the lower leg to around the ankle and foot.



After the application of the second roll, whilst the plaster is still soft, final manipulation is done and the reduction held, with appropriate molding, until the plaster hardens. This may take 4 to 5 minutes, depending on the temperature of the water – colder water gives you more time.

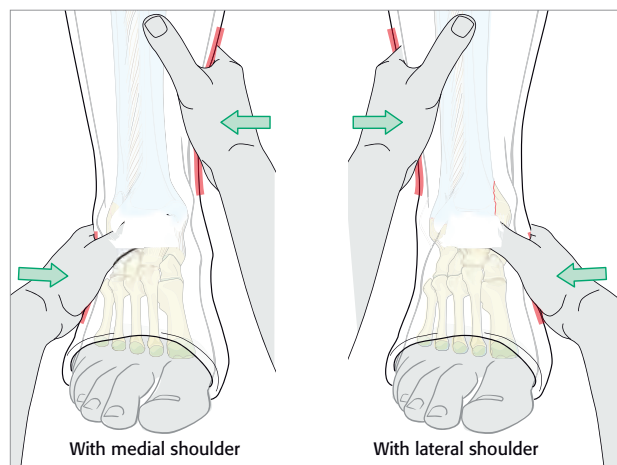
The final two rolls are then applied and further moulding is performed to achieve the desired 3-point fixation.



5.5 Moulding of the cast: 3-point cast fixation

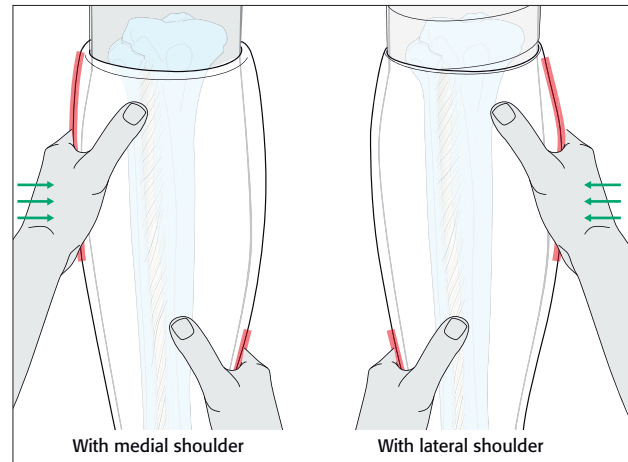
When moulding the cast, the same action as for reduction is repeated and held until the plaster is firm.

The principle of 3-point fixation within the cast needs to be applied. The two main moulding points are created by gentle pressure below the buttressing malleolus and above over the opposite supramalleolar part of the lower leg.





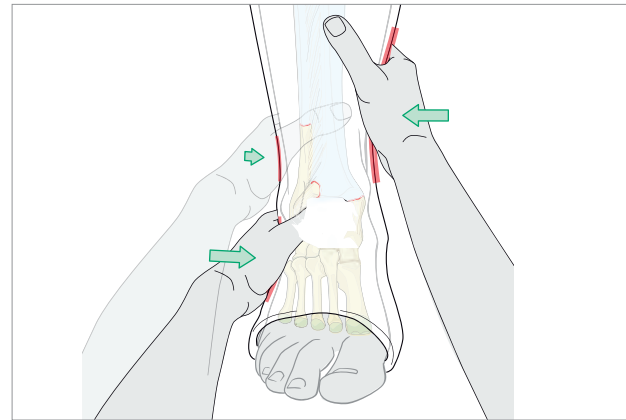
The third point is created later by moulding the upper end of the cast firmly around the leg, on the aspect of the leg opposite to the supramalleolar moulding.



5.6 Suprasyndesmotic fracture (44-C)

In suprasyndesmotic fractures, with disruption of the syndesmosis, firm moulding around and even over the lateral malleolus helps to close the diastasis and allows the syndesmosis to heal.

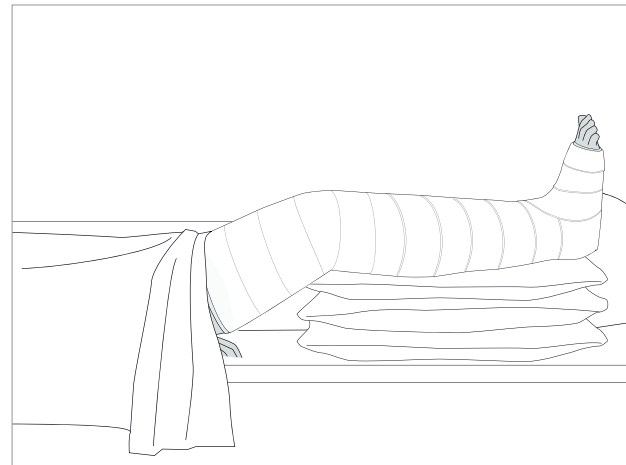
These fractures will require extension to an above-knee cast as discussed shortly.



6 Application of above-knee cast

In those fractures with an external rotation component, the reduction will be held better with an above-knee cast for the first 4-6 weeks (patterns 2 and 3).

Thereafter, a below-knee cast can be applied for the remaining period of casting, as determined by the surgical decision-maker.



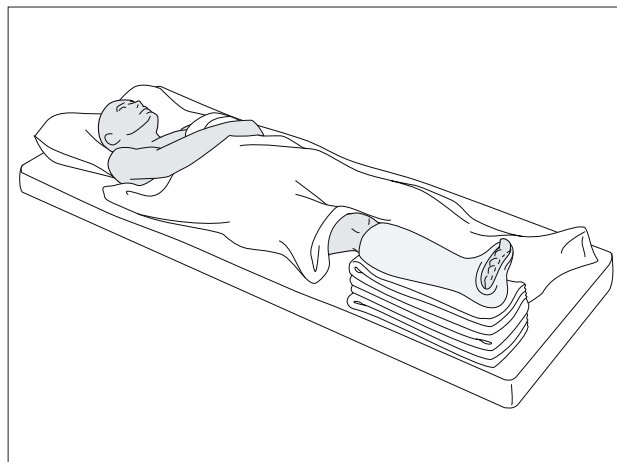
7 Evaporation period

The patient should be warned that the leg in the plaster will feel cool and moist. This is due to the evaporation of water from the plaster. Once the cast is dry, the moist, cold feeling will disappear.

During the evaporation period, the casted limb should remain exposed and not fully covered by blankets.

Any plaster, especially one without adequate padding, carries a risk of causing obstruction of circulation and compartment syndrome.

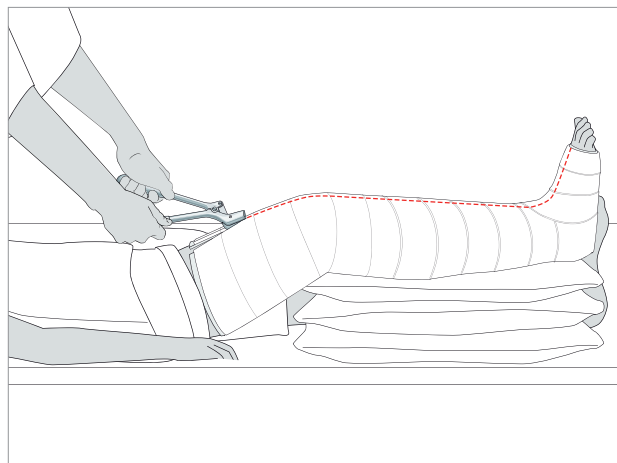
Tip: Remember that the plaster requires over 24 hours to gain full strength.



7.1 Compartment syndrome

In case of inappropriate pain, especially on passive dorsiflexion or plantarflexion of the toes, the plaster and padding should be split immediately down to skin, over its whole length, and the leg watched carefully for rapid recovery. It is better to lose the reduction than to risk muscle necrosis.

If the slightest suspicion of compartment syndrome remains, the plaster needs to be removed and urgent dermatofasciotomy considered.



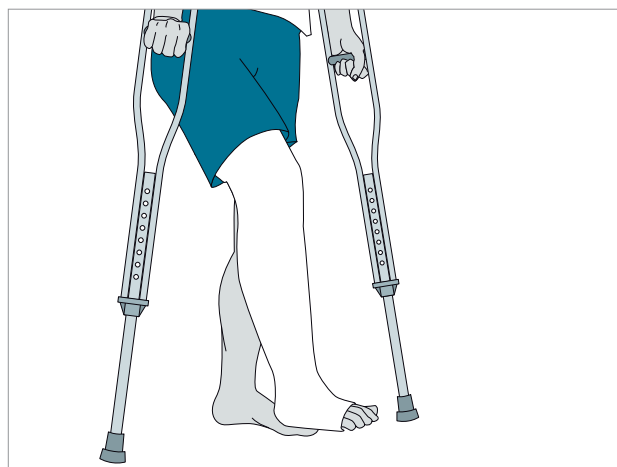
8 Aftercare

Elevate the lower leg on 2-3 pillows for 3-5 days.

X-ray control after reduction confirms the position, but must be repeated after 3-5 days. Redisplacement usually occurs during the early days, as the swelling subsides, and if diagnosed early enough, can often still be corrected non-operatively.

Analgesics and anti-inflammatory drugs should be prescribed, as necessary, during the first few weeks. If analgesia consumption is unexpectedly high, suspect redisplacement, or cast pressure on the skin.

If a cast becomes loose, it should be removed and replaced with a new one. If possible, wait until the fracture has become sticky (+/- 4 weeks) so that the reduction is not lost during the replacement procedure, but check regularly for redisplacement.





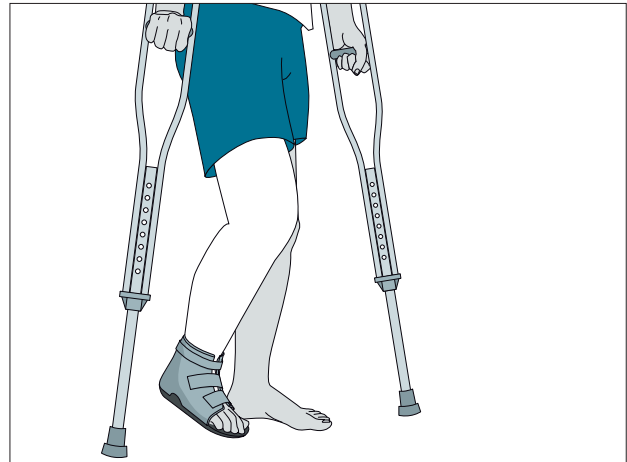
4 Tibial and malleolar fractures

4.14 I Malleolar fractures – Management with limited resources

Non weight bearing should be maintained for 4-6 weeks, depending on the fracture pattern. Thereafter, weight bearing can be started, reaching full weight bearing by 8-9 weeks.

In fractures that required reduction, the plaster cast should not be removed before 9-12 weeks, or before the patient manages to walk pain-free with the cast. In fractures that did not require reduction, the period in the cast can be reduced at the discretion of the surgical decision-maker.

After removal of the cast, rehabilitation should involve dedicated joint mobilization for a prolonged period. At this stage, it is also advisable to give a non-steroidal anti-inflammatory preparation for several weeks





4 Tibial and malleolar fractures

4.14 II Malleolar fractures – Functional treatment

Indication **44-A1.1 and 44-A1.2 type fractures**

1 Indication

Functional treatment is indicated only for stable fractures. Reduction in type A1.2 fractures is not necessary.

Functional treatment can also be indicated following ORIF of unstable fractures.

With functional treatment, movement of the ankle joint is possible.

2 Functional treatment

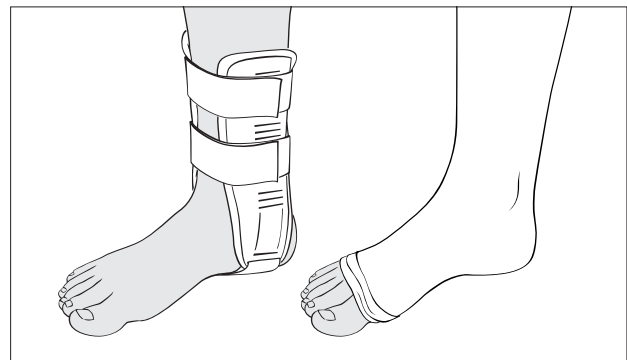
2.1 Implementation

Usually, functional treatment should continue for about 6 weeks after injury.

Elastic bandages, functional braces, and compression stockings support the soft tissues. Remove the brace if the patient feels pain, and check the soft tissues for pressure sores.

Mobilize the patient as soon as possible. Physiotherapy can be helpful (joint movements, lymphatic drainage, manual therapy). Weight bearing is allowed within the limits of any pain and / or swelling.

Check x-rays are taken after 3 and 6 weeks.



Without immobilization, pharmaceutical thromboembolic prophylaxis is only indicated in high risk patients. Non-steroidal anti-inflammatory medication helps to relieve pain and swelling.



5 Acetabular fractures

5.11 I Acetabular fractures – Nonoperative treatment

1 Introduction

1.1 Indications for conservative treatment

As a general rule, acetabular fractures are articular fractures, so they have to be treated under the principles of anatomical reduction, stable internal fixation, and early mobilization.

However, there are limited indications for conservative treatment:

- Medical contraindications
- Pre-existing osteoarthritis
- Local infections
- Osteopenia of the innominate bone
- Special fractures characteristics
 - Undisplaced fractures
 - Very low transverse or anterior column fractures
 - Both column fractures that achieve secondary congruence.

1.2 Contraindications to nonoperative treatment

1.2 Contraindications to nonoperative treatment

Contraindications to nonoperative treatment, and thus indications for surgical treatment, are instability and incongruity.

A. Instability

Hip dislocation associated with

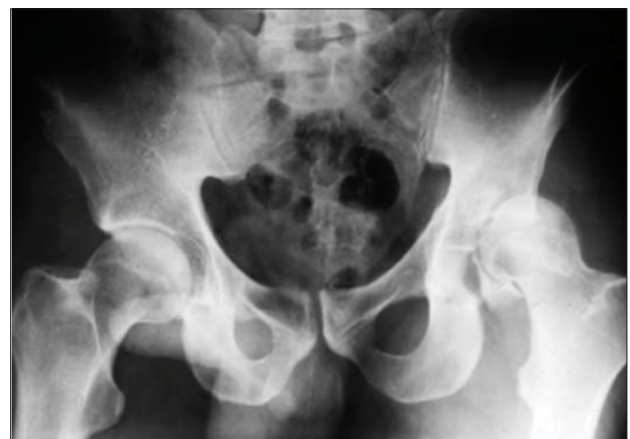- Posterior wall or column displacement.
- Anterior wall or column displacement.

B. Incongruity

- Fractures through the roof or dome
- Displaced dome fragment
 - Transverse or T-types (transtectal)
 - Both column types with incongruity (displaced posterior column)
- Retained bone fragments
- Displaced fragments of the femoral head
- Soft tissue interposition.

1.3 Amount of incongruity

- Step bigger than the width of the cartilage
- Gap bigger than width of the cartilage
- Marginal impaction
- Fracture that involves 20% of the surface of the weight-bearing area.
- Increasing of 20% of the circumference of the acetabulum at the equator of the femoral head.





1.4 Stability of the fracture

Stability is determined by a roof arc measurement.

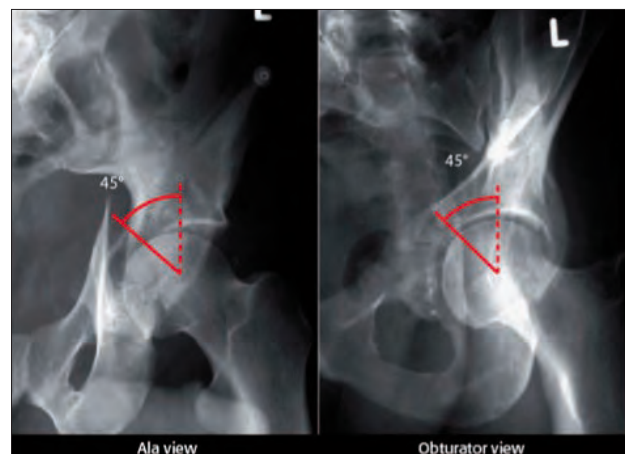
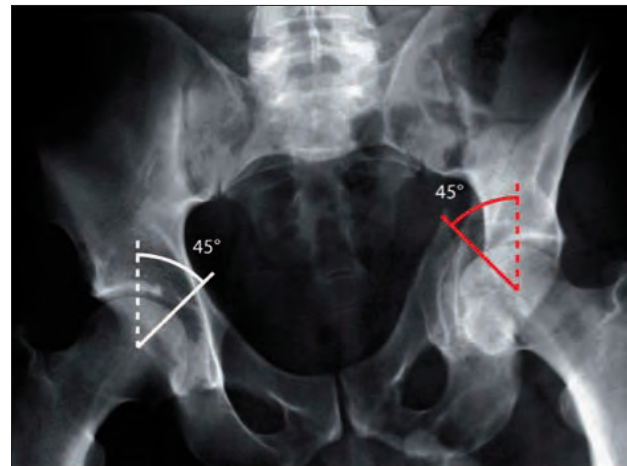
The roof arc angle is determined in the following way:

1. Three radiographic views are needed: AP view, ala and obturator views. Begin by drawing a vertical line through the center of the acetabulum (or the center of the reduced femoral head) on each radiographic view.
2. Now add a second line, intersecting the first at a 45 degree angle at the level of the femoral head's center.

If the second line is outside of the fracture zone in each of the 3 radiographic views, the fracture is considered stable.

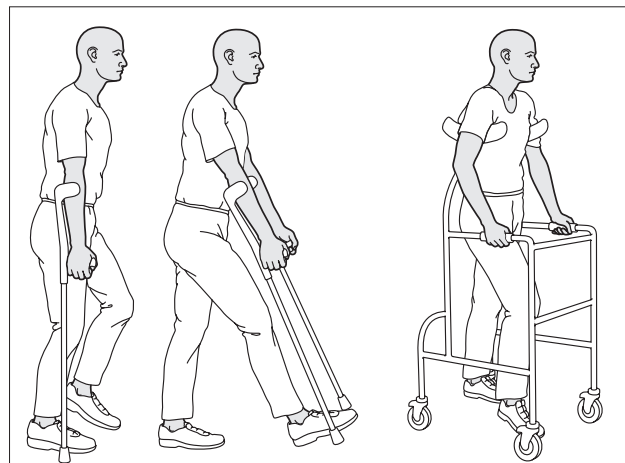
Our example shows a fractured weight-bearing dome of the left acetabulum, with the second line well within the fracture zone, indicating instability.

These images show corresponding measurement of the roof arc on ala (left) and obturator (right) views.



2 Undisplaced fractures

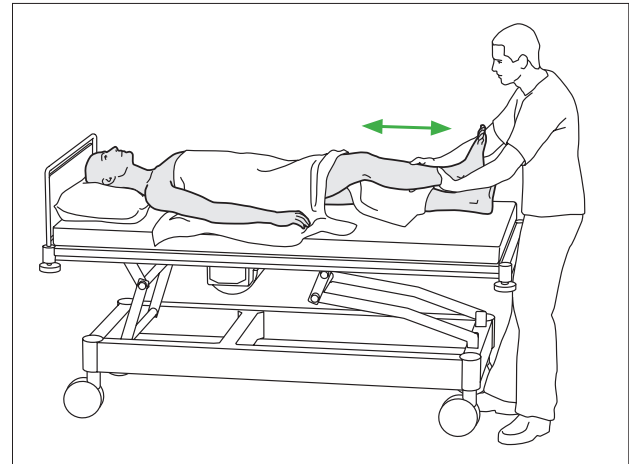
After 6 weeks the iliac bone is completely healed. During the period after fracturing, patients are allowed to mobilize with crutches or a walker, as soon as pain is released. Usually that happens after a few days of bed rest. Anticoagulation therapy is established during this period. Once the fracture is healed, no further assistance is necessary.





Functional therapy

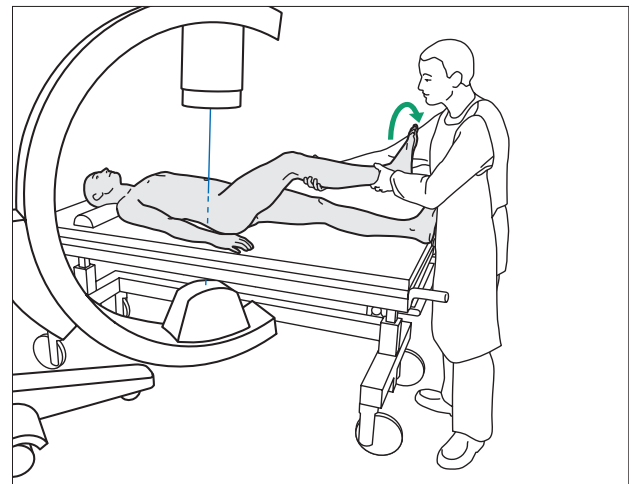
Passive assisted and active range of motion are encouraged from the very beginning.



3 Displaced fractures

Reduction

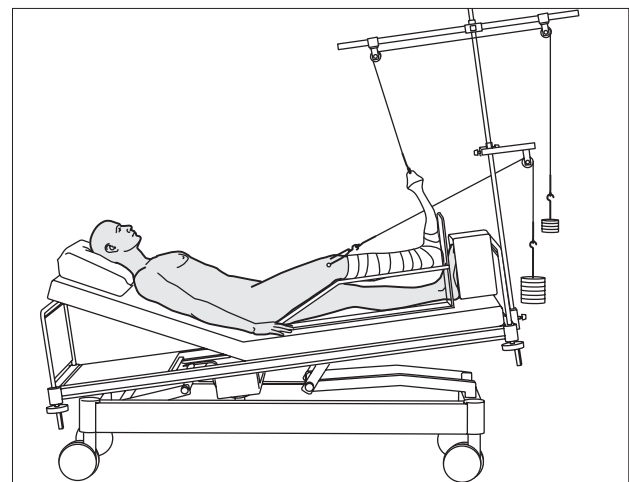
Closed reduction is attempted after hip dislocation.



Skeletal traction

If for any reason the residual amount of displacement is less than indicated for surgical procedure, or there is any contraindication to it, the patient could be put under supracondylar skeletal traction. Usually the tractional weight is 1/7 of the body weight.

Skeletal traction has to be sustained for 6-8 weeks in acetabular and in bony pelvic injuries.





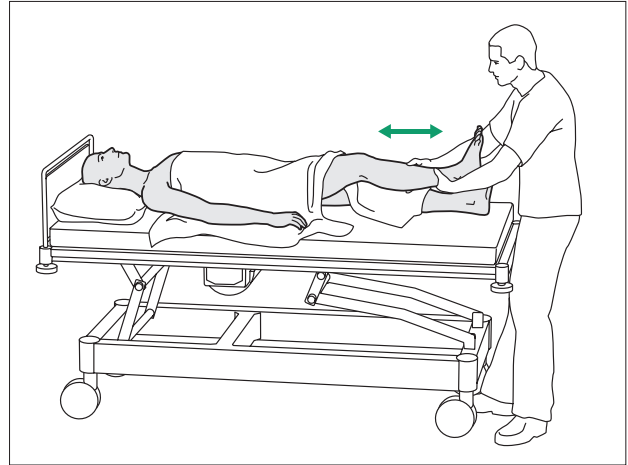
Functional therapy

After completing the skeletal traction, Passive assisted and active range of motion are encouraged.

Some patients after such a long period in traction require the use of a continuous passive motion machine to increase the range of motion.

Even possible to put the patient in skeletal traction, there are many complications related with the bed resting time, such as pulmonary problems, decubitus ulcers, deep vein thrombosis, that have to be addressed.

Final results are in many cases unpredictable.





6 Fractures of the hand

6.11 I Scaphoid fractures – Nonoperative treatment with a cast

Indication **Undisplaced fracture of the waist of the scaphoid**

1 Indications

1.1 Indications for nonoperative treatment

Nonoperative treatment for scaphoid fractures is indicated in the following circumstances:

- Tuberosity fractures
- Incomplete fractures
- Undisplaced waist fractures
- All scaphoid fractures in low-demand, or high-risk patients

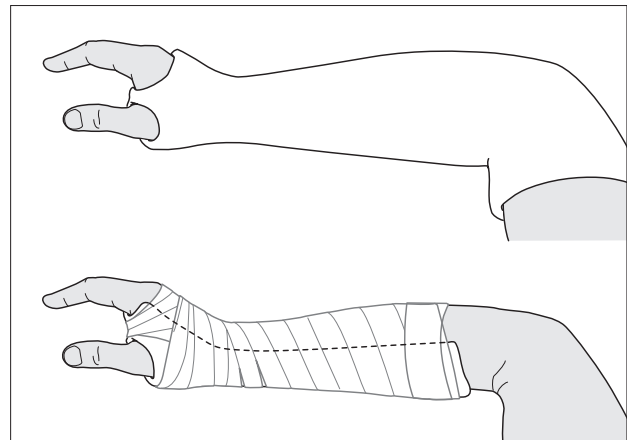
1.2 Contraindications

If treatment is delayed for 3 weeks, or longer, the risk of nonunion rises significantly. In such cases, operative treatment is the method of choice.

2 Plaster

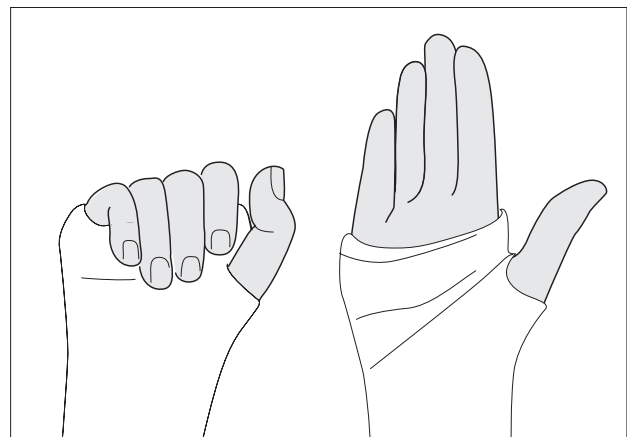
Immobilize the wrist in a well-padded, below-elbow cast, with the wrist slightly extended, and the proximal phalanx of the thumb included in a position of slight opposition (“scaphoid cast”).

An alternative is a radius plaster, the so-called “Colles” cast.



Pitfall: Impeded MCP flexion

Make sure that the plaster does not extend too far distally, both at the levels of the finger metacarpophalangeal joints (MCP) and the thumb IP joint. The cast must allow complete flexion of these joints.



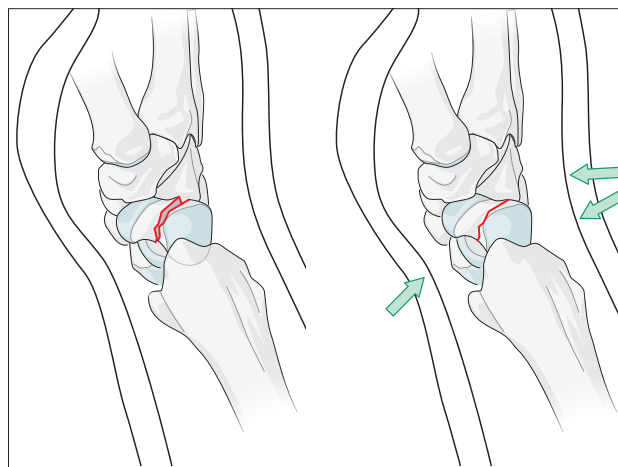


3 Closed reduction

Displacement is usually an indication for operative treatment. However, under certain circumstances (e.g. low-demand, or high-risk, patient), nonoperative treatment may be preferable. The amount of displacement can sometimes be reduced by moulding the plaster before it hardens.

Press the scaphoid tuberosity upwards from the palmar aspect. Carefully mould dorsally over the capitate to depress the distal carpal row in relation to the proximal carpal row.

Note: If displacement of the fracture persists, an above-elbow scaphoid cast with the forearm in supination and the wrist in ulnar deviation has been shown to aid reduction (*King et al, JRoySocMed, 1982*)



4 Duration of immobilization

- Tuberosity fractures: 6 weeks. At that time, check x-rays and start physiotherapy.
- Undisplaced waist fractures: 8-12 weeks. We recommend CT scan or polyaxial tomography at 8 weeks to confirm that the fracture is healed*.

If union is not achieved by this time, continue with immobilization for an extra 4 weeks. If the fracture heals during this period, start physiotherapy. Otherwise consider operative treatment.

*A clinical sign of union is the strength of the pinch of the tip of the index finger to the thumb.





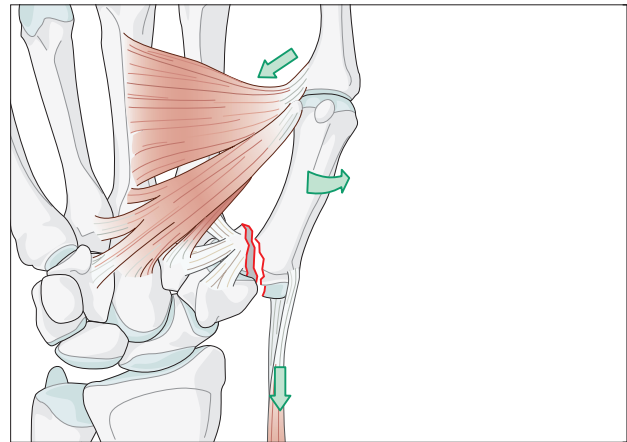
6 Fractures of the hand

6.12 I Fractures of the thumb – Nonoperative treatment of a Bennett fracture

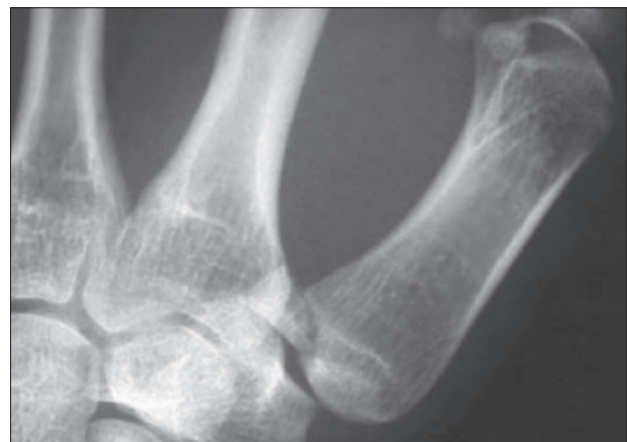Indication **Bennett fracture**

1 Introduction

Bennett's injury is a fracture subluxation of the first carpo-metacarpal joint. The causative mechanism is axial overload along the first metacarpal, combined with simultaneous flexion. The palmar oblique ligament holds the palmar marginal fragment in its anatomical position. The first metacarpal is adducted and supinated by adductor pollicis. The metacarpal as a whole is also displaced proximally by the abductor pollicis longus muscle.



The treatment goals are to reposition the first metacarpal in the carpo-metacarpal joint, and to restore the articular surface.



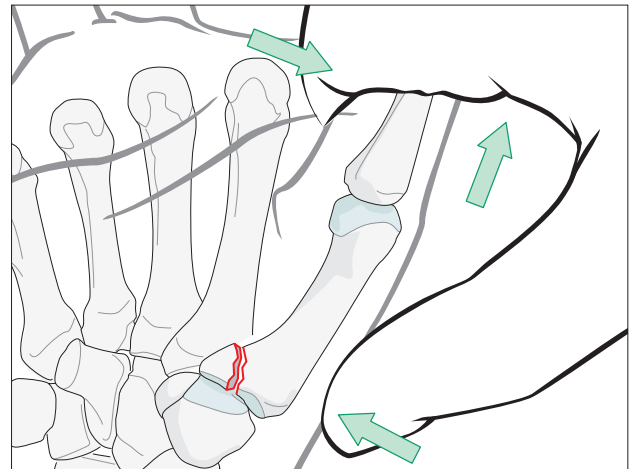


2 Closed reduction

Reduction is performed by a combination of

1. longitudinal traction
2. pronation of the metacarpal
3. pressure at the thumb metacarpal base.

Confirm correct restoration of the articular surface using image intensification.

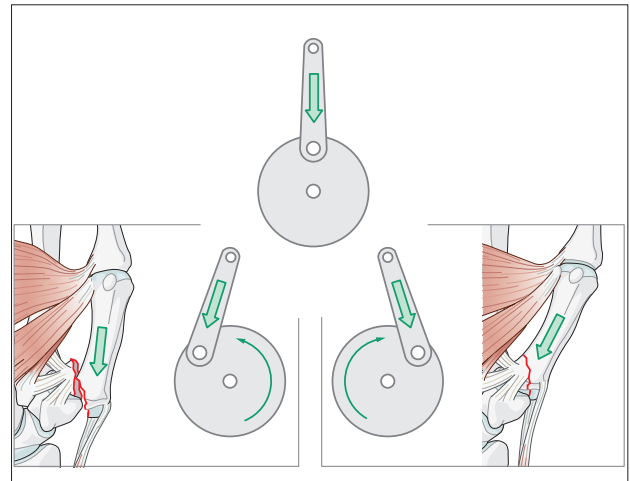


3 Reduction principles

Bennett's fracture possesses considerable potential stability. If the carpo-metacarpal joint is held in extension, thus tightening the palmar ligaments, the reduction will be stable and dorsal redisplacement is unlikely to occur. John Charnley* likened the mechanics of this situation to the crank and connecting rod of an engine: treatment by traction is comparable to the crank standing at "top dead center". This leaves the bone in a state of "uncertain equilibrium".

Without traction (as represented on the bottom left of our illustration), muscular tone can induce complete dislocation if the thumb is allowed to flex.

However, when the thumb is in extension (bottom right of our illustration), the muscle tone will increase the stability of the reduction by generating pressure against the undisplaced fragment and thrusting the bone deeper into the carpo-metacarpal socket.

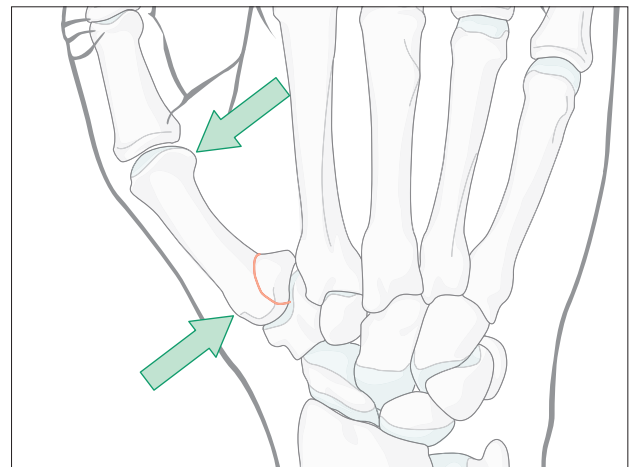


* Charnley, J. (1957) *The closed treatment of common fractures*. Edinburgh, London: Churchill Livingstone, 144

4 Applying cast

4.1 Maintaining reduction

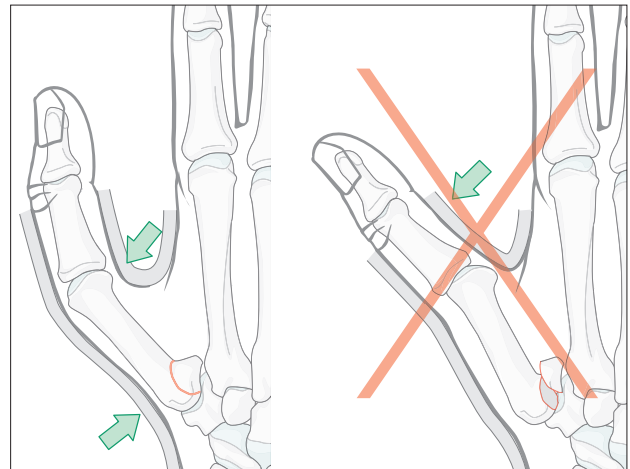
During the application of the plaster, it is important to exert pressure from the dorsal aspect onto the first metacarpal base, and from the palmar aspect over the first metacarpal head.





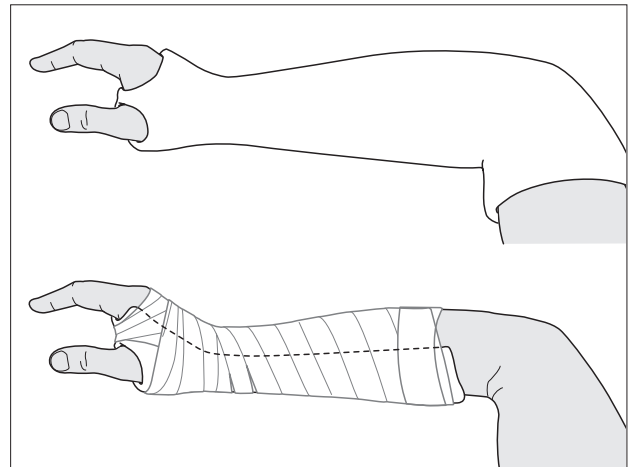
4.2 Pitfall: palmar pressure

Avoid pressing from the palmar side onto the base of the proximal phalanx. This results in redisplacement of the fracture and hyperextension of the MCP joint.

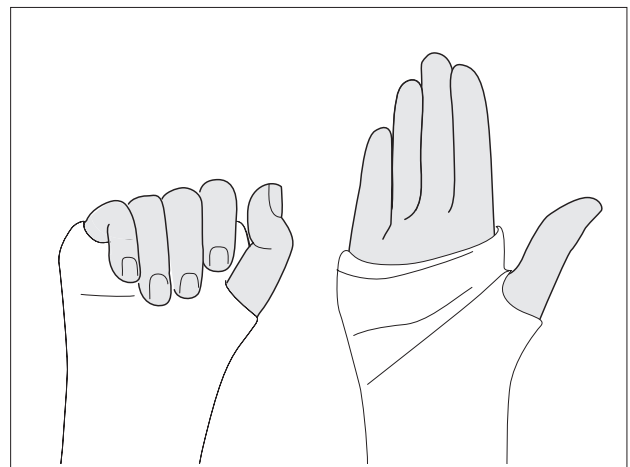


4.3 Apply the cast

Immobilize the wrist in a well-padded below-elbow cast with the wrist slightly extended, and the thumb immobilized in a position of slight abduction, with appropriate moulding of the cast.



Make sure that the cast does not extend too far distally, either at the level of the finger metacarpophalangeal joints (MCP) or the interphalangeal joint of the thumb. The cast must not limit complete flexion of these joints.

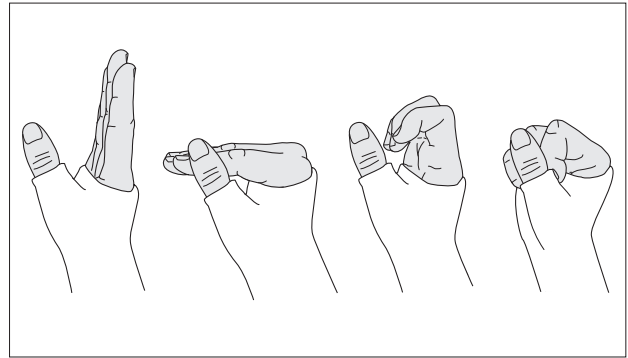




5 Aftertreatment

Confirm reduction by radiographs after the cast has been applied. Repeat radiographs at weekly intervals to check the fracture reduction. Usually, immobilization for a 6 week period is sufficient.

The patient is instructed to exercise the MCP joints and interphalangeal joints regularly.





6 Fractures of the hand

6.12 II Fractures of the thumb – Nonoperative treatment of a Rolando fracture

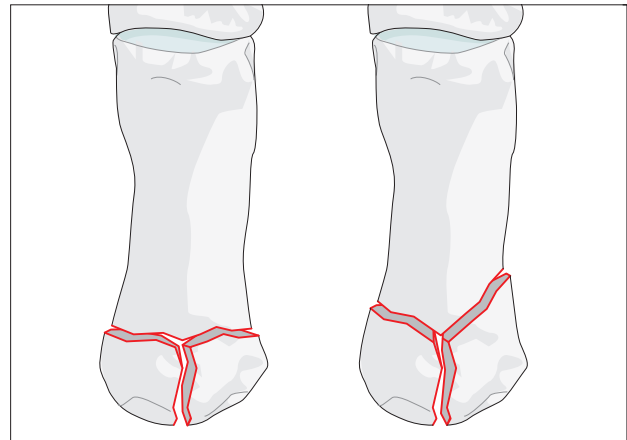
Indication **Rolando fracture**

1 Introduction

Rolando's fracture is a 3-part intraarticular fracture of the base of the thumb metacarpal. These T- or Y-shaped fracture patterns can occur either in the frontal, or in the sagittal plane.

The causative mechanism is axial overload along the first metacarpal causing compression failure of the joint surface.

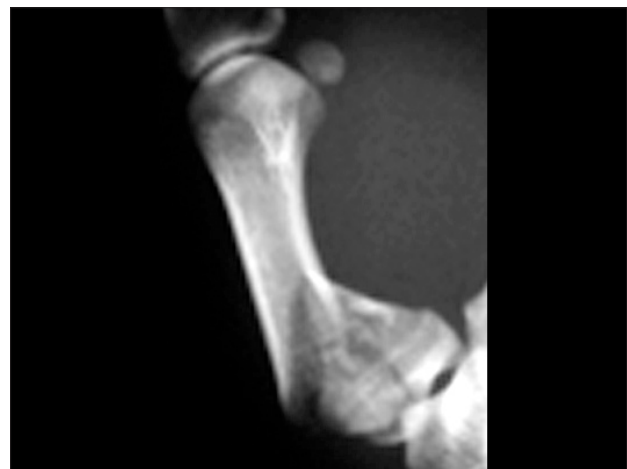Today, the term "Rolando's fracture" is often misused to describe multifragmentary intraarticular fractures of the thumb metacarpal base.



Metaphyseal and articular comminution are often more marked than apparent on the x-rays. The full extent of the comminution is often seen only after distraction of the fracture, as demonstrated in the images.

A CT scan, or traction x-rays, are advisable.

If the fracture can not be reduced anatomically, open reduction and internal fixation must be performed.

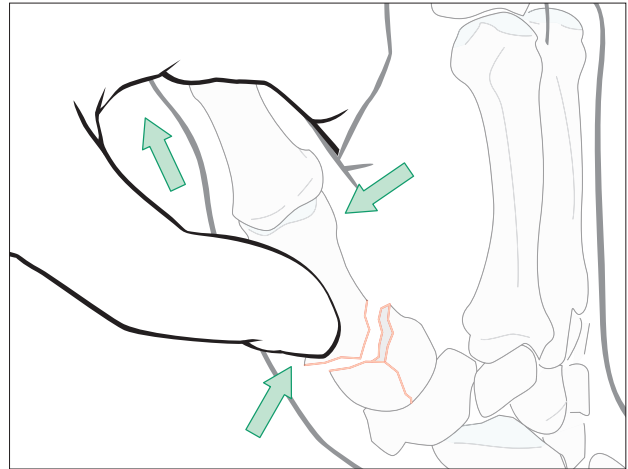




2 Reduction

2.1 Apply traction

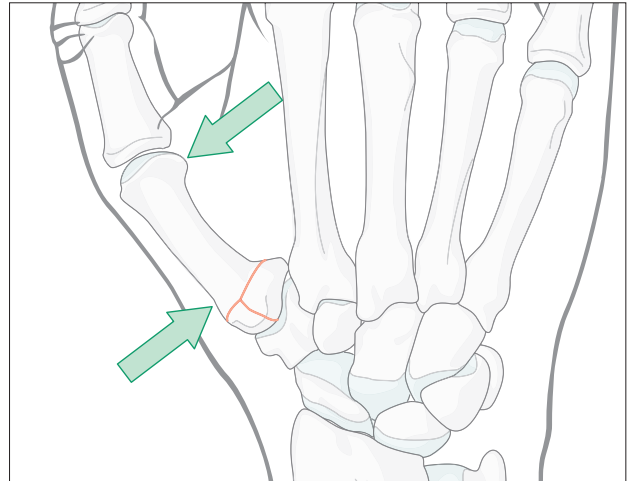
As there is usually a flexion deformity, reduction of the diaphyseal fragment to the articular fragments can be performed with axial traction on the thumb and simultaneous pressure over the dorsal aspect of the basal diaphysis near the fracture.



3 Applying cast

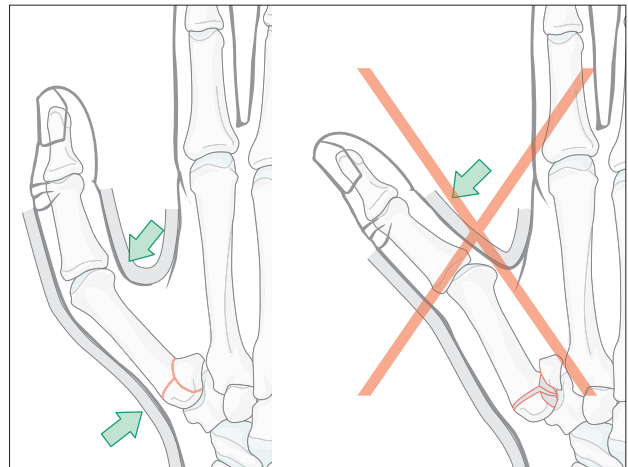
3.1 Maintaining reduction

During the application of the cast, it is important to exert pressure over the dorsal aspect of the first metacarpal diaphyseal base, and from the palmar aspect over the first metacarpal head.



3.2 Pitfall: palmar pressure

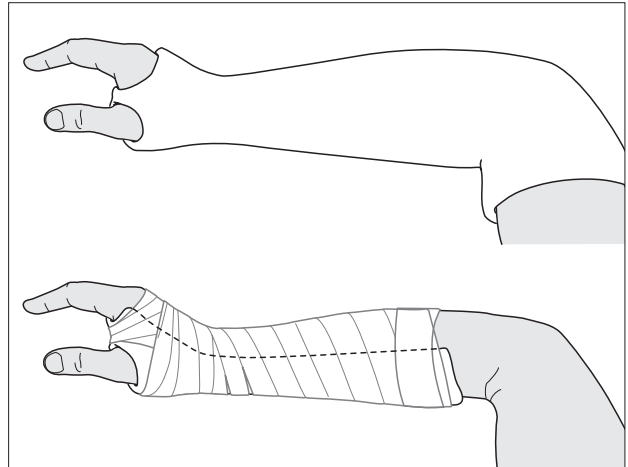
Avoid pressing from the palmar aspect over the base of the proximal phalanx. This results in redisplacement of the fracture and hyperextension of the MCP joint.



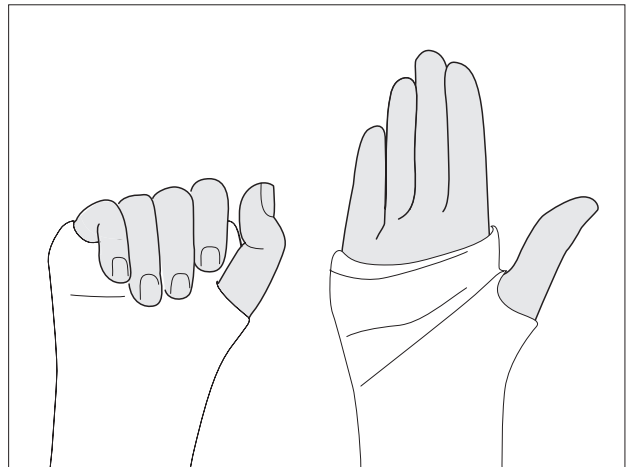


3.3 Apply the cast

Immobilize the wrist in a well-padded below-elbow plaster with the wrist slightly extended, and the thumb immobilized in a position of slight abduction.



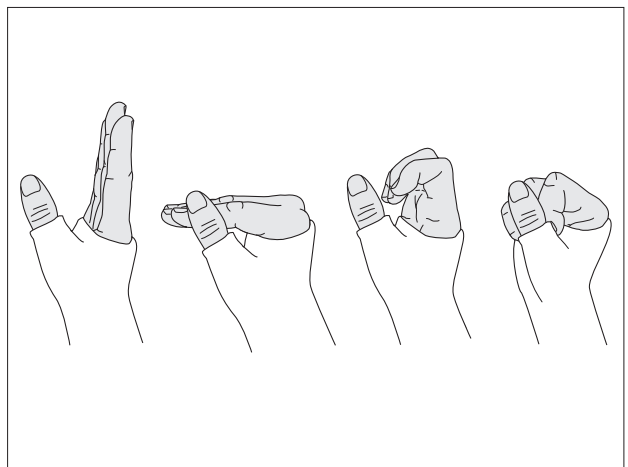
Make sure that the cast does not extend too far distally, either at the level of the finger metacarpophalangeal joints (MCP), or the interphalangeal joint of the thumb. The cast must not limit complete flexion of these joints.



4 Aftertreatment

Confirm reduction by radiographs after the plaster has been applied. Repeat radiographs in weekly intervals until healing. Usually, immobilization for a 6 week period is sufficient.

The patient is instructed to regularly exercise the MCP joints and interphalangeal joints of the fingers, and the interphalangeal joint of the thumb.





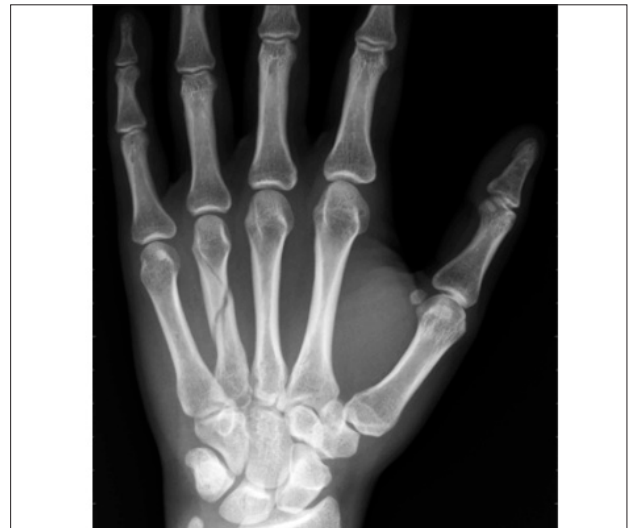6 Fractures of the hand

6.13 I Metacarpal fractures – Nonoperative treatment

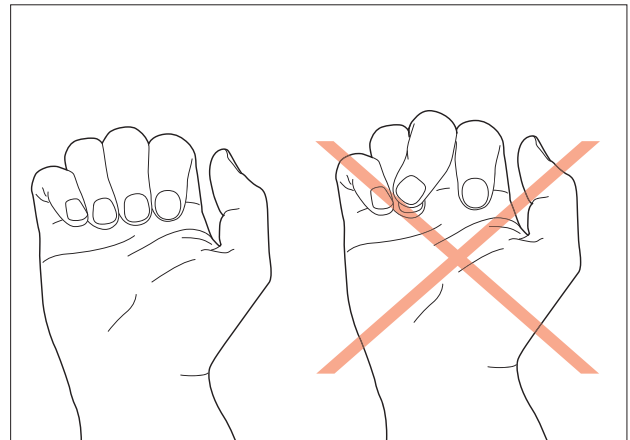
Indication **Undisplaced, or minimally displaced, fractures of the metacarpal shaft**

1 Indications for nonoperative treatment

Undisplaced, or minimally displaced, fractures of the metacarpal shaft can be treated nonoperatively. Most of these fractures produce a flexion deformity and often minimal shortening. If the flexion deformity exceeds 10-20 degrees in fractures of the second and third metacarpals, or 20-30 degrees in fractures of the fourth and fifth metacarpals, ORIF is recommended. Shortening of less than 2 mm does not interfere with function, but more than 5 mm can not be accepted.



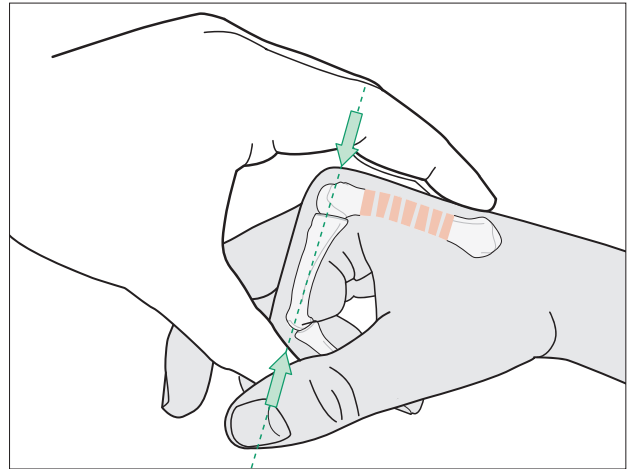
Irreducible rotational malalignment is an indication for ORIF.



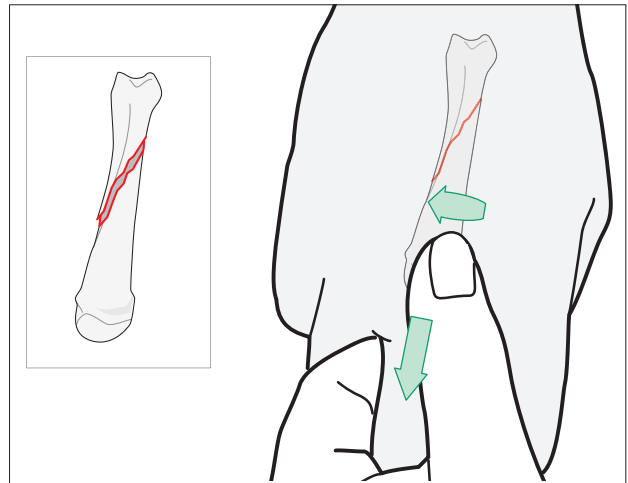


2 Reduction

Displacement usually occurs as a flexion deformity that can be reduced by exerting pressure on the metacarpal head from the palmar aspect, either directly, or using the proximal phalanx as a piston.



Especially in spiral oblique fractures, shortening of the metacarpal is associated with rotational malalignment. Reduction, therefore, is achieved by a combination of longitudinal traction on the finger and derotation. There is a high risk of secondary redisplacement, indicating ORIF as the treatment of choice in such cases.



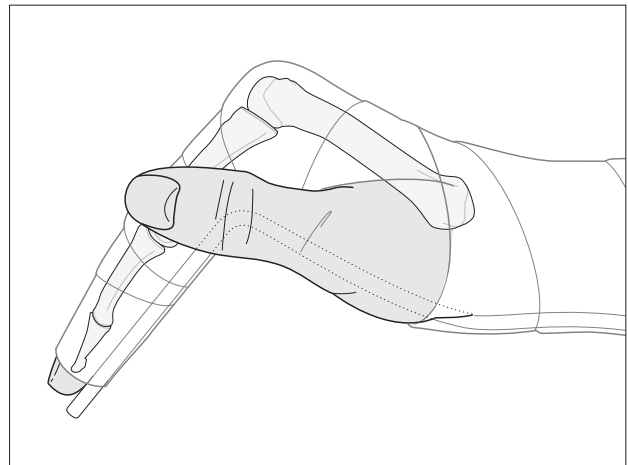
3 Option 1: Immobilization with palmar splint

A splint may be applied with the hand in an intrinsic plus (Edinburgh) position and the wrist in slight extension of 20-30 degrees.

In compliant patients, only the fractured finger ray and the two adjacent rays are included in the splint, in fractures of the third, or fourth, metacarpal. In fractures of the second metacarpal, it may be sufficient to include only the second and third rays. In fractures of the fifth metacarpal, the fifth and fourth rays are included.

The splint is held in place with an elastic bandage. The bandage should not be overtightened at the level of the wrist joint, so as to avoid excessive swelling of the hand. Direct skin contact of adjacent fingers should be prevented by placing gauze pads between them.

This splint is easy to apply and needs no hand therapy during the period of immobilization. A potential disadvantage of this technique is the complete immobilization of uninjured fingers and joints.

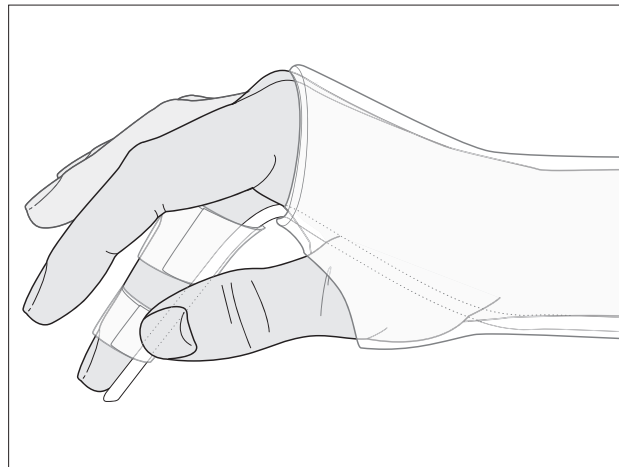




4 Option 2: Immobilization with a forearm cast and finger splint

A standard forearm cast is applied, including the wrist joint in 30 degrees of extension, and the aluminium splint is incorporated in the cast. This aluminium splint must be pre-bent to 90 degrees proximal to the level of the MCP joint of the injured finger. The finger is taped to this splint in an intrinsic plus position. Correct rotational alignment must be checked. The other fingers are not immobilized.

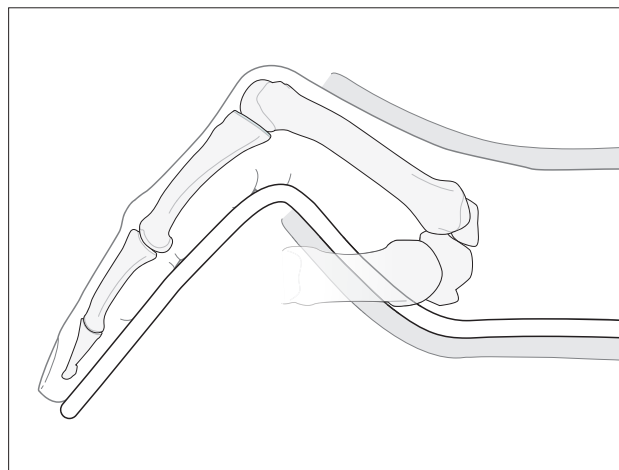
The cast must only be applied once the initial swelling has abated, usually a few days after the injury.



Correct bending of the aluminium splint and correct fixation of the splint in the cast are difficult but essential. The bend for the flexion of the MCP joint is more proximal than often perceived. There is a risk of excessive pressure and later ulceration of the soft tissues at the level of the bend if it is too distal.

The advantage of this technique is that only the injured finger is immobilized. Usually hand therapy is not necessary.

Another advantage is that this technique helps maintain length in shortened fractures, but there is less control over rotation than with immobilisation of the adjacent rays (Option 1).

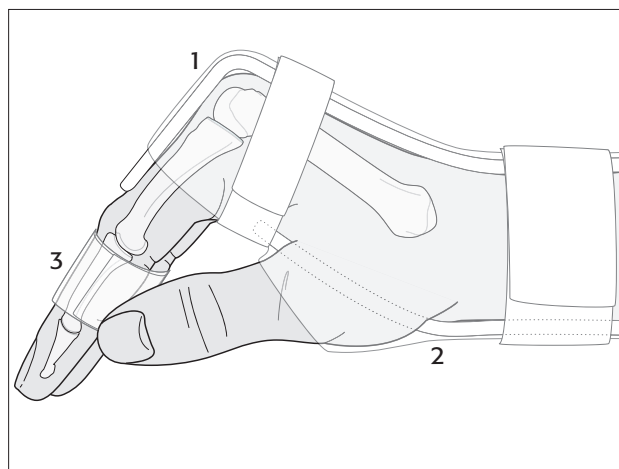


5 Option 3: Attelle fonctionelle

This splint comprises 3 parts:

- A dorsal splint maintaining the wrist in 30 degrees of extension and the MCP joints in full flexion, reaching distally to the PIP joints
- A palmar splint supporting the wrist in 30 degrees of extension, reaching the distal flexion crease of the palm
- A “buddy splintage,” or strapping (syndactylisation), applied at the middle phalanges II-V.

This technique allows immediate mobilization of the interphalangeal joints of all fingers. Its application, however, is difficult, and correct exercising must be supervised by a hand therapist. “Buddy splintage,” prevents rotational malalignment.



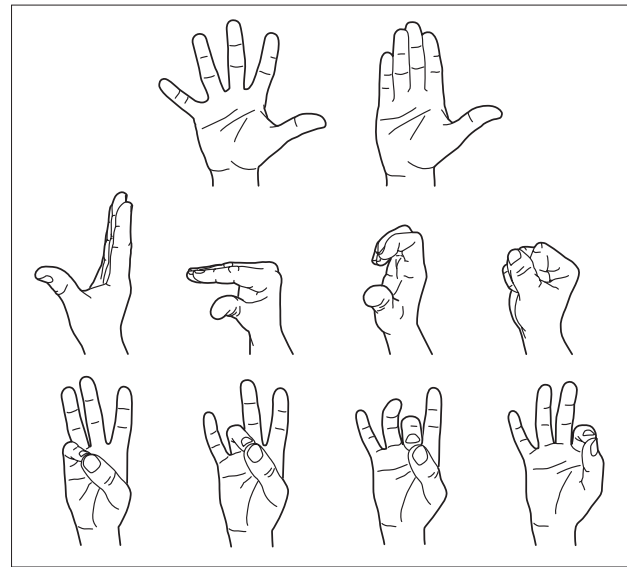


6 Follow up

X-ray checks of fracture position have to be performed immediately after the splint has been applied.

Follow-up check x-rays in the splint should be taken after 1 week, and possibly after 2 weeks. Immobilization is continued until about 4 weeks after the injury. At that time an x-ray without the splint is taken to confirm healing. Splinting can then usually be discontinued and active mobilization is initiated. Functional exercises are recommended.

If after 8 weeks radiographs confirm healing, full manual loading can be permitted.





6 Fractures of the hand

6.14 I Fractures of the proximal phalanx — Nonoperative treatment

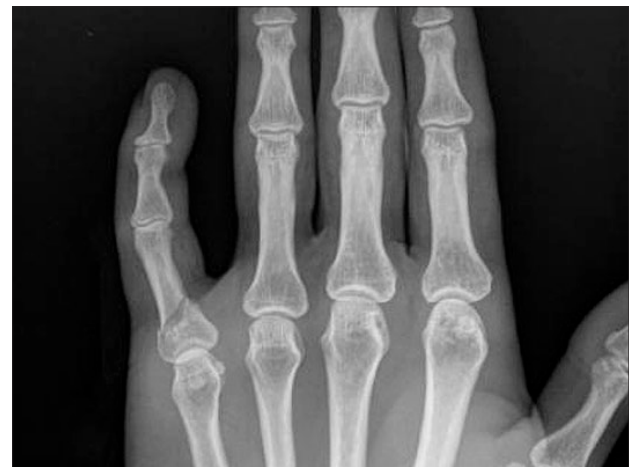Indication **Undisplaced, or minimally displaced, fractures of the diaphysis of the proximal phalanx**

1 Principles

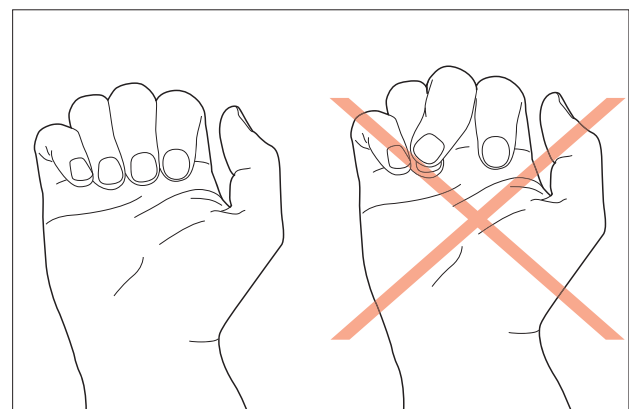
Undisplaced, or minimally displaced, fractures of the diaphysis of the proximal phalanx can be treated non-operatively.

Most of these fractures produce an extension deformity and minimal shortening. If the extension deformity exceeds 15-20 degrees, operative treatment is recommended. More than 2 mm shortening can not be accepted.

Undisplaced metaphyseal and articular fractures may also be treated nonoperatively.



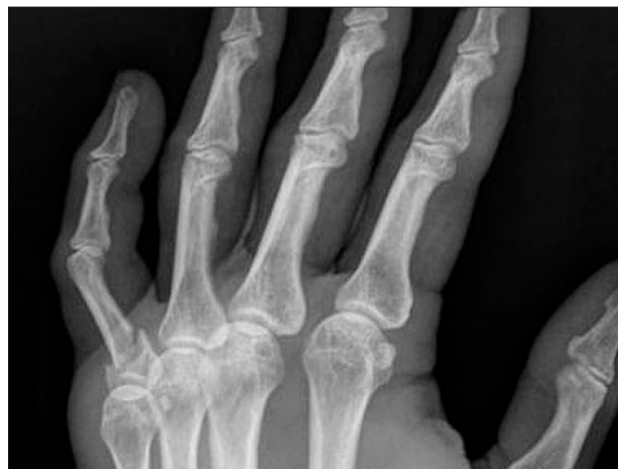Irreducible rotational malalignment is an indication for operative treatment.



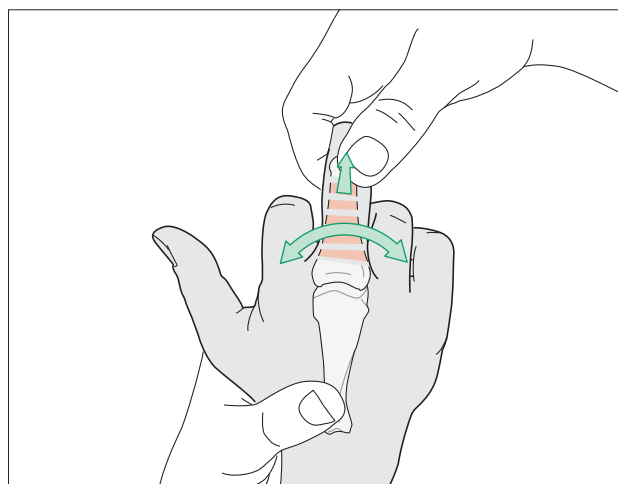


2 Reduction

Displacement usually occurs as an extension deformity.



Reduction is achieved by applying longitudinal traction to the finger and flexing the MCP joint. Rotational malalignment is also corrected. Any lateral angulation can be checked by comparison with the adjacent fingers, and must be reduced. Check angular reduction using image intensification.



3 Option 1: Immobilization with palmar splint

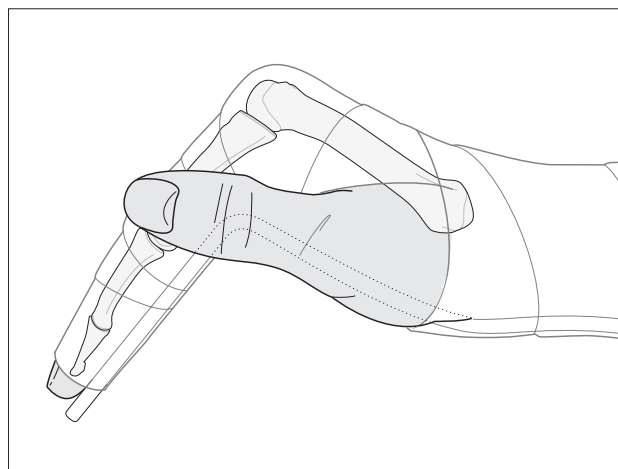
In undisplaced fractures, a splint may be applied with the hand in an intrinsic plus (Edinburgh) position and the wrist in slight extension of 20-30 degrees.

In compliant patients, only the fractured finger ray and the two adjacent rays are included in the splint.

The splint is held in place with an elastic bandage. The bandage should not be overtightened at the level of the wrist joint, in order to avoid excessive swelling of the hand.

Direct skin contact of adjacent fingers should be prevented by placing gauze pads between them.

This splint is easy to apply and needs no hand therapy during the period of immobilization. A potential disadvantage of this technique is the complete immobilization of uninjured fingers and joints.

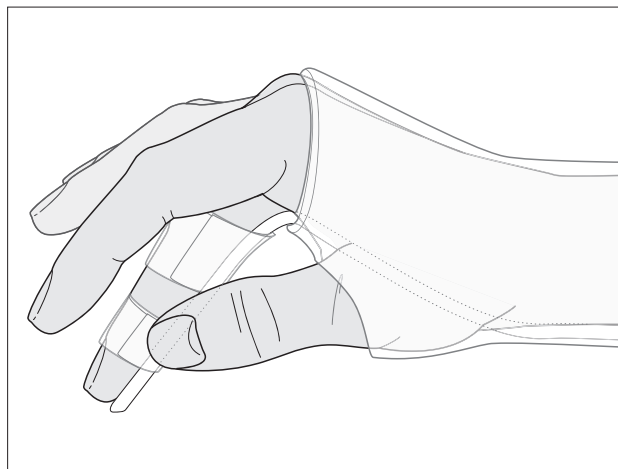




4 Option 2: Immobilization with a forearm cast and finger splint

A standard forearm cast is applied, including the wrist joint in 30 degrees of extension, and the aluminium splint is incorporated in the cast. This aluminium splint must be pre-bent to 90 degrees proximal to the level of the MCP joint of the injured finger. The finger is taped to this splint in an intrinsic plus position. Correct rotational alignment must be checked. The other fingers are not immobilized.

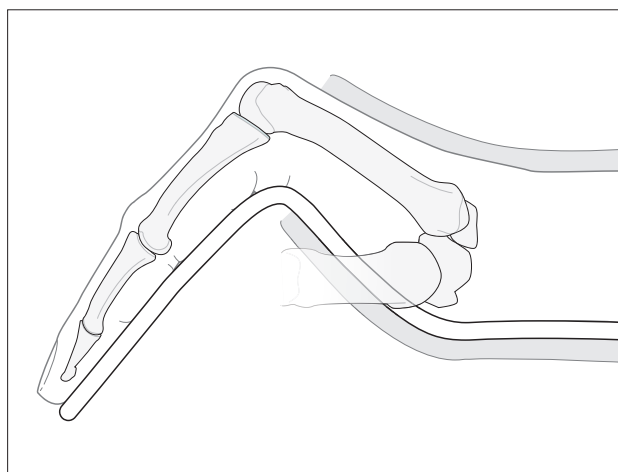
The cast must only be applied once the initial swelling has abated, usually a few days after the injury.



Correct bending of the aluminium splint and correct fixation of the splint in the cast are difficult but essential. The bend for the flexion of the MCP joint is more proximal than often perceived. There is a risk of excessive pressure and later ulceration of the soft tissues at the level of the bend if it is too distal.

The advantage of this technique is that only the injured finger is immobilized. Usually hand therapy is not necessary.

Another advantage is that this technique helps maintain length in shortened fractures, but there is less control over rotation than with immobilisation of the adjacent rays (Option 1).

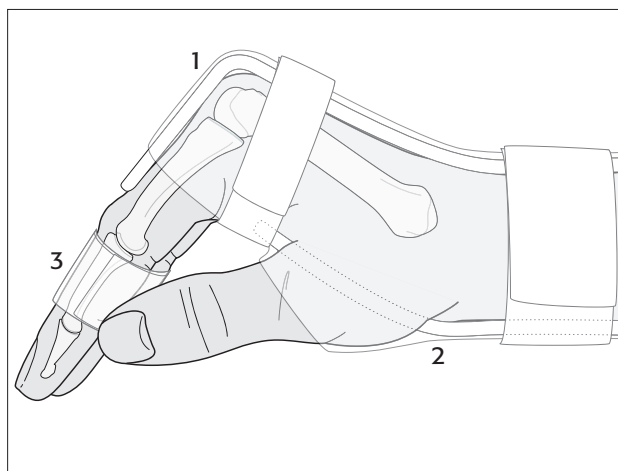


5 Option 3: Attelle fonctionelle

This splint comprises 3 parts:

- A dorsal splint maintaining the wrist in 30 degrees of extension and the MCP joints in full flexion, reaching distally to the PIP joints
- A palmar splint supporting the wrist in 30 degrees of extension, reaching the distal flexion crease of the palm
- A “buddy splintage,” or strapping (syndactylisation), applied at the middle phalanges II-V.

This technique allows immediate mobilization of the interphalangeal joints of all fingers. Its application, however, is difficult, and correct exercising must be supervised by a hand therapist. “Buddy splintage,” prevents rotational malalignment.





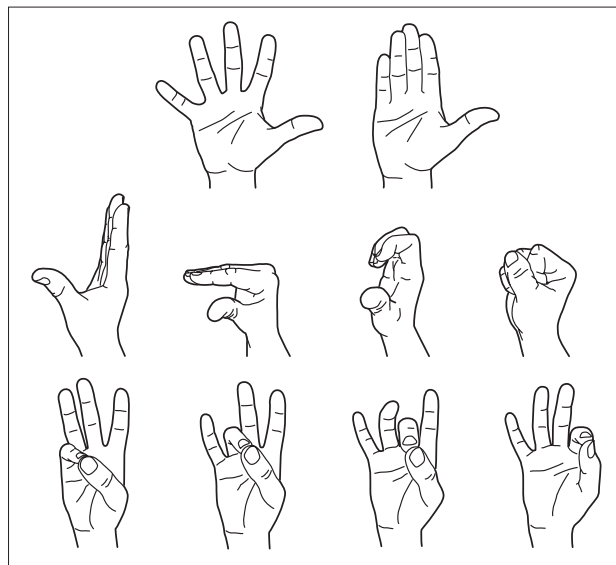
6 Aftertreatment

6.1 Follow up

X-ray controls have to be performed immediately after the splint has been applied.

Follow-up x-rays with the splint should be taken after 1 week, and possibly after 2 weeks. Immobilization is continued until about 4 weeks after the injury. At that time an x-ray without the splint is taken to confirm healing. Splinting can then usually be discontinued and active mobilization is initiated. Functional exercises are recommended.

If after 8 weeks radiographs confirm healing, full loading can be permitted.





6 Fractures of the hand

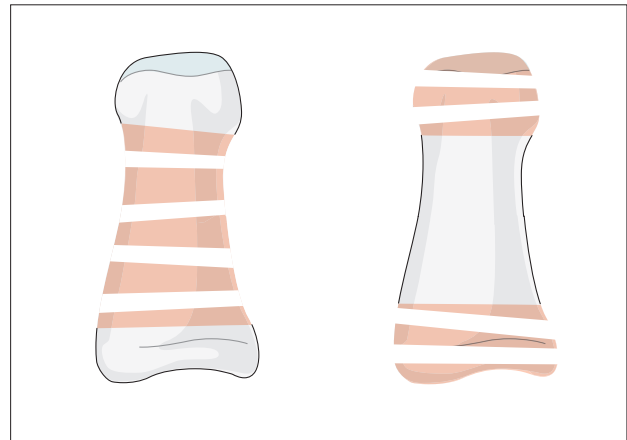
6.14 II Fractures of the middle phalanx – Nonoperative treatment

Indication **Undisplaced, or minimally displaced, fractures of the diaphysis of the middle phalanx**

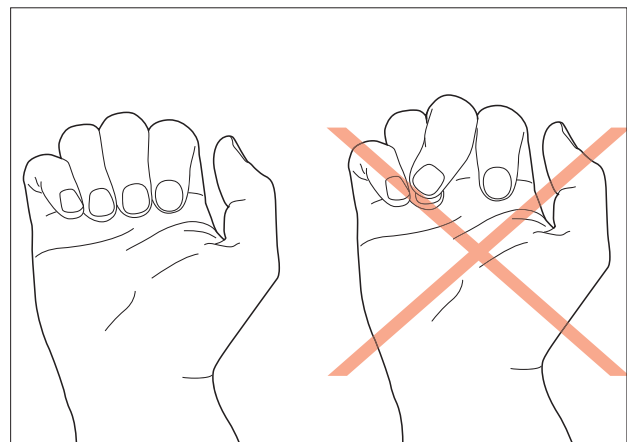
1 Principles

Undisplaced, or minimally displaced, fractures of the diaphysis of the middle phalanx can be treated nonoperatively.

Undisplaced metaphyseal and articular fractures may also be treated nonoperatively.



In fractures distal to the PIP joint, rotational overlap occurs only in the presence of fairly large degree of displacement. In such cases operative treatment is indicated, if malrotation can not be corrected by closed reduction.





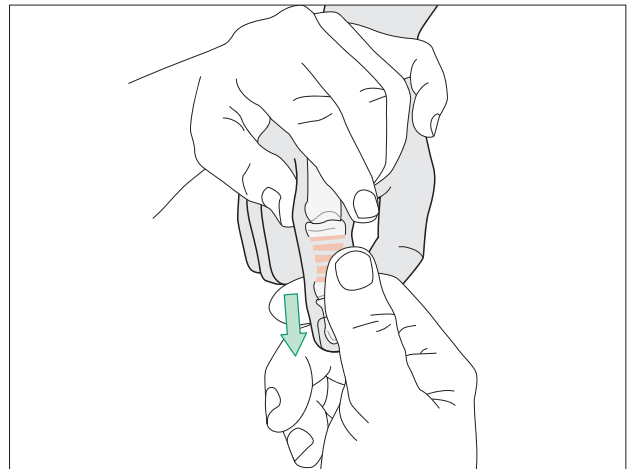
2 Reduction

Reduction is achieved by applying longitudinal traction to the finger.

Rotational malalignment is also corrected.

Any angular deviation can be checked by comparison with the adjacent fingers, and must be reduced.

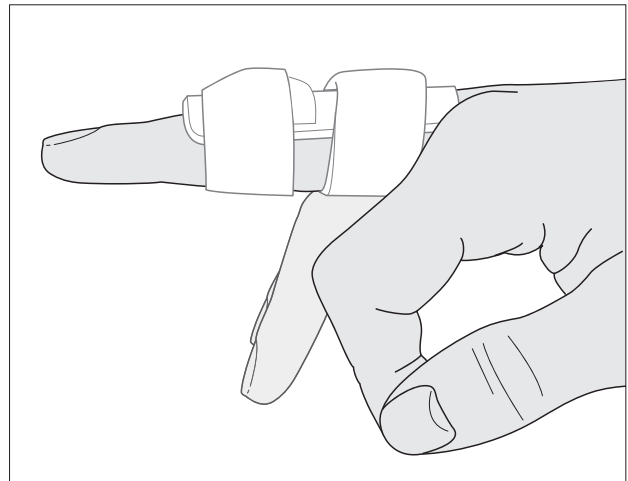
Check the reduction using image intensification.



3 Option 1: Finger splint or “buddy strapping”

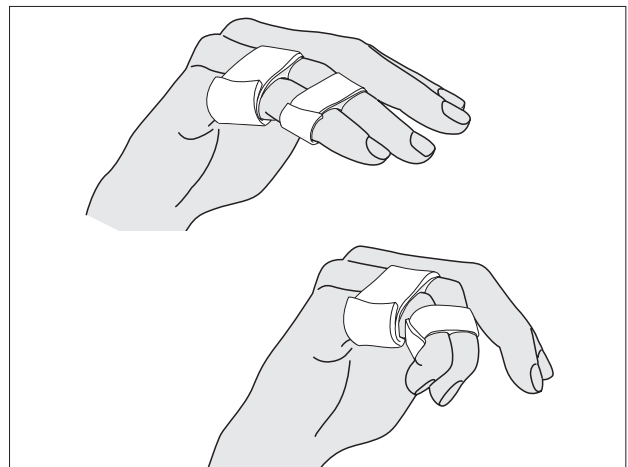
3.1 Finger splint

In compliant patients, undisplaced, or minimally displaced, fractures can be treated with a dorsal finger splint, combined dorsal and palmar splint, or a protection jacket.



3.2 Buddy strapping

Undisplaced, stable fractures can be treated with buddy strapping to the adjacent finger, to neutralize lateral, rotational forces on the finger.





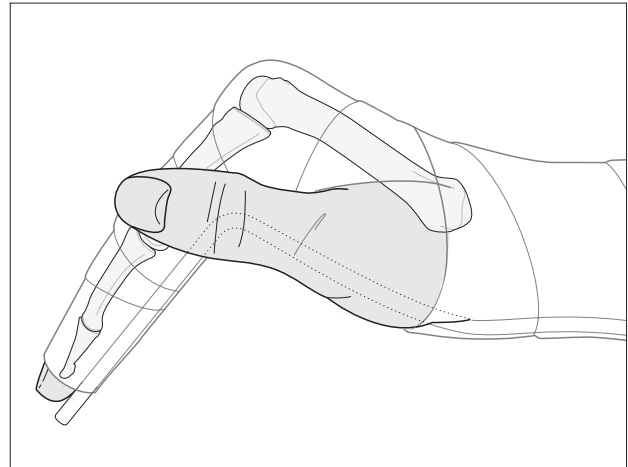
4 Option 2: Immobilization with palmar splint

In noncompliant patients, or in cases of dorsal soft-tissue injury, a palmar splint may be applied with the hand in an intrinsic plus (Edinburgh) position and the wrist in slight extension of 20-30 degrees.

The splint is held in place with an elastic bandage. The bandage should not be overtightened at the level of the wrist joint, in order to avoid excessive swelling of the hand.

Direct skin contact of adjacent fingers should be prevented by placing gauze pads between them.

This splint is easy to apply and needs no hand therapy during the period of immobilization. A potential disadvantage of this technique is the complete immobilization of uninjured fingers and joints.



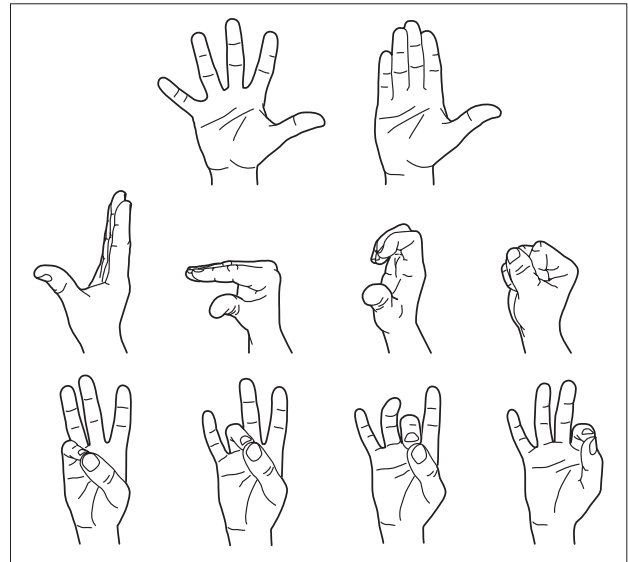
5 Aftertreatment

5.1 Follow up

X-ray checks of fracture position have to be performed immediately after the splint has been applied.

Follow-up check x-rays in the splint should be taken after 1 week, and possibly after 2 weeks. Immobilization is continued until about 4 weeks after the injury. At that time an x-ray without the splint is taken to confirm healing. Splinting can then usually be discontinued and active mobilization is initiated. Functional exercises are recommended.

If after 8 weeks radiographs confirm healing, full manual loading can be permitted.





6 Fractures of the hand

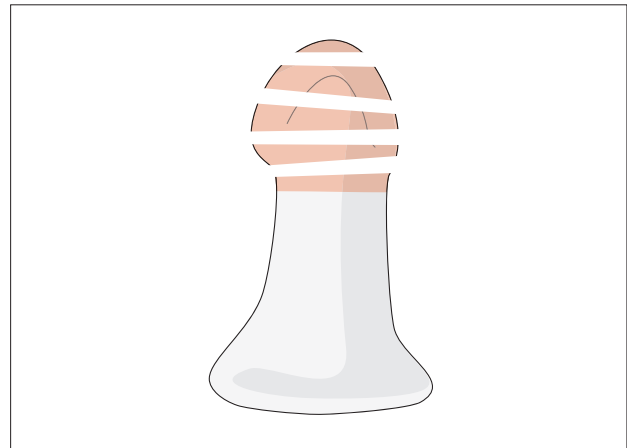
6.14 III Fractures of the distal phalanx – Nonoperative treatment

Indication **Most fractures of the distal phalanx**

1 Principles

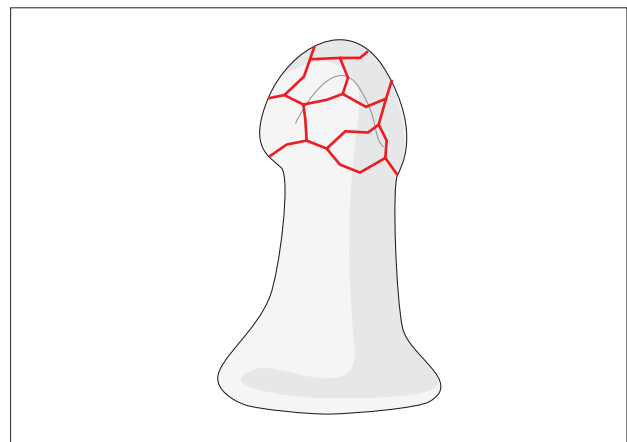
Most fractures of the distal phalanx can be treated non-operatively.

Nonoperative treatment is based on immobilization of the DIP joint in extension, leaving the PIP joint free.



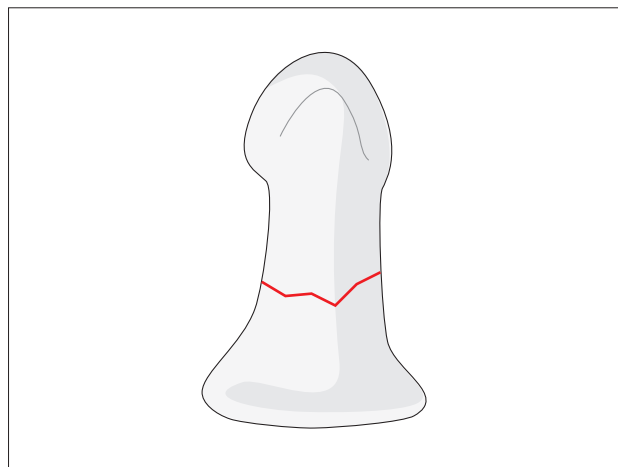
Fractures of the distal phalanx are often the result of direct impact, or crush injuries. Most frequently, there is a comminuted tuft fracture.

Nail bed injuries may need repair and reduction of the nail plate into the nail fold.



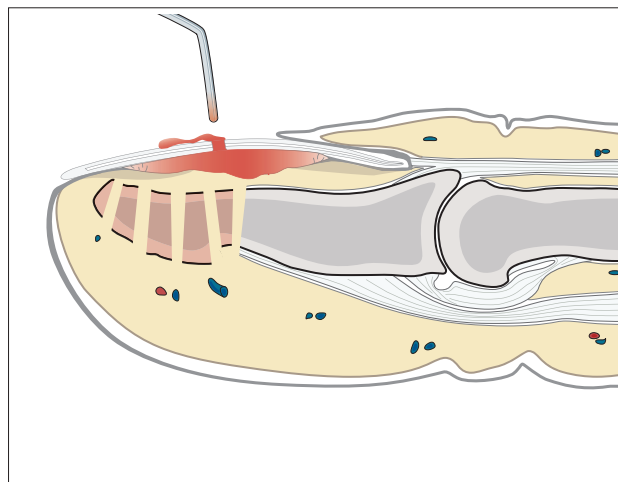


Transverse fractures of the proximal half of the distal phalanx are not well-suited to nonoperative treatment when there is no direct contact between the fragments. These fractures are often unstable and, in open fractures, the nail bed is often folded into the fracture. In these cases, open reduction and internal fixation are indicated.



2 Release of subungual hematoma

Closed crush injuries are often accompanied by a tense subungual hematoma, which can be exceedingly painful, due to the pressure within the closed space. The hematoma can easily be released by puncturing the nail with a red-hot needle, or paperclip end. If no further treatment is indicated, apply a simple splint and cool the finger with the judicious use of an ice pack.

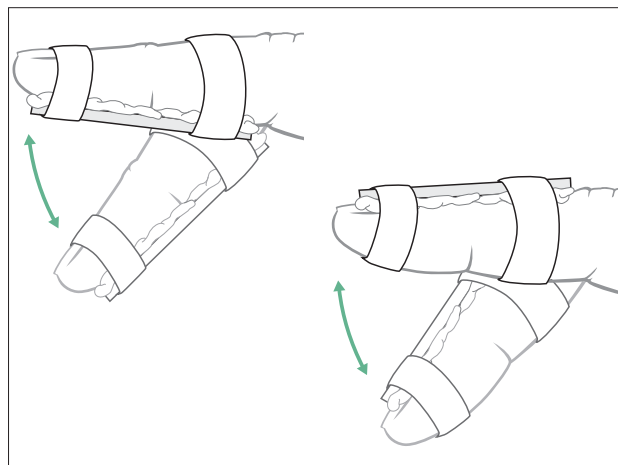


3 Splinting options

3.1 Dorsal splint versus palmar splint

Using a dorsal splint has the advantage of leaving the patient with the ability to pinch while the digit is immobilized.

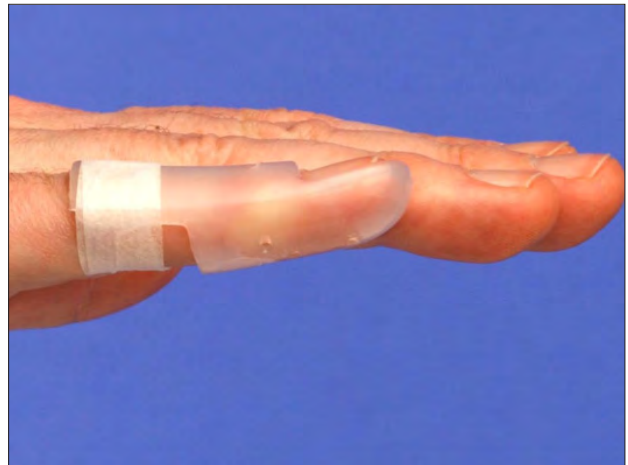However, proponents of palmar splintage argue that the palmar aspect is better cushioned than the dorsal and, thereby, can tolerate the splint better.





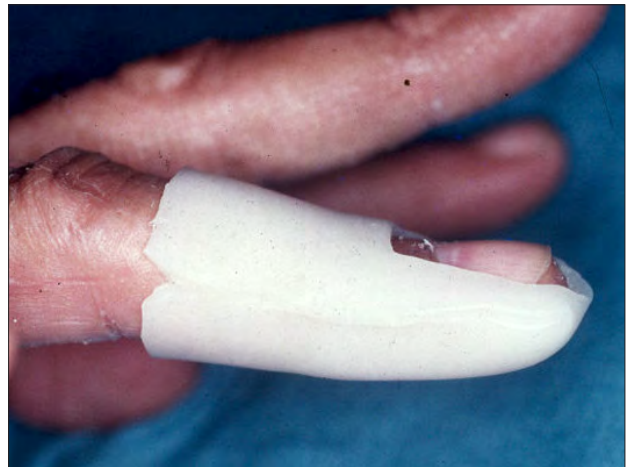3.2 Contoured custom thermoplastic splint

The advantage of a custom thermoplastic splint is that it is adapted better to the shape of the finger, and easier to change.



3.3 Pitfall: immobilization of the PIP joint

Do not immobilize the PIP joint.

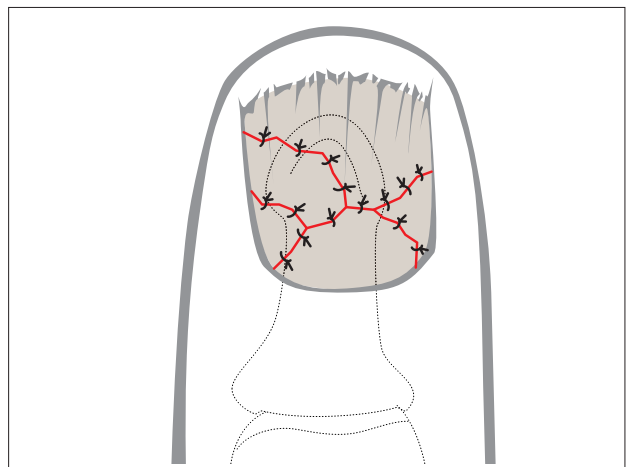


4 Repair of the nail bed

It is advisable precisely to repair the nail bed, or the germinal matrix, lest permanent deformity of nail growth occur.

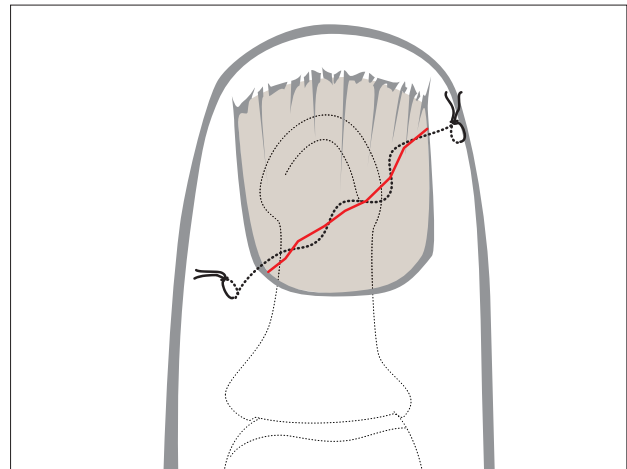
Such procedures are difficult, without the help of magnifying loupes. In many cases, an operating microscope is an even better choice, if available.

Separate fine absorbable sutures should be used.

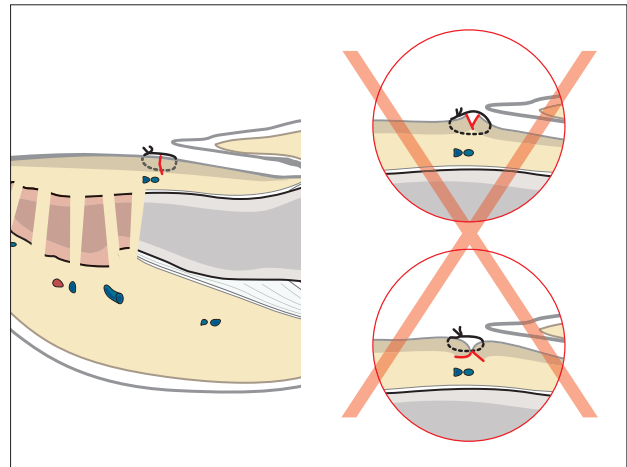




In simple transverse, or oblique, lacerations of the nail bed, a running suture may be used.



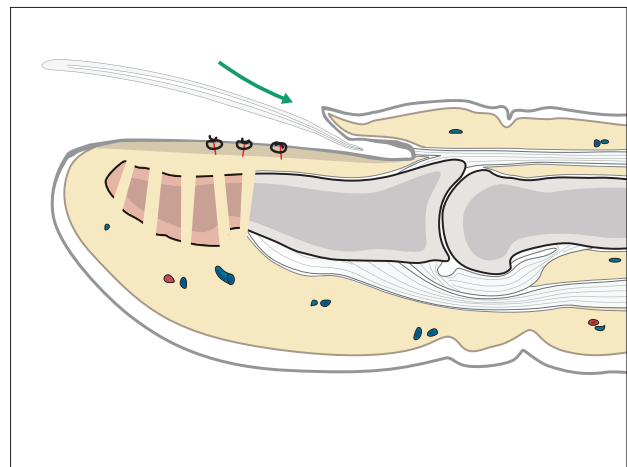
Pitfall: Eversion or inversion of nail bed edges
Be careful to suture the edges of the nail bed, avoiding eversion or inversion, otherwise, permanent deformity of nail growth can result.



5 Reinsertion of the nail

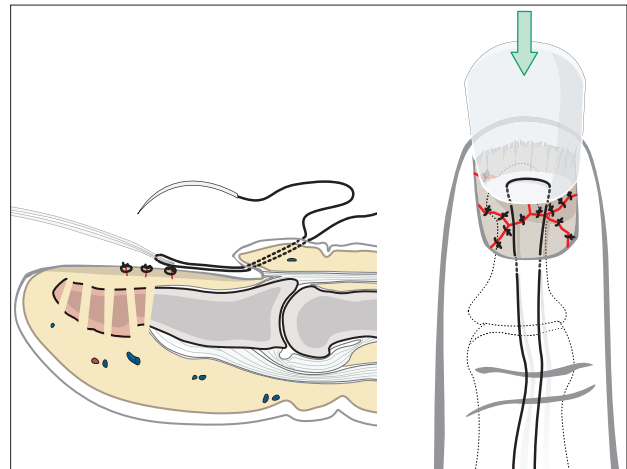
There are 4 main reasons for nail reinsertion:

1. to prevent scarring between the eponychium and the germinal matrix
2. to stabilize the fracture
3. the nail acts a biological barrier and protection
4. it acts as a template for the growth of a new nail.

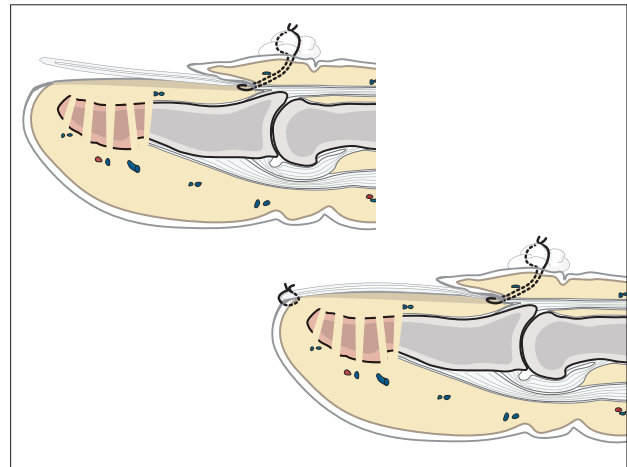




Insert a needle with a 5-0 nonresorbable nylon suture from the dorsal aspect into the sinus, exiting the sinus distally to the eponychium. Pass the needle through the proximal edge of the nail plate. Then pass the needle back through the nail plate and the sinus of the nail, so that it exits level with the first pass of the suture, separated from it by approximately 5 mm. Draw the nail plate back into the sinus by gentle traction on both ends of the suture. Tie the suture over a cotton, or foam, ball to avoid skin pressure injury.



After reinsertion and proximal fixation, the nail has a tendency to tilt upwards distally. To prevent this, use a small suture at the nail's distal tip to secure it to the nail bed.



6 Aftertreatment

Cleaning

Removal of the splint and skin care must be performed by the patient in 1-2 day intervals.

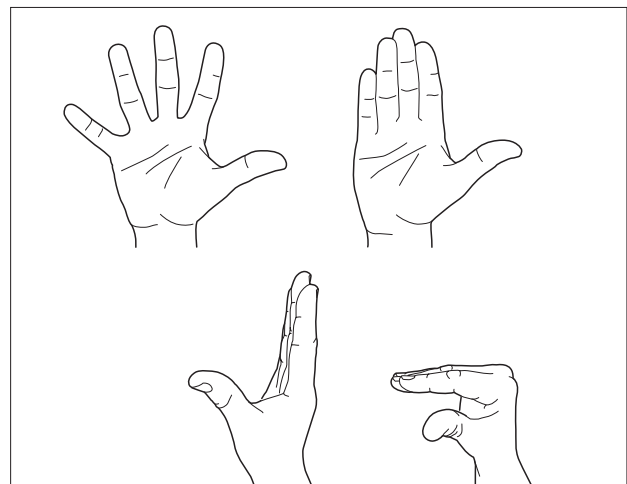
Functional exercises of the nonimmobilized joints can be started immediately.

Duration of immobilization

X-ray controls have to be performed immediately after the splint has been applied.

Follow-up x-rays with the splint should be taken after 1 week, and possibly after 2 weeks. Immobilization is continued until about 4 weeks after the injury. At that time an x-ray without the splint is taken to confirm healing. Splinting can then usually be discontinued and active mobilization is initiated.

If after 8 weeks radiographs confirm healing, full loading can be permitted.



Tuft fractures

In tuft fractures, splinting is mainly performed for pain treatment, and usually after 3 weeks, the splint can be discontinued. These injuries do not necessarily need x-ray control.



7 Fractures of the foot

7.11 I Fractures of the talus – Treatment with a cast

Indication **Undisplaced neck fracture of the talus**

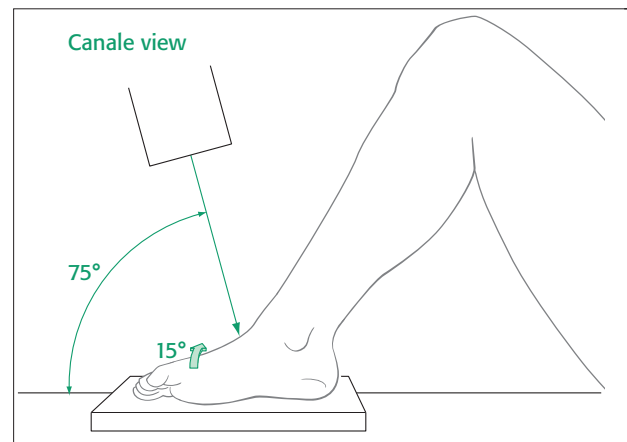
1 Decision making

Radiology

X-ray diagnosis is necessary using standard AP and lateral x-rays of the ankle and foot, with supplementary Canale views.

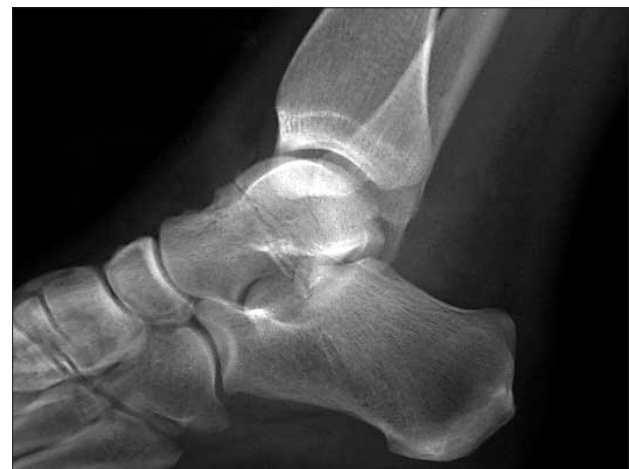These x-rays are often difficult to interpret as there is more displacement or associated subluxation, or dislocation, of the ankle or hindfoot.

CT scans are often necessary.



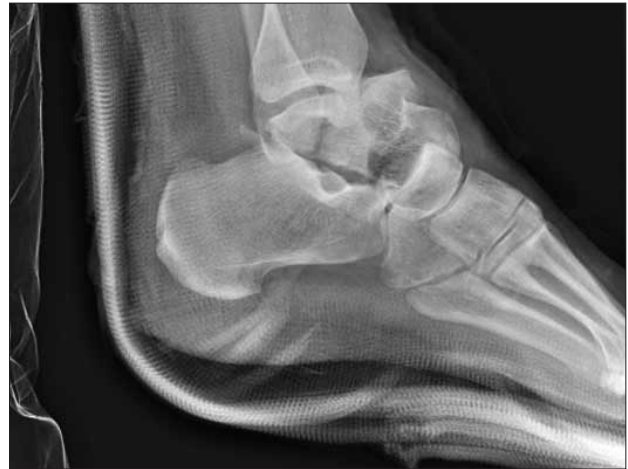Decision making

If the talar neck fracture is undisplaced and all joint surfaces are in perfect alignment, then nonoperative treatment is a rational choice.



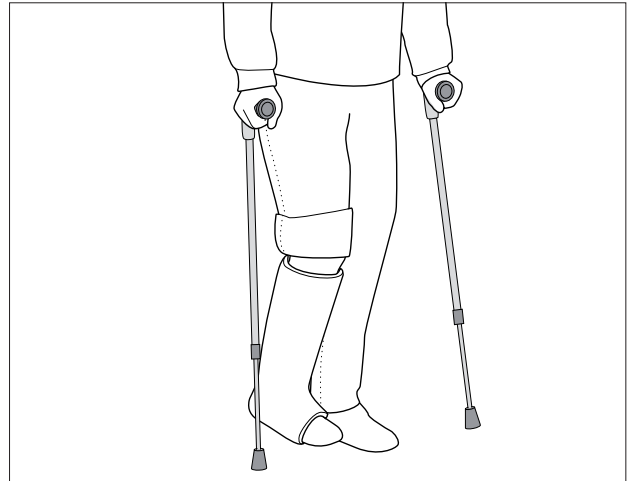


However, if this fracture is part of the spectrum of talar neck injuries which presents with displacement, requiring reduction, then there may be more decisions to be made about investigation and forms of treatment. Plain x-rays may be all that is required if the fracture is undisplaced. This, however, is unusual as most talar neck fractures present with at least some displacement. CT examination is very helpful whenever there is any question about displacement, or requirement for debridement of the subtalar joint. Along the spectrum of injury, increasing displacement presupposes that there is more subtalar and tibiotalar osteochondral injury. This often requires surgical approaches for debridement and fixation of these fracture types.



2 Casting

Undisplaced fractures are treated for 6-8 weeks in a non-weightbearing below-the-knee plaster cast. Avascular necrosis is unlikely with an incidence of 0-10%.



3 Aftertreatment

Non-weight bearing with a below-knee cast is continued for 6-8 weeks. Follow-up visits with radiography should occur at 2 and 6 weeks.

Once out of plaster, mobilization is started. Weight bearing is withheld until a full range of motion is achieved. In undisplaced fractures, full range of motion is usually achieved rapidly.

Gait training is initiated with physiotherapy, as required, at 6-8 weeks.





7 Fractures of the foot

7.12 I Fractures of the calcaneus – Treatment with a splint

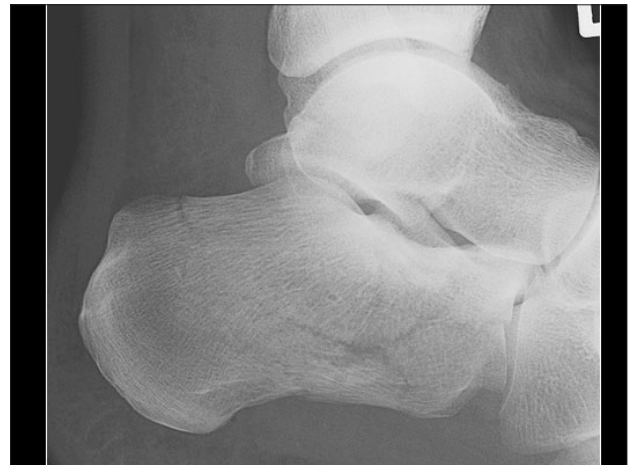Indication **Simple undisplaced fracture of the calcaneus**

1 Diagnosis

1.1 Decision making for nonoperative management
Patient considerations are extremely important when considering the diagnosis of calcaneal fractures. The surgeon must consider the patient and the fracture when making decisions about treatment.

Nonoperative management may be indicated in patients

- with minimal articular involvement
- with adequate maintenance of heel anatomy
- with medical contraindications to operative care.



1.2 Patient considerations

Patient considerations for nonoperative care include

- patients > 60 years old
- patients with medical diseases such as coronary artery disease or diabetes
- heavy smokers

It has been noted that patients who have secondary gain from impairment fail to achieve good outcomes after any form of treatment for calcaneal fractures.





1.3 Patient compliance

Few injuries are more devastating or have more long-term impact on a patient's life. Patient and family education is crucial for enabling the patient to understand the significance of this injury. Important factors such

as limb elevation, limb range of motion, smoking cessation and medical wellness (example: diabetic insulin control) allow patients to complete successfully required care pathways.

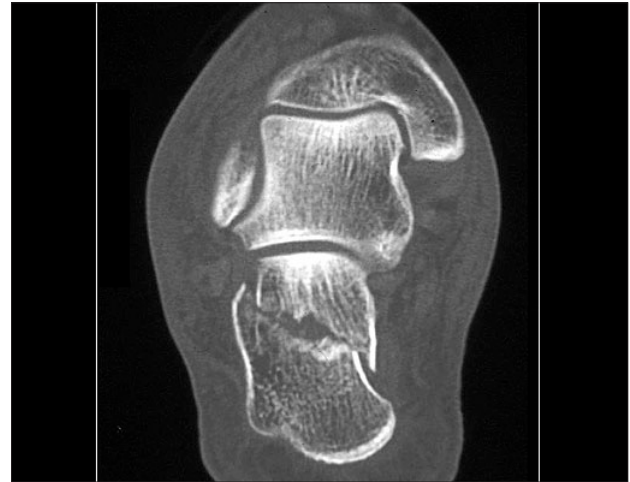1.4 Fracture considerations

Indications for nonoperative treatment are:

- Less than 2 mm displacement of articular surface
- No gross varus or valgus malalignment of the hind-foot

This image shows an extraarticular fracture with mild displacement in an older patient, appropriate for non-operative care.

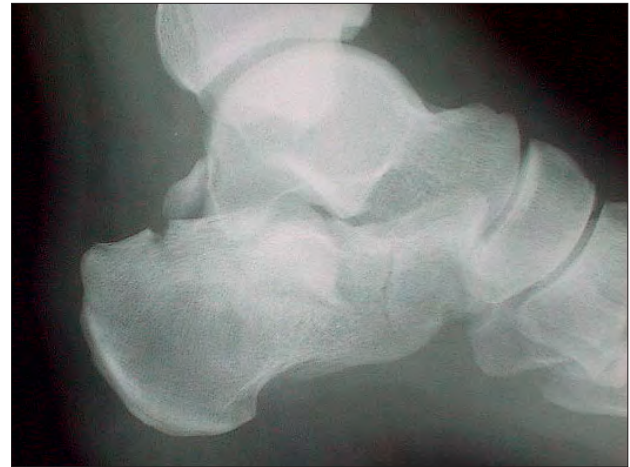Undisplaced fractures have generally a very good outcome.



1.5 Radiology

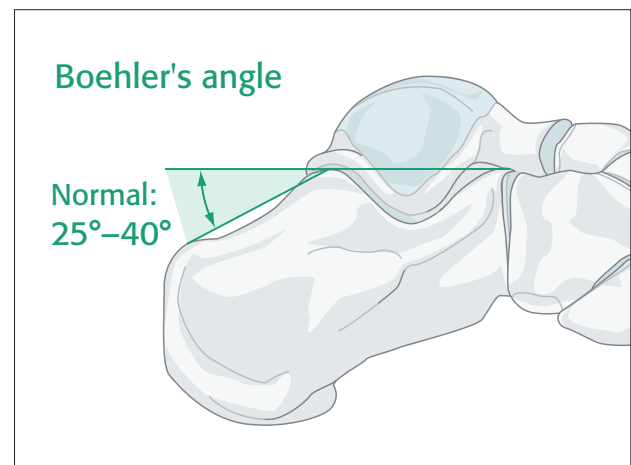
Radiographic views

The radiographic assessment begins with 3 views of the foot as well as an axial (Harris) view. The basic fracture types, i.e. tongue-type vs joint-depression type, are best demonstrated in the lateral view (as in this image).



Böhler's angle

A decrease in Böhler's angle demonstrates the severity of joint injury and displacement (depression) as measured on the lateral x-ray. The normal angle is 25 degrees to 40 degrees. If this angle remains above 15 degrees, nonoperative care can be suggested.

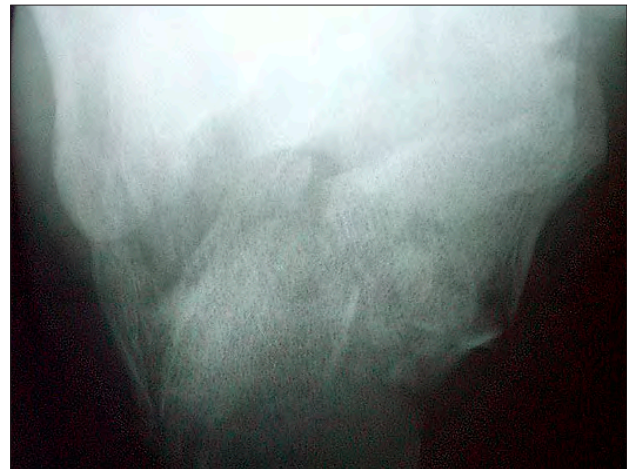



Axial view

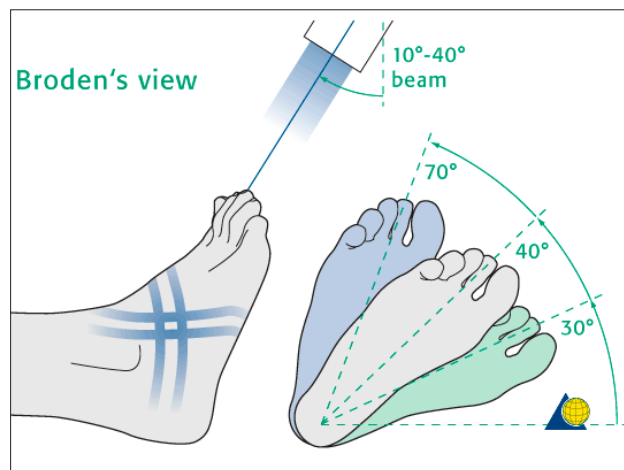
The axial view shows the primary joint displacement and angulation of the tuberosity as well as any increase in heel width.

This view is important intra-operatively to ensure that there is no varus in any calcaneal reconstructive procedure.



Broden's views

Broden's views are special calcaneal radiographic projections to show the congruence of the subtalar joint. They are taken at 30°, 50° and 70° to the horizontal.



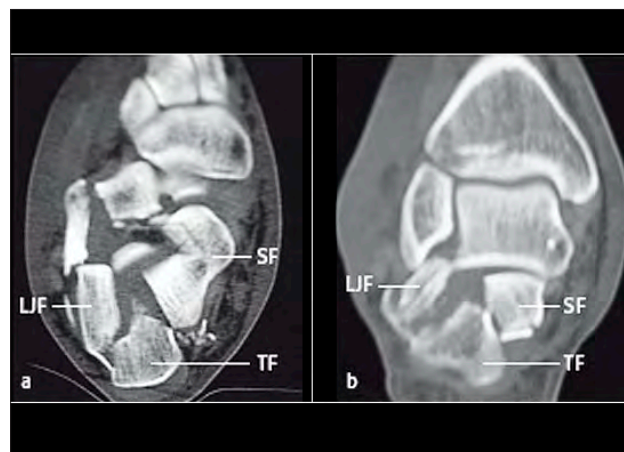
Computer-assisted tomography

Computer-assisted tomography is essential for accurate diagnosis and for surgical planning.

Axial CT images demonstrate fracture extension into the calcaneo-cuboid joint and tuberosity.

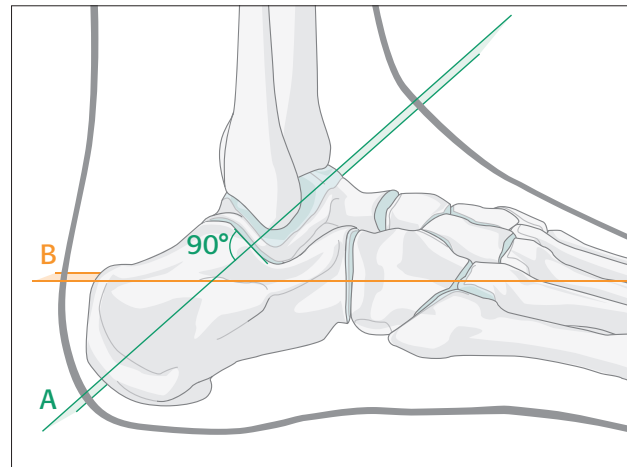
Coronal CT images depict the involvement of the posterior facet as well as shortening and position of the tuberosity.

Sagittal CT reconstructions can further elucidate the injury.





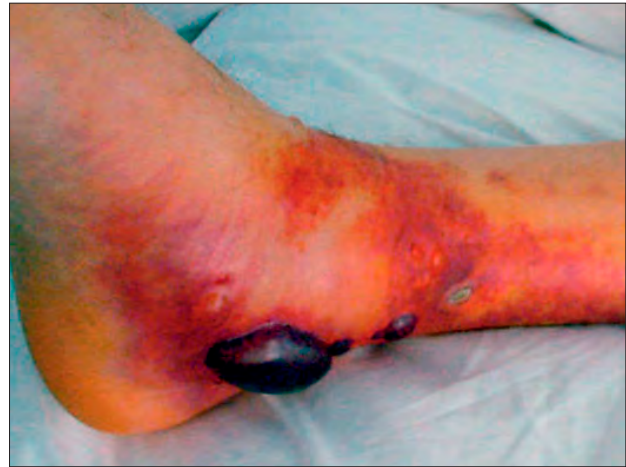For best CT imaging careful foot position is mandatory. As shown in the illustration the planes of reconstruction are A perpendicular to the post facet (semi-coronal) and B parallel to the sole of the foot (not metatarsal).



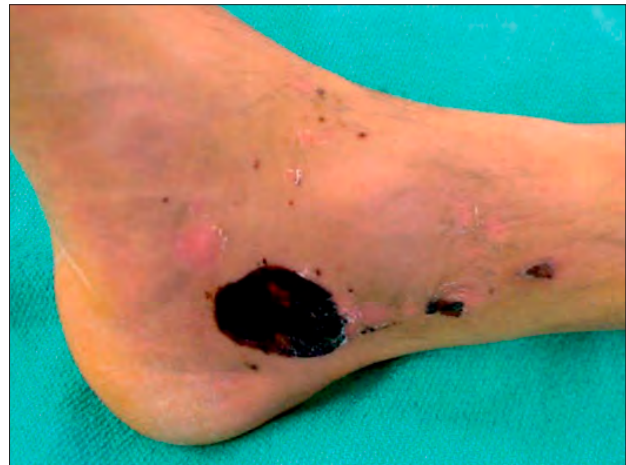2 Soft-tissue principles

2.1 Soft-tissue injury

All heel fractures have a spectrum of soft-tissue injury. Rest, ice, elevation and compression will help in resolving the soft-tissue injury, and prepare the foot for definitive care regardless of fracture type and treatment type. Non-weightbearing is essential until the final treatment plan has been executed. Compartment syndromes occur. Their incidence and indications for treatment are currently not clear. If missed, late reconstruction is successful.



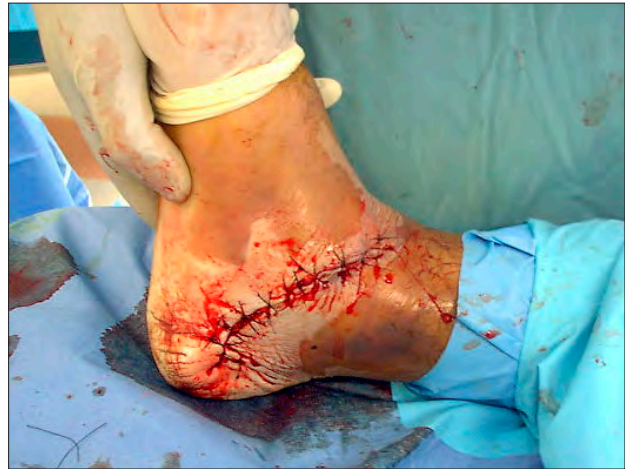The amount of swelling is a good indicator of the degree of soft-tissue injury. As the swelling recedes, the skin begins to wrinkle both on the lateral and medial side. The wrinkling of the skin is a good indicator when surgery can be undertaken. Usually, one has to delay between 8-14 days before surgery can be undertaken without dire consequences. The maximum one can delay is about 3 weeks. After 3 weeks, the fracture becomes increasingly more difficult because of fracture healing.





2.2 Open fractures

These injuries are surgical emergencies requiring urgent debridement and reduction of bony fragments. The soft-tissue injury for the open wound is usually on the medial side. Often, temporizing percutaneous wire fixation is used to hold reductions while the soft tissues are healing before definitive bony reconstruction. This image shows a severe medial soft-tissue wound which could be closed at 3 days.



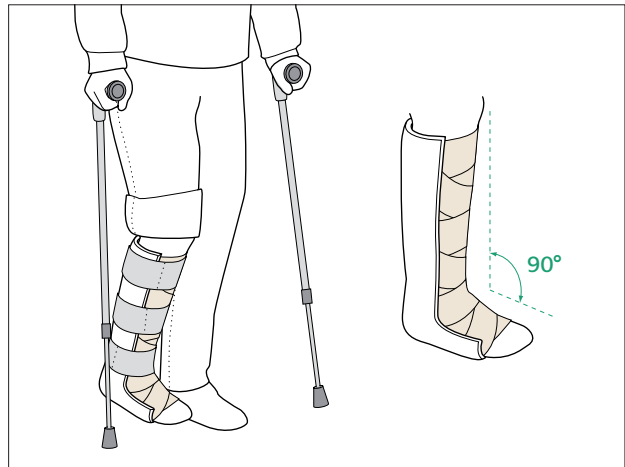
3 Nonoperative care

Nonoperative treatment consists of continued patient compliance with smoking cessation, elevation and limb range of motion.

A posterior splint that allows for ankle and subtalar joint range of motion is advised at 2-5 days.

Weight-bearing is not allowed except toe touch for 6 weeks. After that, fracture healing is assured and progression to full weight bearing is allowed.

Radiographic follow-up at 6 weeks and 12 weeks is advised.





7 Fractures of the foot

7.13 I Fractures of the navicular bone – Treatment with a functional boot

Indication **Navicular split/stress fracture**

1 Diagnosis

1.1 History

These fractures are often associated with jumping sports, like basketball. The patient presents with either immediate or delayed pain.

1.2 Physical exam

Often there is swelling and point tenderness. Usually there is no deformity present in split/stress fractures.

1.3 Imaging

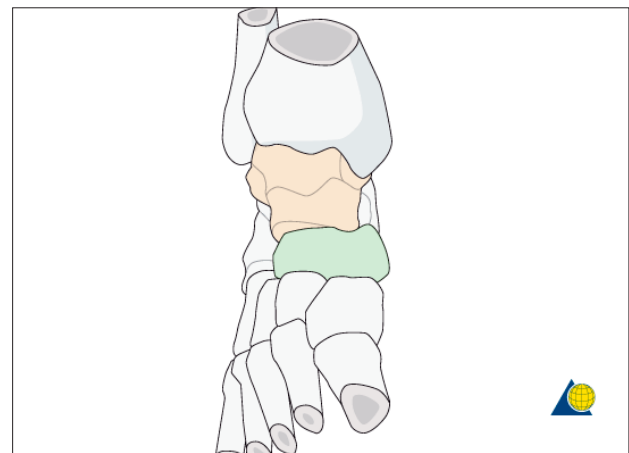
Plain x-rays often show a linear fracture line in the central portion of the navicular.

If a fracture is clinically suspected, but not evident on the x-ray, then proceed to other means of imaging. The TC99 bone scan may show an area of increased uptake and a CT and an MRI may give you a more definitive answer.

2 Principles

2.1 Talonavicular joint function

The talonavicular (TN) joint allows for hindfoot motion in all planes. Loss of TN motion results in loss of complex hindfoot circumduction. It is therefore extremely important to retain TN function as it has a protective function for the adjacent joints. Loss of TN motion leads to adjacent joint degeneration (DJD). Retaining even a small amount of motion is thought to be protective for the adjacent joint function. The TN joint, because of its extensive range of motion, is also known as the “coxa pedis”.

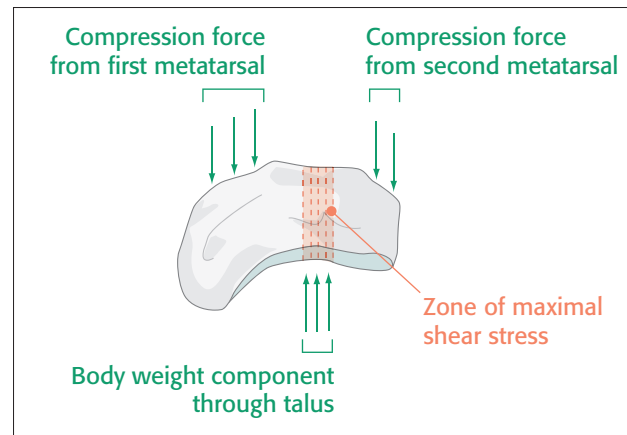




2.2 Stresses in athletics

There is a 3-point bending force on the navicular (see diagram). This can result in a frank fracture, or an occult (stress) fracture.

The principle which guides treatment is the removal of bending forces or stresses. Therefore we use external immobilization like a cast or a removable orthosis.

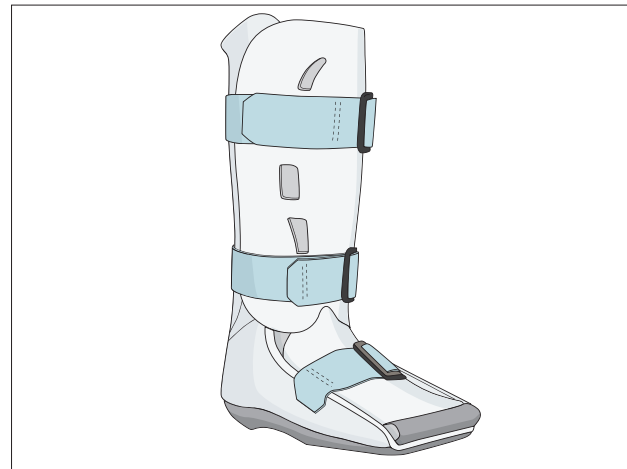

3 Nonoperative care

3.1 Immobilization

A functional boot can be used for support and immobilization. The advantage of a boot over casting is that the boot can be removed for personal hygiene.

In the acute phase while there is pain and swelling, weight bearing should be avoided. The boot can be removed for daily hindfoot circumduction. As healing progresses, protective weight bearing is allowed in the boot. The patient can then be progressed from the boot to cushioned running shoes.



4 Aftertreatment

4.1 Follow up

Return to sports is allowed when pain and swelling subside and there is evidence of healing on plane x-rays.





7 Fractures of the foot

7.13 II Fractures of the cuboid – Treatment with a functional boot

Indication **Simple cuboid fracture**

1 Diagnosis

1.1 History

These fractures are often associated with jumping sports, like basketball. The patient presents with either immediate or delayed pain.

1.2 Physical exam

On physical exam there will be pain and swelling. In the case of simple non-displaced fractures, or stress fractures, there is not likely to be foot deformity.

1.3 Imaging

Plain x-rays will often show a linear fracture line in the central portion of the cuboid.

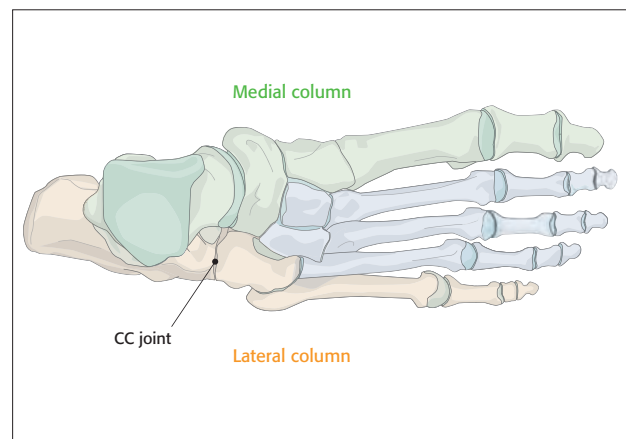
If the x-rays do not show a fracture, but it is clinically suspected, TC99 bone scan may show an area of increased uptake.

CT and MRI are also useful diagnostic tools.

2 Anatomic function

Unlike the TN joint, which is responsible for complex hindfoot circumduction, the calcaneocuboid (CC) joint is relatively unimportant for normal function. In fact, if fused at normal length, no loss of motion in the rest of the hindfoot occurs.

However, lateral column length is very important to maintain the shape and function of foot. Therefore, cuboid length must be maintained.



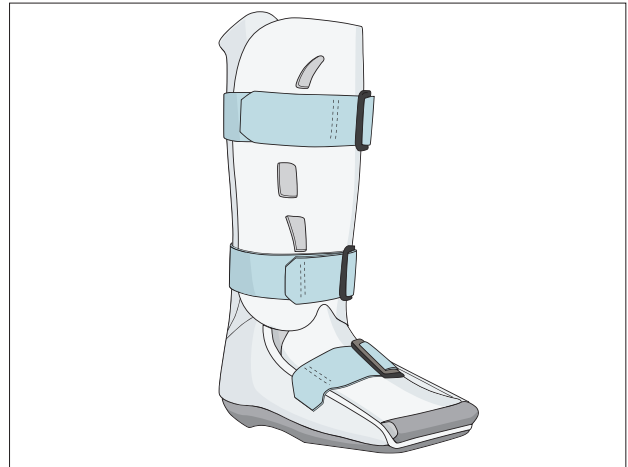

3 Nonoperative care

3.1 Immobilization

A functional boot can be used for support and immobilization. The advantage of a boot over casting is that the boot can be removed for personal hygiene.

In the acute phase while there is pain and swelling, weight bearing should be avoided. The boot can be removed for daily hindfoot circumduction. As healing progresses, protective weight bearing is allowed in the boot. The patient can then be transitioned from the boot to cushioned running shoes.



4 Aftertreatment

4.1 Follow up

Return to sports is allowed when pain and swelling subside and there is evidence of healing on plane x-rays.





7 Fractures of the foot

7.14 I Fractures of the phalanges — Treatment by buddy taping

Indication **Closed fractures of the 2nd - 5th row without serious displacement**

1 Indication for nonoperative treatment

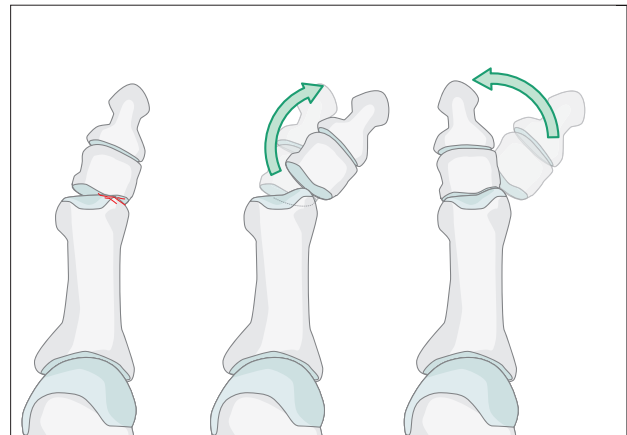
If it is a closed injury and there is no serious displacement, the toe is best treated by strapping it to the

adjacent uninjured toe (buddy taping).

Surgical stabilization is necessary when the fractures are open or grossly displaced.

2 Reduction

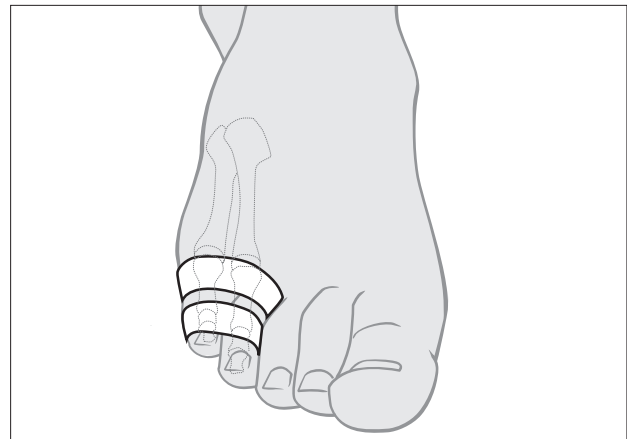
If a toe is dislocated, it is reduced by exaggerating the deformity and then applying traction and reversing the mechanism of injury.



3 Treatment

Alignment can be maintained by buddy taping. The skin is cleaned with alcohol to remove oils and 5-10 mm wide straps are fixed in a loop around the toes. Gauze may be placed between the toes to avoid maceration of the skin.

The MTP joint must be immobilized in an anatomical position to avoid a dorsiflexion contracture.





4 Aftercare

A stiff soled orthosis like a rocker-bottom sandal is used to protect the reduction and allow healing. The symptoms usually settle over the first few weeks. The tape should be changed frequently to prevent maceration between the toes. Most patients are capable of doing this themselves. Taping can be abandoned after 4-5 weeks.

